



# CMHD Pathology Report



## CMHD Pathology Core

Toronto Centre for  
Phenogenomics  
25 Orde St. 3rd fl.  
Toronto, Ont. M5T 3H7  
Tel.(416) 586-8375  
Fax (416) 586-5993

contact: Dr. Susan  
Newbigging  
email:  
[newbigging@lunenfeld.ca](mailto:newbigging@lunenfeld.ca)

## Principle Investigator: Dr. Jacqui White

Institute: Wellcome Trust Sanger Institute  
Address: Attn: Linda Read Wellcome Trust  
Genome Campus Hinxton Cambridge CB10  
1SA, UK

ReportID: Report Date: May 21, 2013  
Pathologist: Dr. H. Adissu

## Mouse Genetics Project

Wellcome Trust Sanger  
Institute  
Wellcome Trust Genome  
Campus  
Hinxton, Cambridge  
CB10 1SA  
UK

email:  
[MGPenquiries@sanger.ac.uk](mailto:MGPenquiries@sanger.ac.uk)  
[Mouse Portal](#)  
[Europhenome](#)

CMHD LabID: N13-242

## Relevant History:

preweaning lethality

preweaning lethality

## AnimalID: M00355922 (Male)

### Histopathology Findings:

#### liver (MA:0000358)

##### Histopath Description:

severe lipidosis

##### Morphological Diagnosis:

**Distribution:** diffuse; **Severity:** severe; **MPATH Diagnosis:** steatosis MPATH:622

##### Definitive Diagnosis:

Hepatic lipidosis

#### lymph node (MA:0000139)

##### Histopath Description:

The mesenteric lymph node is enlarged (greater than three-fold). There are multiple follicles with large germinal centers. The sinuses contain large numbers of mature lymphocytes.

##### Morphological Diagnosis:

**Duration:** Sub-acute; **Distribution:** Diffuse; **Severity:** moderate; **MPATH Diagnosis:** hyperplasia MPATH:134

##### Definitive Diagnosis:

Lymphoid hyperplasia.

##### Histopathology Comments:

The changes in the mesenteric lymph node are suggestive of draining of a regional inflammatory process. However, such a process was not observed in the tissues examined.

#### sternal manubrium (MA:0001332)

##### Histopath Description:

There is focally extensive degeneration and regeneration within sternal muscle

##### Morphological Diagnosis:

**Distribution:** focally extensive; **Severity:** mild;

##### Definitive Diagnosis:

Degeneration and regeneration of sternal muscle

##### Histopathology Comments:

The lesion is likely secondary to trauma or degenerative lesion of the sternal joints (occasionally seen in mice).

#### pancreas (MA:0000120)

**Histopath Description:**

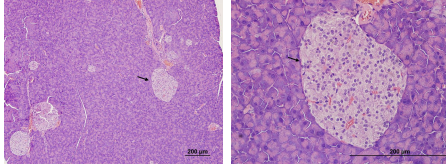
Nearly half of the pancreatic islets in the examined sections are enlarged (compare to WT).

**Morphological Diagnosis:**

**Distribution:** multifocal; **Severity:** mild;

**Definitive Diagnosis:**

Islet cell hyperplasia



Pancreatic islet,  
islet hyperplasia,  
10x, HE

Pancreatic islet,  
islet hyperplasia,  
40x, HE

**AnimalID: M00355923 (Male)****Histopathology Findings:****liver (MA:0000358)****Histopath Description:**

severe lipidosis

**Morphological Diagnosis:**

**Distribution:** diffuse; **Severity:** severe; **MPATH Diagnosis:** steatosis MPATH:622

**Definitive Diagnosis:**

Hepatic lipidosis

**pancreas (MA:0000120)****Histopath Description:**

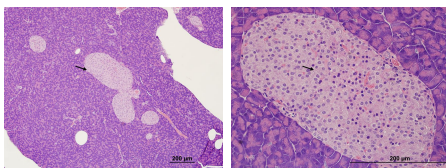
Nearly half of the pancreatic islets in the examined sections are enlarged (compare to WT).

**Morphological Diagnosis:**

**Distribution:** multifocal; **Severity:** mild;

**Definitive Diagnosis:**

Islet cell hyperplasia



Pancreatic islet,  
islet hyperplasia,  
10x, HE

Pancreatic islet,  
islet hyperplasia,  
40x, HE

**AnimalID: M00355930 (Female)****Histopathology Findings:****liver (MA:0000358)****Histopath Description:**

severe lipidosis

**Morphological Diagnosis:**

**Distribution:** diffuse; **Severity:** severe; **MPATH Diagnosis:** steatosis MPATH:622

**Definitive Diagnosis:**

Hepatic lipidosis

**pancreas (MA:0000120)****Histopath Description:**

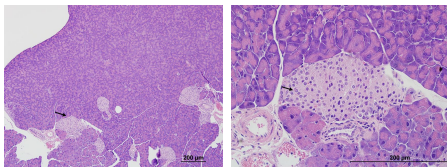
Nearly half of the pancreatic islets in the examined sections are enlarged (compare to WT).

**Morphological Diagnosis:**

**Distribution:** multifocal; **Severity:** mild;

**Definitive Diagnosis:**

Islet cell hyperplasia



Pancreatic islet,  
islet hyperplasia,  
10x, HE

Pancreatic islet,  
islet hyperplasia,  
40x, HE

**AnimalID: M00355931 (Female)**

**Histopathology Findings:**

**liver (MA:0000358)**

**Histopath Description:**

severe lipidosis

**Morphological Diagnosis:**

**Distribution:** diffuse; **Severity:** severe; **MPATH Diagnosis:** steatosis MPATH:622

**Definitive Diagnosis:**

Hepatic lipidosis

**retina (MA:0000276)**

**Histopath Description:**

Involving one eye, there are clusters of external nuclear structures within the internal plexiform layer.

**Morphological Diagnosis:**

**Distribution:** Focal; **Severity:** mild;

**Definitive Diagnosis:**

Retinal dysplasia

**brain (MA:0000168)**

**Histopath Description:**

There is mild dilation of the lateral ventricles

**Morphological Diagnosis:**

**Distribution:** bilateral; **Severity:** mild;

**Definitive Diagnosis:**

Dilation of the brain ventricles

**Histopathology Comments:**

Mild dilation of the lateral ventricles is a background condition in mice of C57BL/6N background (Brayton et al., 2004).

**pancreas (MA:0000120)**

**Histopath Description:**

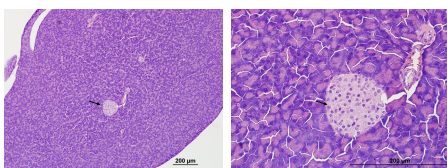
Normal

**Morphological Diagnosis:**

**Severity:** no lesions;

**Histopathology Comments:**

Normal



Pancreatic islet,  
normal, 10x, HE

Pancreatic islet,  
normal, 40x, HE

**Report Summary and Recommendation:**

Mild pancreatic islet hyperplasia was noted in three mice. We did not find lesions to explain early preweaning lethality. Analysis of mice at preweaning age may explain cause of death at this age. Other lesions are attributable to diet or strain background.