



CMHD Pathology Report



CMHD Pathology Core

Toronto Centre for
Phenogenomics
25 Orde St. 3rd fl.
Toronto, Ont. M5T 3H7
Tel.(416) 586-8375
Fax (416) 586-5993

contact: Dr. Susan
Newbigging
email:
newbigging@lunenfeld.ca

Principle Investigator: Dr. Jacqui White

Institute: Wellcome Trust Sanger Institute
Address: Attn: Linda Read Wellcome Trust
Genome Campus Hinxton Cambridge CB10
1SA, UK

ReportID: Report Date: October 23, 2013
Pathologist: Dr. H. Adissu

Mouse Genetics Project

Wellcome Trust Sanger
Institute
Wellcome Trust Genome
Campus
Hinxton, Cambridge
CB10 1SA
UK

email:
MGPenquiries@sanger.ac.uk
[Mouse Portal](#)
[Europhenome](#)

CMHD LabID: N13-704

Relevant History:

Phenotype:

enlarged hippocampus
thick hippocampus stratum oriens

AnimalID: M00572858 (Male)

Histopathology Findings:

brain (MA:0000168)

Histopath Description:

There is mild dilation of the the cerebral aqueduct

Morphological Diagnosis:

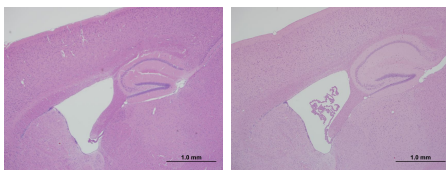
Distribution: bilateral; **Severity:** mild; **MPATH Process Term:** degenerative change MPATH:14

Definitive Diagnosis:

Dilation of the brain ventricles

Histopathology Comments:

Mild dilation ventricles is a background condition in mice of C57BL/6N background (Brayton et al., 2004).



Hippocampus,
normal, note mild
dilation of lateral
ventricle, 4x, HE

Hippocampus, WT,
normal, note mild
dilation of lateral
ventricle, 4x, HE

lymph node (MA:0000139)

Histopath Description:

Overall, the mesenteric lymph node is distinctly basophilic. Its architecture is disrupted by diffuse sheets of monotypic round cells that distended the subcapsular, medullary and occasional transverse sinuses. The cells have scant or no visible cytoplasm, round nuclei with stippled chromatin and a central distinct nucleolus (interpreted as lymphocytes). Rare apoptotic bodies and mitotic figures are present within occasional germinal centers.

Morphological Diagnosis:

MPATH Diagnosis: lymphoid neoplasms MPATH:513; **MPATH Process Term:** neoplasia MPATH:218

Definitive Diagnosis:

Lymphoma

liver (MA:0000358)

Histopath Description:

diffuse lipidosis

Morphological Diagnosis:

Distribution: diffuse; **Severity:** extreme; **MPATH Diagnosis:** steatosis MPATH:622; **MPATH Process Term:** lipid deposition MPATH:42

Definitive Diagnosis:

hepatic steatosis

salivary gland (MA:0000346)

Histopath Description:

There are multifocal perivascular mononuclear inflammatory cell aggregates.

Morphological Diagnosis:

Distribution: multifocal; **Severity:** mild; **MPATH Process Term:** inflammation MPATH:212

Definitive Diagnosis:

Interstitial inflammatory aggregates

Organ/Tissue Analyzed:

Histopathology examination included the following organs and tissues: calvarium, brain, eyes, ears, tongue, Harderian gland, zymbal gland, salivary glands, nasal sinuses, teeth, trachea, lungs, heart, thymus, parathyroid gland, spleen, liver, gall bladder, exocrine pancreas, endocrine pancreas, oesophagus, stomach, large intestine, small intestine, urinary organs and tract, testis, epididymis, vas deference, seminal vesicle, prostate, penis, adrenal gland, lymph nodes, spinal cord, bone marrow, skeletal muscles, brown fat, and skin.

AnimalID: M00572859 (Male)

Histopathology Findings:

brain (MA:0000168)

Histopath Description:

There is mild dilation of the the cerebral aqueduct

Morphological Diagnosis:

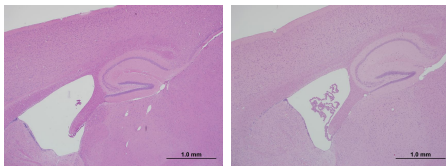
Distribution: bilateral; **Severity:** mild; **MPATH Process Term:** degenerative change MPATH:14

Definitive Diagnosis:

Dilation of the brain ventricles

Histopathology Comments:

Mild dilation ventricles is a background condition in mice of C57BL/6N background (Brayton et al., 2004).



Hippocampus,
normal, note mild
dilation of lateral
ventricle, 4x, HE

Hippocampus, WT,
normal, note mild
dilation of lateral
ventricle, 4x, HE

liver (MA:0000358)

Histopath Description:

diffuse lipidosis

Morphological Diagnosis:

Distribution: diffuse; **Severity:** extreme; **MPATH Diagnosis:** steatosis MPATH:622; **MPATH Process Term:** lipid deposition MPATH:42

Definitive Diagnosis:

hepatic steatosis

salivary gland (MA:0000346)

Histopath Description:

There are multifocal perivascular mononuclear inflammatory cell aggregates.

Morphological Diagnosis:

Distribution: multifocal; **Severity:** mild; **MPATH Process Term:** inflammation MPATH:212

Definitive Diagnosis:

Interstitial inflammatory aggregates

Organ/Tissue Analyzed:

Histopathology examination included the following organs and tissues: calvarium, brain, eyes, ears, tongue, Harderian gland, zymbal gland, salivary glands, nasal sinuses, teeth, trachea, lungs, heart, thymus, parathyroid gland, spleen, liver, gall bladder, exocrine pancreas, endocrine pancreas, oesophagus, stomach, large intestine, small intestine, urinary organs and tract, testis, epididymis, vas deference, seminal vesicle, prostate, penis, adrenal gland, lymph nodes, spinal cord, bone marrow, skeletal muscles, brown fat, and skin.

AnimalID: M00537479 (Female)**Histopathology Findings:****brain (MA:0000168)****Histopath Description:**

There is mild dilation of the the cerebral aqueduct

Morphological Diagnosis:

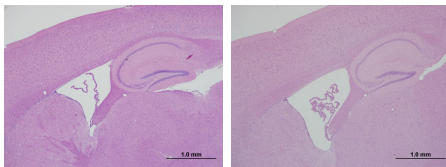
Distribution: bilateral; **Severity:** mild; **MPATH Process Term:** degenerative change MPATH:14

Definitive Diagnosis:

Dilation of the brain ventricles

Histopathology Comments:

Mild dilation ventricles is a background condition in mice of C57BL/6N background (Brayton et al., 2004).



Hippocampus,
normal, note mild
dilation of lateral
ventricle, 4x, HE

Hippocampus, WT,
normal, note mild
dilation of lateral
ventricle, 4x, HE

brain (MA:0000168)**Histopath Description:**

There are 50 um and 200 um diameter dermoid cysts within the cranial caudoputamen. The larger cyst is keratin-filled and is lined by a well-differentiated simple squamous epithelium.

Morphological Diagnosis:

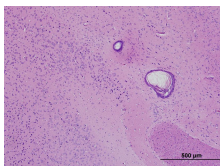
Distribution: multifocal; **Severity:** mild; **MPATH Diagnosis:** dermoid cyst MPATH:311; **MPATH Process Term:** developmental and structural abnormality MPATH:55

Definitive Diagnosis:

Dermoid cyst (dermoid sinus)

Histopathology Comments:

Dermoid cyst is caused by defective epidermal closure along embryonic fissures isolating an island of ectoderm in the dermis or subcutis. The cyst was small with minimal compression of the surrounding brain tissue; its significance is uncertain.



Caudoputamen,
dermoid cysts, 10x,
HE

salivary gland (MA:0000346)**Histopath Description:**

There are multifocal perivascular mononuclear inflammatory cell aggregates.

Morphological Diagnosis:

Distribution: multifocal; **Severity:** mild; **MPATH Process Term:** inflammation MPATH:212

Definitive Diagnosis:

Interstitial inflammatory aggregates

liver (MA:0000358)**Histopath Description:**

moderate lipidosis

Morphological Diagnosis:

Distribution: multifocal to coalescing; **Severity:** moderate; **MPATH Diagnosis:** steatosis MPATH:622; **MPATH Process Term:** lipid deposition MPATH:42

Definitive Diagnosis:

hepatic steatosis

retina (MA:0000276)**Histopath Description:**

There are multifocal retinal folds involving the outer nuclear layer

Morphological Diagnosis:

Distribution: multifocal; **Severity:** mild;

Definitive Diagnosis:

Retinal folding (dysplasia)

Organ/Tissue Analyzed:

Histopathology examination included the following organs and tissues: calvarium, brain, eyes, ears, tongue, Harderian gland, zymbal gland, salivary glands, nasal sinuses, teeth, trachea, lungs, heart, thymus, parathyroid gland, spleen, liver, gall bladder, exocrine pancreas, endocrine pancreas, oesophagus, stomach, large intestine, small intestine, urinary organs and tract, ovary, uterus, oviduct, vagina, adrenal gland, lymph nodes, spinal cord, bone marrow, skeletal muscles, brown fat, and skin.

AnimalID: M00537478 (Female)**Histopathology Findings:****brain (MA:0000168)****Histopath Description:**

There is mild dilation of the the cerebral aqueduct

Morphological Diagnosis:

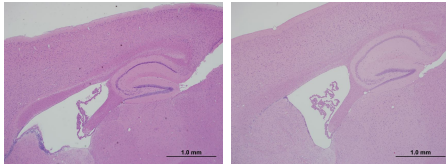
Distribution: bilateral; **Severity:** mild; **MPATH Process Term:** degenerative change MPATH:14

Definitive Diagnosis:

Dilation of the brain ventricles

Histopathology Comments:

Mild dilation ventricles is a background condition in mice of C57BL/6N background (Brayton et al., 2004).



Hippocampus,
normal, note mild
dilation of lateral
ventricle, 4x, HE

Hippocampus, WT,
normal, note mild
dilation of lateral
ventricle, 4x, HE

liver (MA:0000358)**Histopath Description:**

diffuse lipodosis

Morphological Diagnosis:

Distribution: diffuse; **Severity:** extreme; **MPATH Diagnosis:** steatosis MPATH:622; **MPATH Process Term:** lipid deposition MPATH:42

Definitive Diagnosis:

hepatic steatosis

spleen (MA:0000141)**Histopath Description:**

mild erythropoiesis

Morphological Diagnosis:

Distribution: multifocal to coalescing; **Severity:** moderate; **MPATH Diagnosis:** extramedullary hemopoiesis MPATH:595; **MPATH Process Term:** hyperplasia MPATH:134

Definitive Diagnosis:
mild erythropoiesis

Organ/Tissue Analyzed:

Histopathology examination included the following organs and tissues: calvarium, brain, eyes, ears, tongue, Harderian gland, zymbal gland, salivary glands, nasal sinuses, teeth, trachea, lungs, heart, thymus, parathyroid gland, spleen, liver, gall bladder, exocrine pancreas, endocrine pancreas, oesophagus, stomach, large intestine, small intestine, urinary organs and tract, ovary, uterus, oviduct, vagina, adrenal gland, lymph nodes, spinal cord, bone marrow, skeletal muscles, brown fat, and skin.

Report Summary and Recommendation:

Lesions in this line are incidental or attributable to diet or strain background. No morphological abnormalities were detected to corroborate the phenotype annotation.