



CMHD Pathology Report



CMHD Pathology Core

Toronto Centre for
Phenogenomics
25 Orde St. 3rd fl.
Toronto, Ont. M5T 3H7
Tel.(416) 586-8375
Fax (416) 586-5993

contact: Dr. Susan
Newbigging
email:
newbigging@lunenfeld.ca

Principle Investigator: Dr. Jacqui White

Institute: Wellcome Trust Sanger Institute
Address: Attn: Linda Read Wellcome Trust
Genome Campus Hinxton Cambridge CB10
1SA, UK

ReportID: Report Date: August 20, 2013
Pathologist: Dr. H. Adissu

Mouse Genetics Project

Wellcome Trust Sanger
Institute
Wellcome Trust Genome
Campus
Hinxton, Cambridge
CB10 1SA
UK

email:
MGPenquiries@sanger.ac.uk
[Mouse Portal](#)
[Europhenome](#)

CMHD LabID: N13-490

Relevant History:

Clinical phenotype

abnormal retinal pigmentation
abnormal retina morphology

AnimalID: M00688191 (Male)

Histopathology Findings:

liver (MA:0000358)

Histopath Description:

diffuse lipidosis

Morphological Diagnosis:

Distribution: diffuse; **Severity:** severe; **MPATH Diagnosis:** steatosis MPATH:622

Definitive Diagnosis:

Hepatic lipidosis

thymus (MA:0000142)

Histopath Description:

There is a 50 um diameter epithelial cyst.

Morphological Diagnosis:

Distribution: focal; **MPATH Diagnosis:** cyst MPATH:62

Definitive Diagnosis:

Epithelial cyst

Histopathology Comments:

This is a developmental abnormality commonly seen in mice.

lymph node (MA:0000139)

Histopath Description:

Early lymphoma

Morphological Diagnosis:

Distribution: Diffuse; **MPATH Diagnosis:** hyperplasia MPATH:134

Definitive Diagnosis:

Early lymphoma

eye (MA:0000261)

Histopath Description:

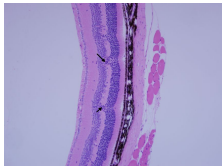
Involving one eye, there are clusters of external nuclear structures within the internal plexiform layer.

Morphological Diagnosis:

Distribution: multifocal; **Severity:** mild;

Definitive Diagnosis:

Retinal dysplasia



Eye, retina,
dysplasia, 20x, HE

Organ/Tissue Analyzed:

Histopathology examination included the following organs and tissues: brain, trigeminal ganglion, eyes, salivary glands, trachea, lungs, heart, thymus, thyroid gland, parathyroid gland, exocrine and endocrine pancreas, oesophagus, stomach, small intestine, large intestine, liver, gall bladder, spleen, kidneys, adrenal gland, lymph nodes, spinal cord, bone marrow, sternum, femur and tibia with associated skeletal muscles, brown fat, pinna, skin, testis, epididymis, seminal vesicle, and prostate.

AnimalID: M00688190 (Male)**Histopathology Findings:****liver (MA:0000358)****Histopath Description:**

diffuse lipidosis

Morphological Diagnosis:**Distribution:** diffuse; **Severity:** severe; **MPATH Diagnosis:** steatosis MPATH:622**Definitive Diagnosis:**

Hepatic lipidosis

thymus (MA:0000142)**Histopath Description:**

There is a 50 um diameter epithelial cyst.

Morphological Diagnosis:**Distribution:** focal; **MPATH Diagnosis:** cyst MPATH:62**Definitive Diagnosis:**

Epithelial cyst

Histopathology Comments:

This is a developmental abnormality commonly seen in mice.

lymph node (MA:0000139)**Histopath Description:**

The mesenteric lymph node is markedly enlarged (greater than four fold). The medulla is particularly expanded by chords and sheets of plasmotoid cells. There are prominent germinal centers within the medulla

Morphological Diagnosis:**Distribution:** Diffuse; **Severity:** moderate; **MPATH Diagnosis:** hyperplasia MPATH:134**Definitive Diagnosis:**

Lymphoid hyperplasia

Histopathology Comments:

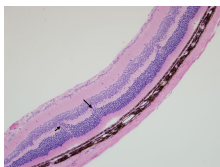
The changes in the mesenteric lymph node are suggestive of draining of a regional inflammatory process. However, such a process was not observed in the tissues examined. Early maginal center lymphoma is suspected.

eye (MA:0000261)**Histopath Description:**

Involving one eye, there are clusters of external nuclear structures within the internal plexiform layer.

Morphological Diagnosis:**Distribution:** multifocal; **Severity:** mild;**Definitive Diagnosis:**

Retinal dysplasia



Eye, retina,
dysplasia, 20x, HE

Organ/Tissue Analyzed:

Histopathology examination included the following organs and tissues: brain, trigeminal ganglion, eyes, salivary glands, trachea, lungs, heart, thymus, thyroid gland, parathyroid gland, exocrine and endocrine pancreas, oesophagus, stomach, small intestine, large intestine, liver, gall bladder, spleen, kidneys, adrenal gland, lymph nodes, spinal cord, bone marrow, sternum, femur and tibia with associated skeletal muscles, brown fat, pinna, skin, testis, epididymis, seminal vesicle, and prostate.

AnimalID: M00713871 (Female)

Histopathology Findings:

liver (MA:0000358)

Histopath Description:

diffuse lipidosis

Morphological Diagnosis:

Distribution: diffuse; **Severity:** severe; **MPATH Diagnosis:** steatosis MPATH:622

Definitive Diagnosis:

Hepatic lipidosis

thymus (MA:0000142)

Histopath Description:

There is a 50 um diameter epithelial cyst.

Morphological Diagnosis:

Distribution: focal; **MPATH Diagnosis:** cyst MPATH:62

Definitive Diagnosis:

Epithelial cyst

Histopathology Comments:

This is a developmental abnormality commonly seen in mice.

lymph node (MA:0000139)

Histopath Description:

The mesenteric lymph node is markedly enlarged (greater than four fold). The medulla is particularly expanded by chords and sheets of plasmotoid cells. There are prominent germinal centers within the medulla

Morphological Diagnosis:

Distribution: Diffuse; **Severity:** moderate; **MPATH Diagnosis:** hyperplasia MPATH:134

Definitive Diagnosis:

Lymphoid hyperplasia

Histopathology Comments:

The changes in the mesenteric lymph node are suggestive of draining of a regional inflammatory process. However, such a process was not observed in the tissues examined. Early maginal center lymphoma is suspected.

eye (MA:0000261)

Histopath Description:

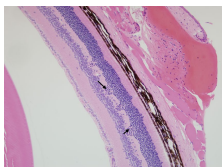
Involving one eye, there are clusters of external nuclear structures within the internal plexiform layer.

Morphological Diagnosis:

Distribution: multifocal; **Severity:** mild;

Definitive Diagnosis:

Retinal dysplasia



Eye, retina,
dysplasia, 20x, HE

Organ/Tissue Analyzed:

Histopathology examination included the following organs and tissues: brain, trigeminal ganglion, eyes, salivary glands, trachea, lungs, heart, thymus, thyroid gland, parathyroid gland, exocrine and endocrine pancreas, oesophagus, stomach, small intestine, large intestine, liver, gall bladder, spleen, kidneys, adrenal gland, lymph nodes, spinal cord, bone marrow, sternum, femur and tibia with associated skeletal muscles, brown fat, pinna, skin, uterus, oviduct, and ovary, and mammary gland.

AnimalID: M00713863 (Female)

Histopathology Findings:

liver (MA:0000358)

Histopath Description:

diffuse lipidosis

Morphological Diagnosis:

Distribution: diffuse; **Severity:** severe; **MPATH Diagnosis:** steatosis MPATH:622

Definitive Diagnosis:

Hepatic lipidosis

lymph node (MA:0000139)

Histopath Description:

The mesenteric lymph node is markedly enlarged (greater than four fold). The medulla is particularly expanded by chords and sheets of plasmotoid cells. There are prominent germinal centers within the medulla

Morphological Diagnosis:

Distribution: Diffuse; **Severity:** moderate; **MPATH Diagnosis:** hyperplasia MPATH:134

Definitive Diagnosis:

Lymphoid hyperplasia

Histopathology Comments:

The changes in the mesenteric lymph node are suggestive of draining of a regional inflammatory process. However, such a process was not observed in the tissues examined. Early marginal center lymphoma is suspected.

eye (MA:0000261)

Histopath Description:

A 100-um long stretch of fibrous connective tissue extends from the area of the optic disc towards the posterior capsule of the lens.

Morphological Diagnosis:

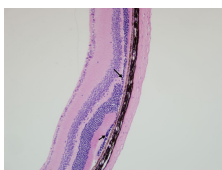
MPATH Diagnosis: developmental and structural abnormality MPATH:55

Definitive Diagnosis:

Persistent hyaloid artery

Histopathology Comments:

hyaloid artery remnant is a rare condition in which there remain some parts of the hyaloid artery. The posterior hyaloid vascular system of mice usually undergoes involution in the first month of life (Richard et al., 2000).



Eye, retina,
dysplasia, 20x, HE

eye (MA:0000261)

Histopath Description:

In one eye, there are clusters of external nuclear structures within the internal plexiform layer. In

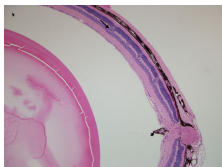
the other eye the inner nuclear layer is segmentally attenuated (hypoplastic); adjacent to this, there is an additional layer of inner nuclear layer embedded within the outer plexiform layer.

Morphological Diagnosis:

Distribution: multifocal; **Severity:** mild;

Definitive Diagnosis:

Retinal dysplasia



Eye, retina,
dysplasia (large
arrow); hyaloid
artery remnant
(small arrow), 20x,
HE

Organ/Tissue Analyzed:

Histopathology examination included the following organs and tissues: brain, trigeminal ganglion, eyes, salivary glands, trachea, lungs, heart, thymus, thyroid gland, parathyroid gland, exocrine and endocrine pancreas, oesophagus, stomach, small intestine, large intestine, liver, gall bladder, spleen, kidneys, adrenal gland, lymph nodes, spinal cord, bone marrow, sternum, femur and tibia with associated skeletal muscles, brown fat, pinna, skin, uterus, oviduct, and ovary, and mammary gland.

Report Summary and Recommendation:

Mild unilateral or bilateral retinal dysplasia is observed in all mice. The lesion may explain the abnormal retinal morphology documented. We did not see abnormality in retinal pigmentation. Lymphoid hyperplasia or early lymphoma was noted in all mice. Other lesions are attributable to diet or strain background.

Summary: Retinal dysplasia (4/4); Lymphoid hyperplasia/lymphoma (4/4).