



# CMHD Pathology Report



## CMHD Pathology Core

Toronto Centre for  
Phenogenomics  
25 Orde St. 3rd fl.  
Toronto, Ont. M5T 3H7  
Tel.(416) 586-8375  
Fax (416) 586-5993

contact: Dr. Susan  
Newbigging  
email:  
[newbigging@lunenfeld.ca](mailto:newbigging@lunenfeld.ca)

## Principle Investigator: Dr. Jacqui White

Institute: Wellcome Trust Sanger Institute  
Address: Attn: Linda Read Wellcome Trust  
Genome Campus Hinxton Cambridge CB10  
1SA, UK

ReportID: Report Date: October 17, 2013  
Pathologist: Dr. H. Adissu

## Mouse Genetics Project

Wellcome Trust Sanger  
Institute  
Wellcome Trust Genome  
Campus  
Hinxton, Cambridge  
CB10 1SA  
UK

email:  
[MGPenquiries@sanger.ac.uk](mailto:MGPenquiries@sanger.ac.uk)  
[Mouse Portal](#)  
[Europhenome](#)

CMHD LabID: N13-703

## Relevant History:

Phenotypes:

Salmonella Challenge  
Citrobacter Challenge

increased susceptibility to bacterial infection  
increased susceptibility to bacterial infection induced morbidity/mortality

## AnimalID: M00455413 (Male)

### Histopathology Findings:

#### lung (MA:0000415)

##### Histopath Description:

There are occasional perivascular lymphoid aggregates

##### Morphological Diagnosis:

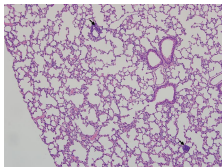
**Distribution:** multifocal; **Severity:** mild; **MPATH Process Term:** inflammation MPATH:212

##### Definitive Diagnosis:

Perivascular lymphoid aggregates

##### Histopathology Comments:

The lesion suggests antigenic stimulation of hematogenous origin



Lung, perivascular  
lymphoid  
aggregates, 10x,  
HE

#### adrenal gland (MA:0000116)

##### Histopath Description:

There is a small, well-circumscribed mass in the cortex. It is encapsulated by a thin layer of pale eosinophilic material and fusiform cells (connective tissue with fibroblasts) and is made of nests of polygonal cells interspersed by a very thin fibrovascular membrane. The architecture is reminiscent of the zona glomerulosa and zona fasciculata of the mature adrenal gland.

##### Morphological Diagnosis:

**Distribution:** focal; **MPATH Process Term:** developmental and structural abnormality  
MPATH:55

##### Definitive Diagnosis:

accessory adrenal cortical tissue

#### retina (MA:0000276)

**Histopath Description:**

There are multifocal retinal folds involving the outer nuclear layer

**Morphological Diagnosis:**

**Distribution:** multifocal; **Severity:** mild;

**Definitive Diagnosis:**

Retinal folding (dysplasia)

**liver (MA:0000358)****Histopath Description:**

diffuse lipidosis

**Morphological Diagnosis:**

**Distribution:** diffuse; **Severity:** extreme; **MPATH Diagnosis:** steatosis MPATH:622; **MPATH Process Term:** lipid deposition MPATH:42

**Definitive Diagnosis:**

hepatic steatosis

**Organ/Tissue Analyzed:**

Histopathology examination included the following organs and tissues: brain, trigeminal ganglion, eyes, salivary glands, trachea, lungs, heart, thymus, thyroid gland, parathyroid gland, exocrine and endocrine pancreas, oesophagus, stomach, small intestine, large intestine, liver, gall bladder, spleen, kidneys, adrenal gland, lymph nodes, spinal cord, bone marrow, sternum, femur and tibia with associated skeletal muscles, brown fat, pinna, skin, testis, epididymis, seminal vesicle, and prostate.

**AnimalID: M00455414 (Male)****Histopathology Findings:****liver (MA:0000358)****Histopath Description:**

diffuse lipidosis

**Morphological Diagnosis:**

**Distribution:** diffuse; **Severity:** extreme; **MPATH Diagnosis:** steatosis MPATH:622; **MPATH Process Term:** lipid deposition MPATH:42

**Definitive Diagnosis:**

hepatic steatosis

**lymph node (MA:0000139)****Histopath Description:**

The mesenteric lymph node is markedly enlarged (greater than four fold). The medulla is particularly expanded by chords and sheets of plasmotoid cells. There are prominent germinal centers within the medulla

**Morphological Diagnosis:**

**Distribution:** Diffuse; **Severity:** moderate; **MPATH Diagnosis:** hyperplasia MPATH:134; **MPATH Process Term:** hyperplasia MPATH:134

**Definitive Diagnosis:**

Lymphoid hyperplasia

**Histopathology Comments:**

The changes in the mesenteric lymph node are suggestive of draining of a regional inflammatory process. However, such a process was not observed in the tissues examined. Early maginal center lymphoma is suspected.

**Organ/Tissue Analyzed:**

Histopathology examination included the following organs and tissues: brain, trigeminal ganglion, eyes, salivary glands, trachea, lungs, heart, thymus, thyroid gland, parathyroid gland, exocrine and endocrine pancreas, oesophagus, stomach, small intestine, large intestine, liver, gall bladder, spleen, kidneys, adrenal gland, lymph nodes, spinal cord, bone marrow, sternum, femur and tibia with associated skeletal muscles, brown fat, pinna, skin, testis, epididymis, seminal vesicle, and prostate.

**AnimalID: M00558290 (Female)****Histopathology Findings:**

**lung (MA:0000415)****Histopath Description:**

There are numerous perivascular lymphoid aggregates

**Morphological Diagnosis:**

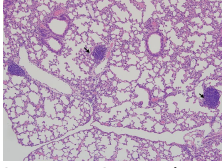
**Distribution:** multifocal; **Severity:** moderate; **MPATH Process Term:** inflammation MPATH:212

**Definitive Diagnosis:**

Perivascular lymphoid aggregates

**Histopathology Comments:**

The lesion suggests antigenic stimulation of hematogenous origin



Lung, perivascular  
lymphoid  
aggregates, 10x,  
HE

**adrenal gland (MA:0000116)****Histopath Description:**

There is a small, well-circumscribed mass in the cortex. It is encapsulated by a thin layer of pale eosinophilic material and fusiform cells (connective tissue with fibroblasts) and is made of nests of polygonal cells interspersed by a very thin fibrovascular membrane. The architecture is reminiscent of the zona glomerulosa and zona fasciculata of the mature adrenal gland.

**Morphological Diagnosis:**

**Distribution:** focal; **MPATH Process Term:** developmental and structural abnormality MPATH:55

**Definitive Diagnosis:**

accessory adrenal cortical tissue

**retina (MA:0000276)****Histopath Description:**

There are multifocal retinal folds involving the outer nuclear layer

**Morphological Diagnosis:**

**Distribution:** multifocal; **Severity:** mild;

**Definitive Diagnosis:**

Retinal folding (dysplasia)

**liver (MA:0000358)****Histopath Description:**

moderate lipidoses

**Morphological Diagnosis:**

**Distribution:** multifocal to coalescing; **Severity:** moderate; **MPATH Diagnosis:** steatosis MPATH:622; **MPATH Process Term:** lipid deposition MPATH:42

**Definitive Diagnosis:**

hepatic steatosis

**Organ/Tissue Analyzed:**

Histopathology examination included the following organs and tissues: brain, trigeminal ganglion, eyes, salivary glands, trachea, lungs, heart, thymus, thyroid gland, parathyroid gland, exocrine and endocrine pancreas, oesophagus, stomach, small intestine, large intestine, liver, gall bladder, spleen, kidneys, adrenal gland, lymph nodes, spinal cord, bone marrow, sternum, femur and tibia with associated skeletal muscles, brown fat, pinna, skin, uterus, oviduct, and ovary, and mammary gland.

**AnimalID: M00558298 (Female)****Histopathology Findings:****heart (MA:0000072)****Histopath Description:**

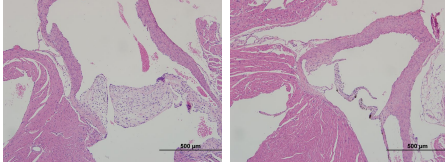
The aortic valve is enlarged and expanded by fibroplasia and small amount of myxomatous matrix.

**Morphological Diagnosis:****Distribution:** diffuse; **Severity:** moderate; **MPATH Process Term:** fibrosis MPATH:181**Definitive Diagnosis:**

Aortic sclerosis

**Histopathology Comments:**

Aortic sclerosis is an irregular valve thickening, mostly resulting from fibrosis, without obstruction to the ventricular outflow tract. Secondary changes in the left ventricular wall are not noticeable.



Aorta, sclerosis,  
10x, HE

Aorta, WT, normal,  
10x, HE

**liver (MA:0000358)****Histopath Description:**

moderate lipidosis

**Morphological Diagnosis:****Distribution:** multifocal to coalescing; **Severity:** moderate; **MPATH Diagnosis:** steatosis MPATH:622; **MPATH Process Term:** lipid deposition MPATH:42**Definitive Diagnosis:**

hepatic steatosis

**retina (MA:0000276)****Histopath Description:**

There are multifocal retinal folds involving the outer nuclear layer

**Morphological Diagnosis:****Distribution:** multifocal; **Severity:** mild;**Definitive Diagnosis:**

Retinal folding (dysplasia)

**Organ/Tissue Analyzed:**

Histopathology examination included the following organs and tissues: brain, trigeminal ganglion, eyes, salivary glands, trachea, lungs, heart, thymus, thyroid gland, parathyroid gland, exocrine and endocrine pancreas, oesophagus, stomach, small intestine, large intestine, liver, gall bladder, spleen, kidneys, adrenal gland, lymph nodes, spinal cord, bone marrow, sternum, femur and tibia with associated skeletal muscles, brown fat, pinna, skin, uterus, oviduct, and ovary, and mammary gland.

**Report Summary and Recommendation:**

Multifocal perivascular mononuclear inflammatory cell aggregates were noted in two mice. The lesion in one of the mice is more severe and numerous than normally seen as incidental lesion. The lesion suggests antigenic stimulation of hematogenous origin. Besides these lesions there are no changes suggestive of susceptibility to infection.

We have recently analyzed a Myd88 KO mouse from Norcomm project. Multiorgan abscess with intralesional bacteria was found in that line consistent with the role of the gene in innate immunity (Skerrett et al. 2004; Naiki et al., 2005). The absence of similar lesions in this line is intriguing and suggests potential partial functionality of the targeted gene in question.

**Line summary:**

Lung: perivascular mononuclear inflammatory aggregates (2/4)

**References:**

Naiki Y, et al. (2005). MyD88 is pivotal for the early inflammatory response and subsequent bacterial clearance and survival in a mouse model of Chlamydia pneumoniae pneumonia. J Biol Chem. 280:29242-9  
Skerrett SJ et al. (2004). Cutting edge: myeloid differentiation factor 88 is essential for pulmonary host defense against Pseudomonas aeruginosa but not Staphylococcus aureus. J Immunol. 172:3377-81