



# CMHD Pathology Report



## CMHD Pathology Core

Toronto Centre for  
Phenogenomics  
25 Orde St. 3rd fl.  
Toronto, Ont. M5T 3H7  
Tel.(416) 586-8375  
Fax (416) 586-5993

contact: Dr. Susan  
Newbigging  
email:  
[newbigging@lunenfeld.ca](mailto:newbigging@lunenfeld.ca)

## Principle Investigator: Dr. Colin McKerlie ICSIG

Institute: Sick Kids  
Address:

ReportID: Report Date: November 23,  
2011  
Pathologist: H. Adissu

## Mouse Genetics Project

Wellcome Trust Sanger  
Institute  
Wellcome Trust Genome  
Campus  
Hinxton, Cambridge  
CB10 1SA  
UK

email:  
[MGPenquiries@sanger.ac.uk](mailto:MGPenquiries@sanger.ac.uk)  
[Mouse Portal](#)  
[Europhenome](#)

CMHD LabID: N11-188

## Relevant History:

(Fertility; Body Weight Curves; Grip Strength; Body Composition (DEXA); X-ray Imaging; Peripheral Blood Lymphocytes) Decreased grip strength, decreased body weight/length, increased NK T cells, abnormal fertility, decreased BMD/BMC, abnormal spine curvature

## AnimalID: M00400341 Sms hem

### Tissue Preservation and Staining:

Thyroid gland is not present in the section. Mesenteric lymph node is not present in section. Tissues not present in submission: Calvarium, ears, tongue, Harderian gland, zymbal gland, nasal sinuses, teeth, gall bladder.

### Histopathology Findings:

#### fat (MA:0000056)

#### Morphological Diagnosis:

**Distribution:** Focal;

#### Definitive Diagnosis:

Focally extensive chronic and proliferative steatitis

#### Histopathology Comments:

Lesion will be reviewed further; results will be appended

#### testis (MA:0000411)

#### Histopath Description:

Nearly 80% of the seminiferous tubules are vacuolated and hypocellular with fewer spermatids and no or minimum numbers of spermatocytes. Apoptotic bodies and multinucleated cells are frequent.

#### Morphological Diagnosis:

**Distribution:** Multifocal; **Severity:** severe; **MPATH Diagnosis:** atrophy MPATH:127

#### Definitive Diagnosis:

Testicular degeneration and atrophy with apoptosis and multinucleated cells, vacuolation of sertoli cells.

#### epididymal duct (MA:0001735)

#### Histopath Description:

The epididymal duct in all segments contains no spermatocytes.

#### Morphological Diagnosis:

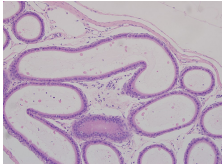
**Distribution:** Diffuse; **Severity:** extreme; **MPATH Diagnosis:** atrophy MPATH:127

#### Definitive Diagnosis:

Epididymal aspermia

#### Histopathology Comments:

The absence of spermatocytes within the epididymis is consistent with the changes in the seminiferous tubules.



Epididymal duct,  
hypospermia, 20x

#### bone marrow (MA:0000134)

##### Histopath Description:

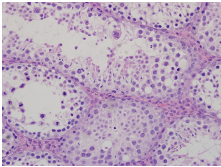
Myeloid hyperplasia

##### Morphological Diagnosis:

**Distribution:** Diffuse; **Severity:** moderate; **MPATH Diagnosis:** hyperplasia MPATH:134

##### Definitive Diagnosis:

Granulocytic hyperplasia



Testis, testicular  
degeneration, 40x

#### Summary:

hepatic lipidosis not present.

#### AnimalID: M00400348 Sms hem

##### Tissue Preservation and Staining:

Tissues not present in submission: Calvarium, ears, tongue, Harderian gland, zymbal gland, nasal sinuses, teeth, gall bladder.

##### Histopathology Findings:

#### heart (MA:0000072)

##### Histopath Description:

Focal lymphoplasmacytic perivascular inflammatory aggregate adjacent to the thoracic outlet.

##### Morphological Diagnosis:

**Distribution:** Focal; **Severity:** mild; **MPATH Diagnosis:** inflammation MPATH:212

##### Definitive Diagnosis:

Perivascular mononuclear inflammatory aggregate

#### fat (MA:0000056)

##### Histopath Description:

Focal histiocytic steatitis

##### Morphological Diagnosis:

**Duration:** Chronic; **Distribution:** Focal; **Severity:** mild; **MPATH Diagnosis:** inflammation MPATH:212

##### Definitive Diagnosis:

Histiocytic and lymphocytic steatitis/paniculitis

#### lymph node (MA:0000139)

##### Histopath Description:

The mesenteric lymph node is enlarged more than three-fold. Its architecture is altered by large numbers of monomorphic lymphocytes that fill and distend all the sinuses and elevate the capsule. The neoplastic cells have generally a scant amount of eosinophilic cytoplasm, medium sized round central nucleus with granular chromatin, and single variably distinct amphophilic nucleoli. Mitotic figures are (less than 1/HPF).

##### Morphological Diagnosis:

**MPATH Diagnosis:** lymphoma [obsolete use MPATH:516 or 535] MPATH:343

##### Definitive Diagnosis:

Lymphoma

**Histopathology Comments:**

The lesion is suggestive of an early lymphoma of the mesenteric lymph node.

**testis (MA:0000411)****Histopath Description:**

Nearly 80% of the seminiferous tubules are vacuolated and hypocellular with fewer spermatids and no or minimum numbers of spermatocytes. Apoptotic bodies and multinucleated cells are frequent.

**Morphological Diagnosis:**

**Distribution:** Multifocal; **Severity:** severe; **MPATH Diagnosis:** atrophy MPATH:127

**Definitive Diagnosis:**

Testicular degeneration and atrophy with apoptosis and multinucleated cells, vacuolation of sertoli cells.

**epididymal duct (MA:0001735)****Histopath Description:**

The epididymal duct in all segments contains abundant cellular debris. Spermatocytes are not present.

**Morphological Diagnosis:**

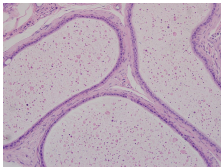
**Distribution:** Diffuse; **Severity:** extreme; **MPATH Diagnosis:** atrophy MPATH:127

**Definitive Diagnosis:**

Epididymal aspermia

**Histopathology Comments:**

The absence of spermatocytes within the epididymis is consistent with the changes in the seminiferous tubules.



Epididymal duct,  
hypospermia, 20x

**bone marrow (MA:0000134)****Histopath Description:**

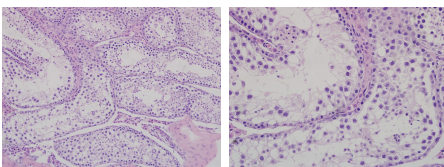
Erythroid cells are decreased (Myloid erythroid ration is 8:1 or more in many foci).

**Morphological Diagnosis:**

**Severity:** moderate; **MPATH Diagnosis:** hypoplasia MPATH:133

**Definitive Diagnosis:**

Erythroid hypoplasia



Testis, testicular  
degeneration, 20x

Testis, testicular  
degeneration, 40x

**AnimalID: M00338492 Sms hom****Tissue Preservation and Staining:**

Tissues not present in submission: Calvarium, ears, tongue, Harderian gland, zymbal gland, nasal sinuses, teeth, gall bladder.

**Histopathology Findings:****liver (MA:0000358)****Histopath Description:**

The overall hepatic lobular architecture is normal. Nearly 10-15% of hepatocytes notably within the midzonal region contain large (8-12 um in diameter) intracytoplasmic clear vacuoles (macrovesicular lipid). Rare small clusters of lymphocytes are present.

**Morphological Diagnosis:**

**Distribution:** Multifocal; **Severity:** mild; **MPATH Diagnosis:** lipid deposition MPATH:42

**Definitive Diagnosis:**

Hepatic lipidosis; multifocal inflammatory foci

**Histopathology Comments:**

Hepatocellular vacuolar change of variable degree suggestive of lipidosis is present in all mice from WTSI, consistent with high lipid diet. The changes in this mouse are less severe.

**stomach (MA:0000353)****Histopath Description:**

there are large numbers of eosinophils and lower numbers of lymphocytes and plasma cells within the submucosa and muscularis. The glandular epithelium is hyperplastic with prominence of mucous glands.

**Morphological Diagnosis:**

**Distribution:** Multifocal; **Severity:** mild; **MPATH Diagnosis:** inflammation MPATH:212

**Definitive Diagnosis:**

Eosinophilic gastritis with glandular hyperplasia

**brain (MA:0000168)****Histopath Description:**

There is a mild enlargement of the lateral ventricle.

**Morphological Diagnosis:**

**Severity:** mild; **MPATH Diagnosis:** hydrocephalus MPATH:639

**Definitive Diagnosis:**

hydrocephalus, lateral ventricle

**Histopathology Comments:**

Variable degree of hydrocephalus is observed in a proportion of wild type C57 Black 6 mice.

**Organ/Tissue Analyzed:**

There were no significant findings in the following tissues: eyes, ears, tongue, Harderian gland, zymbal gland, salivary glands, nasal sinuses, teeth, trachea, lungs, heart, thymus, thyroid gland, parathyroid gland, spleen, lgall bladder, exocrine and endocrine pancreas, esophagus, stomach, intestines, urinary organs and tract, adrenal gland, reproductive organs, lymph nodes, spinal cord, bones, bone marrow, skeletal muscles, brown fat, and skin.

**AnimalID: M00338493 Sms hom****Tissue Preservation and Staining:**

There is artifactual separation of the dermis and hypodermis. There is artifactual tissue fracture in the brain. Tissues not present in submission: Calvarium, ears, tongue, Harderian gland, zymbal gland, nasal sinuses, teeth, gall bladder.

**Histopathology Findings:****spleen (MA:0000141)****Histopath Description:**

Multiple germinal centers with proliferative lymphocytes and apoptotic bodies are present. The marginal zone is mildly expanded in all lymphoid nodules.

**Morphological Diagnosis:**

**Duration:** Chronic-active; **Distribution:** Multifocal; **Severity:** mild; **MPATH Diagnosis:** hyperplasia MPATH:134

**Definitive Diagnosis:**

Germinal zone hyperplasia; follicular hyperplasia

**Organ/Tissue Analyzed:**

There were no significant findings in the following tissues: brain, eyes, ears, tongue, Harderian gland, zymbal gland, salivary glands, nasal sinuses, teeth, trachea, lungs, heart, thymus, thyroid gland, parathyroid gland, liver, gall bladder, exocrine and endocrine pancreas, esophagus, stomach, intestines, urinary organs and tract, adrenal gland, reproductive organs, lymph nodes, spinal cord, bones, bone marrow, skeletal muscles, brown fat, and skin.

**Summary:**

Marked testicular degeneration and epididymal hypospermia is present in this line. Two mice have mild myeloid/granulocytic hyperplasia (00400348 M0040034). Other lesions are considered incidental.

**Report Summary and Recommendation:**

Marked testicular degeneration and epididymal hypospermia is present in this line. The lesion is consistent with abnormal fertility/fecundity observed during in-life phenotyping. Images from WT control are included for comparison. Two mice have mild myeloid/granulocytic hyperplasia (00400348 M0040034). Other lesions are considered incidental.

Testis: Degenerative change : MPATH:14