



CMHD Pathology Report



CMHD Pathology Core

Toronto Centre for
Phenogenomics
25 Orde St. 3rd fl.
Toronto, Ont. M5T 3H7
Tel.(416) 586-8375
Fax (416) 586-5993

contact: Dr. Susan
Newbigging
email:
newbigging@lunenfeld.ca

Principle Investigator: Dr. Jacqui White

Institute: Wellcome Trust Sanger Institute
Address: Attn: Linda Read Wellcome Trust
Genome Campus Hinxton Cambridge CB10
1SA, UK

ReportID: Report Date: February 05,
2013
Pathologist: H. Adissu

Mouse Genetics Project

Wellcome Trust Sanger
Institute
Wellcome Trust Genome
Campus
Hinxton, Cambridge
CB10 1SA
UK

email:
MGPenquiries@sanger.ac.uk
[Mouse Portal](#)
[Europhenome](#)

CMHD LabID: N12-1507

Relevant History:

abnormal incisor morphology
abnormal snout morphology
asymmetric snout
short snout
upturned snout
narrow eye opening
abnormal tooth morphology
abnormal maxilla morphology
kyphosis
scoliosis
abnormal cranium morphology
abnormal spine curvature
abnormal vertebrae morphology
vertebral fusion
preweaning lethality
increased susceptibility to bacterial infection

AnimalID: M00356389 (Male)

Tissue Preservation and Staining:

Thyroid not present in section

Histopathology Findings:

lung (MA:0000415)

Histopath Description:

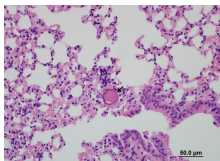
There is a focal 50 uM diameter osseous tissue within the lung interstitium

Morphological Diagnosis:

Distribution: focal; **Severity:** mild;

Definitive Diagnosis:

Focal osseous metaplasia



Focal osseous
metaplasia

liver (MA:0000358)

Histopath Description:

There is diffuse microvesicular lipidosis

Morphological Diagnosis:

Distribution: diffuse; **Severity:** severe; **MPATH Diagnosis:** steatosis MPATH:622

Definitive Diagnosis:

Hepatic lipidosis

thymus (MA:0000142)**Histopath Description:**

There are multifocal epithelial cyts (50-100 um in diameter)

Morphological Diagnosis:

Distribution: multifocal; **Severity:** mild; **MPATH Diagnosis:** cyst MPATH:62

Definitive Diagnosis:

Epithelial cyst

lymph node (MA:0000139)**Histopath Description:**

The mesenteric lymph node is enlarged (greater than three-fold). There are multiple follicles with large germinal centers. The sinuses contain large numbers of mature lymphocytes.

Morphological Diagnosis:

Duration: Sub-acute; **Distribution:** Diffuse; **Severity:** moderate; **MPATH Diagnosis:** hyperplasia MPATH:134

Definitive Diagnosis:

Lymphoid hyperplasia.

Histopathology Comments:

The changes in the mesenteric lymph node are suggestive of draining of a regional inflammatory process. However, such a process was not observed in the tissues examined.

salivary gland (MA:0000346)**Histopath Description:**

Focal perivascular mononuclear inflammatory infiltrate

Morphological Diagnosis:

Distribution: focal; **Severity:** mild;

Definitive Diagnosis:

Perivascular inflammatory infiltrate

brain (MA:0000168)**Histopath Description:**

mild hydrocephalus of the lateral ventricles

Morphological Diagnosis:

Distribution: bilateral; **Severity:** mild; **MPATH Diagnosis:** hydrocephalus MPATH:639

Definitive Diagnosis:

Mild hydrocephalus

Organ/Tissue Analyzed:

Histopathology examination included the following organs and tissues: brain, trigeminal ganglion, eyes, salivary glands, trachea, lungs, heart, thymus, thyroid gland, parathyroid gland, exocrine and endocrine pancreas, oesophagus, stomach, small intestine, large intestine, liver, gall bladder, spleen, kidneys, adrenal gland, lymph nodes, spinal cord, bone marrow, sternum, femur and tibia with associated skeletal muscles, brown fat, pinna, skin, testis, epididymis, seminal vesicle, and prostate.

AnimalID: M00435760 (Male)**Tissue Preservation and Staining:**

Thyroid not present in section; the skin is not well preserved.

Histopathology Findings:**liver (MA:0000358)****Histopath Description:**

There is diffuse microvesicular lipidosis

Morphological Diagnosis:

Distribution: diffuse; **Severity:** severe; **MPATH Diagnosis:** steatosis MPATH:622

Definitive Diagnosis:

Hepatic lipidosis

spleen (MA:0000141)**Histopath Description:**

marked erythroid hyperplasia. Lymphoid follicles are enlarged with many of them having germinal centres.

Morphological Diagnosis:

Severity: moderate; **MPATH Diagnosis:** extramedullary hemopoiesis MPATH:595

Definitive Diagnosis:

extramedullary erythroid hyperplasia; lymphoid hyperplasia

Organ/Tissue Analyzed:

Histopathology examination included the following organs and tissues: brain, trigeminal ganglion, eyes, salivary glands, trachea, lungs, heart, thymus, thyroid gland, parathyroid gland, exocrine and endocrine pancreas, oesophagus, stomach, small intestine, large intestine, liver, gall bladder, spleen, kidneys, adrenal gland, lymph nodes, spinal cord, bone marrow, sternum, femur and tibia with associated skeletal muscles, brown fat, pinna, skin, testis, epididymis, seminal vesicle, and prostate.

AnimalID: M00435763 (Female)**Tissue Preservation and Staining:**

Thyroid not present in section

Histopathology Findings:**liver (MA:0000358)****Histopath Description:**

There is diffuse microvesicular lipodosis

Morphological Diagnosis:

Distribution: diffuse; **Severity:** severe; **MPATH Diagnosis:** steatosis MPATH:622

Definitive Diagnosis:

Hepatic lipodosis

lymph node (MA:0000139)**Histopath Description:**

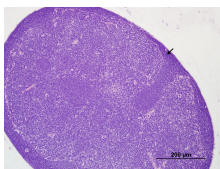
The architecture of two superficial cervical lymph nodes is altered by the presence of large numbers of monomorphic lymphocytes filling and distending all the sinuses and elevating the capsule. The neoplastic cells have generally a scant amount of eosinophilic cytoplasm, medium sized round central nucleus with granular chromatin and single variably distinct amphophilic nucleoli. Mitotic figures are less than 1/HPF.

Morphological Diagnosis:

Distribution: Diffuse; **MPATH Diagnosis:** lymphoid neoplasms MPATH:513

Definitive Diagnosis:

Lymphoma



Lymphoma

spleen (MA:0000141)**Histopath Description:**

marked erythroid hyperplasia. Lymphoid follicles are enlarged with many of them having germinal centres.

Morphological Diagnosis:

Severity: moderate; **MPATH Diagnosis:** extramedullary hemopoiesis MPATH:595

Definitive Diagnosis:

extramedullary erythroid hyperplasia; lymphoid hyperplasia

stomach (MA:0000353)**Histopath Description:**

moderate neutrophilic gastritis

Morphological Diagnosis:

Distribution: multifocal to coalescing; **Severity:** moderate;
Definitive Diagnosis:
Gastritis, neutrophilic

brain (MA:0000168)

Histopath Description:
mild hydrocephalus of the lateral ventricles

Morphological Diagnosis:

Distribution: bilateral; **Severity:** mild; **MPATH Diagnosis:** hydrocephalus MPATH:639

Definitive Diagnosis:

Mild hydrocephalus

Organ/Tissue Analyzed:

Histopathology examination included the following organs and tissues: brain, trigeminal ganglion, eyes, salivary glands, trachea, lungs, heart, thymus, thyroid gland, parathyroid gland, exocrine and endocrine pancreas, oesophagus, stomach, small intestine, large intestine, liver, gall bladder, spleen, kidneys, adrenal gland, lymph nodes, spinal cord, bone marrow, sternum, femur and tibia with associated skeletal muscles, brown fat, pinna, skin, uterus, oviduct, and ovary, and mammary gland.

AnimalID: M00356390 (Female)

Tissue Preservation and Staining:

Thyroid not present in section

Histopathology Findings:

liver (MA:0000358)

Histopath Description:

There is diffuse microvesicular lipidosis

Morphological Diagnosis:

Distribution: diffuse; **Severity:** severe; **MPATH Diagnosis:** steatosis MPATH:622

Definitive Diagnosis:

Hepatic lipidosis

lymph node (MA:0000139)

Histopath Description:

The mesenteric lymph node is enlarged (greater than three-fold). There are multiple follicles with large germinal centers. The sinuses contain large numbers of mature lymphocytes.

Morphological Diagnosis:

Duration: Sub-acute; **Distribution:** Diffuse; **Severity:** moderate;

Definitive Diagnosis:

Lymphoid hyperplasia.

Histopathology Comments:

The changes in the mesenteric lymph node are suggestive of draining of a regional inflammatory process. However, such a process was not observed in the tissues examined.

eye (MA:0000261)

Histopath Description:

One of the eyes is small (less than half of a normal eye). It is composed of a cavity lined by a thickened layers of retina and a thick wall of pigmented choroid. The lens and cornea are not present in section.

Morphological Diagnosis:

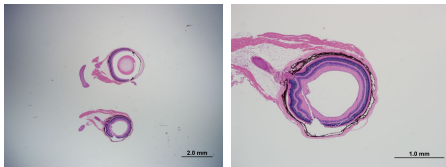
Distribution: Unilateral;

Definitive Diagnosis:

Microphthalmia, unilateral

Histopathology Comments:

Microphthalmia and other ocular defects are noted as incidental lesion in C57BL6/B6 mice.



Microphthalmia,
unilateral

Microphthalmia,
unilateral

brain (MA:0000168)

Histopath Description:

mild hydrocephalus of the lateral ventricles

Morphological Diagnosis:

Distribution: bilateral; **Severity:** mild; **MPATH Diagnosis:** hydrocephalus MPATH:639

Definitive Diagnosis:

Mild hydrocephalus

Organ/Tissue Analyzed:

Histopathology examination included the following organs and tissues: brain, trigeminal ganglion, eyes, salivary glands, trachea, lungs, heart, thymus, thyroid gland, parathyroid gland, exocrine and endocrine pancreas, oesophagus, stomach, small intestine, large intestine, liver, gall bladder, spleen, kidneys, adrenal gland, lymph nodes, spinal cord, bone marrow, sternum, femur and tibia with associated skeletal muscles, brown fat, pinna, skin, uterus, oviduct, and ovary, and mammary gland.

Report Summary and Recommendation:

The microphthalmia in one mouse may explain narrow eye opening reported in some mice in this line. Other lesions are considered incidental. The morphological abnormalities involving the cranium, incisors, snout, and vertebra are difficult to ascertain by histopathology.