



## CMHD Pathology Report



### CMHD Pathology Core

Toronto Centre for  
Phenogenomics  
25 Orde St. 3rd fl.  
Toronto, Ont. M5T 3H7  
Tel.(416) 586-8375  
Fax (416) 586-5993

contact: Dr. Susan  
Newbigging  
email:  
[newbigging@lunenfeld.ca](mailto:newbigging@lunenfeld.ca)

### Principle Investigator: Dr. Colin McKerlie ICSIG

Institute: Sick Kids  
Address:

ReportID: Report Date: November 23,  
2011  
Pathologist: H. Adissu

### Mouse Genetics Project

Wellcome Trust Sanger  
Institute  
Wellcome Trust Genome  
Campus  
Hinxton, Cambridge  
CB10 1SA  
UK

email:  
[MGPenquiries@sanger.ac.uk](mailto:MGPenquiries@sanger.ac.uk)  
[Mouse Portal](#)  
[Europhenome](#)

CMHD LabID: N11-195

---

### AnimalID: M00365888 FundC1 hem

#### Tissue Preservation and Staining:

The thyroid gland is not present in section. Tissues not present in submission: Calvarium, ears, tongue, Harderian gland, zymbal gland, nasal sinuses, teeth, gall bladder.

#### Histopathology Findings:

##### liver (MA:0000358)

##### Histopath Description:

The overall hepatic lobular architecture is normal. Nearly 50 of hepatocytes notably within the midzonal region contain large (8-12 um in diameter) intracytoplasmic clear vacuoles (macrovesicular lipid).

##### Morphological Diagnosis:

**Distribution:** Multifocal; **Severity:** mild; **MPATH Diagnosis:** lipid deposition MPATH:42

##### Definitive Diagnosis:

Hepatic lipodosis; multifocal inflammatory foci

##### Histopathology Comments:

Hepatocellular vacuolar change of variable degree suggestive of lipodosis is present in all mice from WTSI, consistent with high lipid diet.

##### stomach (MA:0000353)

##### Histopath Description:

There are rare neutrophils and eosinophils within the lamina propria of the glandular region at the limiting ridge.

##### Morphological Diagnosis:

**Duration:** Sub-acute; **Distribution:** Multifocal; **Severity:** mild; **MPATH Diagnosis:** inflammation MPATH:212

##### Definitive Diagnosis:

Gastritis, suppurative

##### Histopathology Comments:

This lesion is most commonly associated with Helicobacter infection. Further investigation is suggested using histochemistry (Silver stain) or colony fecal PCR.

#### Organ/Tissue Analyzed:

NSF will be appended

---

### AnimalID: M00365889 FundC1 hem

#### Tissue Preservation and Staining:

There is artifactual separation of the dermis and hypodermis. The thyroid gland is not present in section. Tissues not present in submission: Calvarium, ears, tongue, Harderian gland, zymbal gland, nasal sinuses, teeth, gall bladder.

**Histopathology Findings:****lymph node (MA:0000139)****Histopath Description:**

The mesenteric lymph node is enlarged (greater than two-fold). There are multiple follicles with large germinal centers. The sinuses contain large numbers of mature lymphocytes. The subcapsular sinuses contain large numbers of lymphocytes that multifocally elevate the capsule.

**Morphological Diagnosis:**

**Duration:** Sub-acute; **Distribution:** Diffuse; **Severity:** moderate; **MPATH Diagnosis:** hyperplasia MPATH:134

**Definitive Diagnosis:**

Lymphoid hyperplasia.

**Histopathology Comments:**

The changes in the mesenteric lymph node are suggestive of draining of a regional inflammatory process. However, such a process was not observed in the tissues examined.

**Organ/Tissue Analyzed:**

NSF will be appended

**AnimalID: M00393215 FundC1 hem****Tissue Preservation and Staining:**

The thyroid gland is not present in section. Tissues not present in submission: Calvarium, ears, tongue, Harderian gland, zymbal gland, nasal sinuses, teeth, gall bladder.

**Histopathology Findings:****liver (MA:0000358)****Histopath Description:**

The overall hepatic lobular architecture is normal. Diffusely, hepatocytes contain intracytoplasmic clear vacuoles (lipid). The lipid vacuoles within the midzonal and periportal regions are small (2-3 um in diameter) and surround a central nucleus (interpreted as microvesicular lipid). The lipid vacuoles within the portal areas are large (8-12 um in diameter) and displace the nucleus to the margin (macrovesicular lipid). There is a small (100x200 um) focal necrosis surrounded by numerous neutrophils.

**Morphological Diagnosis:**

**Distribution:** Diffuse; **Severity:** moderate; **MPATH Diagnosis:** lipid deposition MPATH:42

**Definitive Diagnosis:**

Hepatic lipidosis with focal hepatic coagulative necrosis

**Histopathology Comments:**

Hepatocellular vacuolar change of variable degree suggestive of lipidosis is present in all mice from WTS1, consistent with high lipid diet.

**mesenteric lymph node (MA:0002829)****Histopath Description:**

There are large numbers of histiocytes within the medullary and paracortical sinuses. There is a focal expansive germinal center proliferation of pleomorphic round cells with prominent pale background (as described in mouse M00393215). Mitosis is rare in this focus

**Morphological Diagnosis:**

**Distribution:** Multifocal; **Severity:** mild; **MPATH Diagnosis:** histiocytosis MPATH:146

**Definitive Diagnosis:**

Sinus histiocytosis with focal germinal center lymphoid hyperplasia.

**Histopathology Comments:**

The cause for sinus histiocytosis is not determined. The focal germinal center proliferation is atypical and may represent an early stage of follicular center B cell lymphoma.

**Organ/Tissue Analyzed:**

NSF will be appended

**AnimalID: M00393223 FundC1 hem****Tissue Preservation and Staining:**

There is artifactual separation of the dermis and hypodermis. The thyroid gland is not present in section. Tissues not present in submission: Calvarium, ears, tongue, Harderian gland, zymbal gland, nasal sinuses, teeth, gall bladder.

**Histopathology Findings:****superficial cervical lymph node (MA:0002886)****Histopath Description:**

The cervical lymph node is enlarged nearly 4x normal by multifocal to coalescing sheets and clusters of pleomorphic round cells that obliterated the normal lymphoid architecture. The neoplastic round cells are pleomorphic but mainly are large and cohesive with irregularly shaped, folded and cleaved or notched nuclei, and variably abundant pale fibrillar cytoplasm. There is up to three fold cell and nuclear size variation between the neoplastic cells. Resident lymphocytes are engulfed or displaced to the cortex.

**Morphological Diagnosis:**

**Distribution:** Multifocal to coalescing; **MPATH Diagnosis:** follicular b cell lymphoma MPATH:522

**Definitive Diagnosis:**

Follicular center lymphoma, mixed cell type with predominance of large cells

**Histopathology Comments:**

This neoplasm is currently referred to as follicular B cell lymphoma. The spleen, mesenteric lymph nodes and Peyer's patches of the ileum are the most commonly involved sites. The disease is rare before 12 months of age and may increase dramatically in some strains after 18 months. Recently, there is a suggestion that some tumors with this histological feature may be a composite of histiocytic sarcoma and malignant lymphoma

**mesenteric lymph node (MA:0002829)****Histopath Description:**

Lesions are similar to those seen in cervical lymph node

**Morphological Diagnosis:**

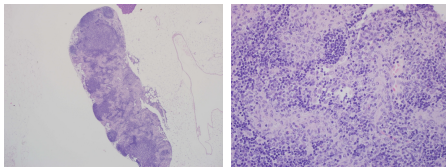
**MPATH Diagnosis:** follicular b cell lymphoma MPATH:522

**Definitive Diagnosis:**

Follicular center lymphoma, mixed cell type with predominance of large cells

**Histopathology Comments:**

see comment above



Mesenteric lymph node-Brown fat 4x

Mesenteric lymph node 40x

**liver (MA:0000358)****Histopath Description:**

The overall hepatic lobular architecture is normal. Diffusely, hepatocytes contain intracytoplasmic clear vacuoles (lipid). The lipid vacuoles within the midzonal and periacinar regions are small (2-3 um in diameter) and surround a central nucleus (interpreted as microvesicular lipid). The lipid vacuoles within the portal areas are large (8-12 um in diameter) and displace the nucleus to the margin (macrovesicular lipid). There is a small (100x200 um) focal necrosis surrounded by numerous neutrophils.

**Morphological Diagnosis:**

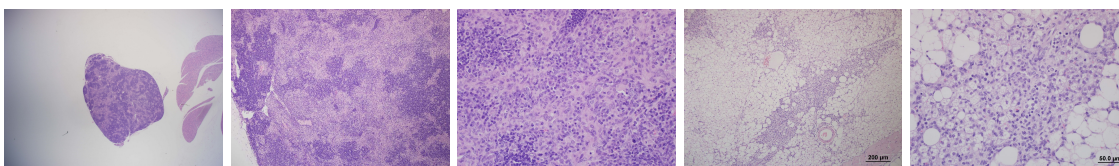
**Distribution:** Diffuse; **Severity:** moderate; **MPATH Diagnosis:** lipid deposition MPATH:42

**Definitive Diagnosis:**

Hepatic lipidosis with focal hepatic coagulative necrosis

**Histopathology Comments:**

Hepatocellular vacuolar change of variable degree suggestive of lipidosis is present in all mice from WTSI, consistent with high lipid diet.



Cervical lymph node 10x

Cervical lymph node 10x

Cervical lymph node 40x

Brown fat-Cervical lymph node 10x

Brown fat 40x

**Organ/Tissue Analyzed:**

NSF will be appended

**Summary:**

In two of the mice (M00393223 and M00393215), lymphoid proliferative lesion suggestive of follicular B cell lymphomas were seen.

**Report Summary and Recommendation:**

In two of the mice (M00393223 and M00393215), lymphoid proliferative lesion suggestive of follicular B cell lymphomas were seen.

Lymph node: precursor b cell neoplasms MPATH:517

**References:**

C.H. Frith and J.M. Ward .Color Atlas of Neoplastic and Non-neoplastic Lesions in Aging Mice. Elsevier 1988  
Hao X et al. (2010). The Histopathologic and Molecular Basis for the Diagnosis of Histiocytic Sarcoma and Histiocyte-Associated Lymphoma of Mice. Veterinary Pathology. Veterinary Pathology 47(3) 434-445