



CMHD Pathology Report



CMHD Pathology Core

Toronto Centre for
Phenogenomics
25 Orde St. 3rd fl.
Toronto, Ont. M5T 3H7
Tel.(416) 586-8375
Fax (416) 586-5993

contact: Dr. Susan
Newbigging
email:
newbigging@lunenfeld.ca

Principle Investigator: Dr. Colin McKerlie ICSIG

Institute: Sick Kids
Address:

ReportID: Report Date: November 23,
2011
Pathologist: H. Adissu

Mouse Genetics Project

Wellcome Trust Sanger
Institute
Wellcome Trust Genome
Campus
Hinxton, Cambridge
CB10 1SA
UK

email:
MGPenquiries@sanger.ac.uk
[Mouse Portal](#)
[Europhenome](#)

CMHD LabID: N11-200

AnimalID: M00236902 Nipa homo

Histopathology Findings:

liver (MA:0000358)

Histopath Description:

The overall hepatic lobular architecture is normal. Approximately 5% of hepatocytes within the midzonal region contain large (8-12 um in diameter) intracytoplasmic clear vacuoles (macrovesicular lipid).

Morphological Diagnosis:

Distribution: Multifocal; **Severity:** no lesions; **MPATH Diagnosis:** lipid deposition MPATH:42

Definitive Diagnosis:

Hepatic lipidosis.

Histopathology Comments:

The hepatic lipidosis is considered very mild compared to many WTSI lines.

kidney (MA:0000368)

Histopath Description:

There is a focal aggregate of lymphocytes, plasma cells and macrophages within the submucosa of the renal pelvis.

Morphological Diagnosis:

Duration: Chronic; **Distribution:** Focal; **Severity:** mild; **MPATH Diagnosis:** inflammation MPATH:212

Definitive Diagnosis:

Chronic pyelitis

Histopathology Comments:

Incidental lesion usually associated with retrograde bacterial infection

AnimalID: M00236903 Nipa homo

Tissue Preservation and Staining:

There is artifactual separation of the dermis and the subcutis

Histopathology Findings:

liver (MA:0000358)

Histopath Description:

The overall hepatic lobular architecture is normal. Approximately 5% of hepatocytes within the midzonal and pericentral region contain large (8-12 um in diameter) intracytoplasmic clear vacuoles (macrovesicular lipid).

Morphological Diagnosis:

Distribution: Multifocal; **Severity:** no lesions; **MPATH Diagnosis:** lipid deposition MPATH:42

Definitive Diagnosis:

Hepatic lipidosis.

Histopathology Comments:

Hepatocellular vacuolar change of variable degree suggestive of lipidosis is present in all mice from WTSI, consistent with high lipid diet.

AnimalID: M00236905 Nipa homo**Tissue Preservation and Staining:**

There is artifactual separation of the dermis and the subcutis

Histopathology Findings:**adrenal gland (MA:0000116)****Histopath Description:**

Adrenal cortical cells immediately surrounding the medulla are vacuolated and contain fine granular golden brown cytoplasmic pigment. Rare mononuclear cells are present within this zone.

Morphological Diagnosis:

Distribution: Diffuse; **Severity:** no lesions; **MPATH Diagnosis:** degenerative change MPATH:14

Definitive Diagnosis:

Vacuolar degeneration of X-zone of the adrenal gland with cytoplasmic ceroid accumulation (X-zone involution).

Histopathology Comments:

The X zone of the adrenal cortex disappears when males reach sexual maturity and females undergo their first pregnancy. The zone also disappears in virgin females, albeit gradually (Percy and Barthold, 2007).

liver (MA:0000358)**Histopath Description:**

There is diffuse hepatic lipidosis.

Morphological Diagnosis:

Distribution: Diffuse; **Severity:** severe; **MPATH Diagnosis:** lipid deposition MPATH:42

Definitive Diagnosis:

Hepatic lipiposis

salivary gland (MA:0000346)**Histopath Description:**

There are multifocal interstitial mononuclear inflammatory aggregates.

Morphological Diagnosis:

Distribution: Multifocal; **Severity:** mild; **MPATH Diagnosis:** inflammation MPATH:212

Definitive Diagnosis:

Interstitial mononuclear inflammatory infiltrate

stomach (MA:0000353)**Histopath Description:**

There are rare eosinophils and neutrophils within the lamina propria at the limiting ridge.

Morphological Diagnosis:

Duration: Sub-acute; **Distribution:** Multifocal; **Severity:** mild; **MPATH Diagnosis:** inflammation MPATH:212

Definitive Diagnosis:

Gastritis, suppurative

Histopathology Comments:

This lesion is most commonly associated with Helicobacter infection. Further investigation is suggested using histochemistry (Silver stain) or colony fecal PCR.

AnimalID: M00232245 Nipa homo**Histopathology Findings:**

adrenal gland (MA:0000116)**Histopath Description:**

Adrenal cortical cells immediately surrounding the medulla are vacuolated and contain fine granular golden brown cytoplasmic pigment. Rare mononuclear cells are present within this zone.

Morphological Diagnosis:

Distribution: Diffuse; **Severity:** no lesions; **MPATH Diagnosis:** degenerative change MPATH:14

Definitive Diagnosis:

Vacuolar degeneration of X-zone of the adrenal gland with cytoplasmic ceroid accumulation (X-zone involution).

Histopathology Comments:

The X zone of the adrenal cortex disappears when males reach sexual maturity and females undergo their first pregnancy. The zone also disappears in virgin females, albeit gradually (Percy and Barthold, 2007).

liver (MA:0000358)**Histopath Description:**

There is diffuse hepatic lipidosis.

Morphological Diagnosis:

Distribution: Diffuse; **Severity:** severe; **MPATH Diagnosis:** lipid deposition MPATH:42

Definitive Diagnosis:

Hepatic lipidosis

stomach (MA:0000353)**Histopath Description:**

There are rare eosinophils and neutrophils within the lamina propria at the limiting ridge.

Morphological Diagnosis:

Duration: Sub-acute; **Distribution:** Multifocal; **Severity:** mild; **MPATH Diagnosis:** inflammation MPATH:212

Definitive Diagnosis:

Gastritis, suppurative

Histopathology Comments:

This lesion is most commonly associated with Helicobacter infection. Further investigation is suggested using histochemistry (Silver stain) or colony fecal PCR.

AnimalID: M00232250 Nipa homo**Tissue Preservation and Staining:**

Thyroid gland is not present in section

Histopathology Findings:**adrenal gland (MA:0000116)****Histopath Description:**

Adrenal cortical cells immediately surrounding the medulla are vacuolated and contain fine granular golden brown cytoplasmic pigment. Rare mononuclear cells are present within this zone.

Morphological Diagnosis:

Distribution: Diffuse; **Severity:** no lesions; **MPATH Diagnosis:** degenerative change MPATH:14

Definitive Diagnosis:

Vacuolar degeneration of X-zone of the adrenal gland with cytoplasmic ceroid accumulation (X-zone involution).

Histopathology Comments:

The X zone of the adrenal cortex disappears when males reach sexual maturity and females undergo their first pregnancy. The zone also disappears in virgin females, albeit gradually (Percy and Barthold, 2007).

liver (MA:0000358)**Histopath Description:**

There is diffuse hepatic lipidosis.

Morphological Diagnosis:

Distribution: Diffuse; **Severity:** severe; **MPATH Diagnosis:** lipid deposition MPATH:42

Definitive Diagnosis:

Hepatic liposis

uterus (MA:0000389)**Histopath Description:**

The uterine lumen is distended up to 8 mm diameter by a granular proteinaceous material and small amount of cellular debris. The submucosa contains low numbers of neutrophils, lymphocytes, and macrophages. Small amount of karyorrhectic debris is present within the epithelium.

Morphological Diagnosis:

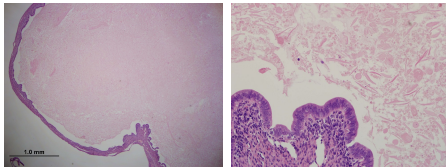
Duration: Chronic; **Distribution:** Diffuse; **Severity:** severe;

Definitive Diagnosis:

Hydrometra

Histopathology Comments:

The lesion is likely caused by occlusive vaginal lesion that blocked normal discharge of uterine fluid (see below)



Uterus, hydrometra, 4x, HE Uterus, hydrometra, 40x, HE

vagina (MA:0000394)**Histopath Description:**

The vaginal lumen is distended up to 7 mm in diameter with proteinaceous granular material and occasional keratin aggregates admixed with cellular debris. The vaginal epithelium is hypertrophic and markedly vacuolated. The submucosa and the muscular layers are infiltrated by large numbers of neutrophils, lymphocytes, plasma cells and macrophages.

Morphological Diagnosis:

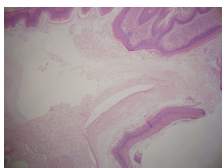
Duration: Chronic-active; **Distribution:** Diffuse; **Severity:** severe; **MPATH Diagnosis:** inflammation MPATH:212

Definitive Diagnosis:

Suppurative gastritis with luminal distention with cellular and keratin debris

Histopathology Comments:

The vaginal lesion likely precipitated the hydrometra.



Vagina, 4x

stomach (MA:0000353)**Histopath Description:**

There are large numbers of neutrophils within the lamina propria at the limiting ridge.

Morphological Diagnosis:

Duration: Sub-acute; **Distribution:** Multifocal; **Severity:** mild; **MPATH Diagnosis:** inflammation MPATH:212

Definitive Diagnosis:

Gastritis, suppurative

Histopathology Comments:

This lesion is most commonly associated with Helicobacter infection. Further investigation is suggested using histochemistry (Silver stain) or colony fecal PCR.

Report Summary and Recommendation:

Hydrometra was observed in one mouse. This finding together with the role of the gene Nipa in ion transport suggests that this may be a significant pathology in this line.

Uterus: degenerative change MPATH:14

