



CMHD Pathology Report



CMHD Pathology Core

Toronto Centre for
Phenogenomics
25 Orde St. 3rd fl.
Toronto, Ont. M5T 3H7
Tel.(416) 586-8375
Fax (416) 586-5993

contact: Dr. Susan
Newbigging
email:
newbigging@lunenfeld.ca

Principle Investigator: Dr. Colin McKerlie

ICSIG
Institute: Sick Kids
Address:

ReportID: Report Date: November 03,
2011
Pathologist: H. Adissu

Mouse Genetics Project

Wellcome Trust Sanger
Institute
Wellcome Trust Genome
Campus
Hinxton, Cambridge
CB10 1SA
UK

email:
MGPenquiries@sanger.ac.uk
[Mouse Portal](#)
[Europhenome](#)

CMHD LabID: N11-368

Relevant History:

(Modified SHIRPA; X-ray Imaging; Plasma Chemistry; Plasma Immunoglobulins; Haematology (CBC); Peripheral Blood Lymphocytes)

AnimalID: M00256321 Sytl1 hom

Tissue Preservation and Staining:

The thyroid gland is not present in section

Histopathology Findings:

thymus (MA:0000142)

Histopath Description:

There is a 1 mm diameter cyst that contains a proteinaceous material and sloughed cells within the lumen, and is lined segmentally by squamous epithelium

Morphological Diagnosis:

Distribution: Focal; **Severity:** mild; **MPATH Diagnosis:** cyst MPATH:62

Definitive Diagnosis:

Thymic cyst

Histopathology Comments:

This is an incidental lesion

epididymis (MA:0000397)

Histopath Description:

There are clusters of lymphocytes and plasma cells surrounding and abutting the tail of epididymis

Morphological Diagnosis:

Distribution: Multifocal; **Severity:** mild; **MPATH Diagnosis:** inflammation MPATH:212

Definitive Diagnosis:

Periepididymitis, lymphoplasmacytic, multifocal

brain (MA:0000168)

Histopath Description:

Blood vessels within the meninges and pila investments in different parts of the brain are surrounded by lymphocytes, macrophages, and rare neutrophils. Occasional neutrophils are embedded within the neuropil of the hippocampus. Rare cells with pyknotic neurons and eosinophilic cytoplasm are present within the parenchyma (necrosis).

Morphological Diagnosis:

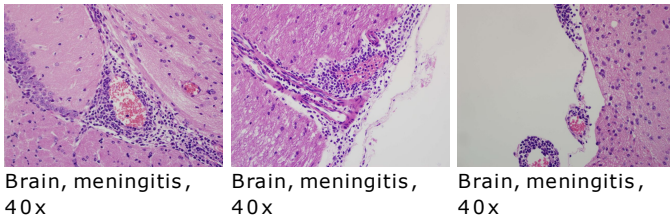
Distribution: Multifocal; **Severity:** moderate; **MPATH Diagnosis:** inflammation MPATH:212

Definitive Diagnosis:

Meningitis, lymphocytic and neutrophilic

Histopathology Comments:

The lesion suggests a chronic active meningitis, the cause of which is not apparent.

Brain, meningitis,
40xBrain, meningitis,
40xBrain, meningitis,
40x

AnimalID: M00256322 Sytl1 hom

Tissue Preservation and Staining:

The thyroid gland is not present in section

Histopathology Findings:

liver (MA:0000358)

Histopath Description:

There is diffuse hepatic lipidosis.

Morphological Diagnosis:

Distribution: Diffuse; **Severity:** severe; **MPATH Diagnosis:** lipid deposition MPATH:42

Definitive Diagnosis:

Hepatic lipisosis

thymus (MA:0000142)

Histopath Description:

There are three 250-200 um diameter cysts within the medulla. All contain proteinaceous material and sloughed cells within their lumina and are segmentally by squamous epithelium

Morphological Diagnosis:

Distribution: Focal; **Severity:** mild; **MPATH Diagnosis:** cyst MPATH:62

Definitive Diagnosis:

Thymic cysts

Histopathology Comments:

This is an incidental lesion

epididymis (MA:0000397)

Histopath Description:

There are clusters of lymphocytes and plasma cells surrounding and abutting the tail of epididymis

Morphological Diagnosis:

Distribution: Multifocal; **Severity:** mild; **MPATH Diagnosis:** inflammation MPATH:212

Definitive Diagnosis:

Periepididymitis, lymphoplasmacytic, multifocal

AnimalID: M00256325 Sytl1 hom

Tissue Preservation and Staining:

The thyroid gland is not present in section

Histopathology Findings:

liver (MA:0000358)

Histopath Description:

There is diffuse hepatic lipidosis.

Morphological Diagnosis:

Distribution: Diffuse; **Severity:** severe; **MPATH Diagnosis:** lipid deposition MPATH:42

Definitive Diagnosis:

Hepatic lipisosis

AnimalID: M00256326 Sytl1 hom**Tissue Preservation and Staining:**

The thyroid gland is not present in section

Histopathology Findings:**liver (MA:0000358)****Histopath Description:**

There is diffuse hepatic lipidosis.

Morphological Diagnosis:

Distribution: Diffuse; **Severity:** severe; **MPATH Diagnosis:** lipid deposition MPATH:42

Definitive Diagnosis:

Hepatic lipiposis

stomach (MA:0000353)**Histopath Description:**

There are large numbers of neutrophils and moderate numbers of eosinophils within the lamina propria of the glandular region at the limiting ridge.

Morphological Diagnosis:

Duration: Sub-acute; **Distribution:** Multifocal; **Severity:** moderate; **MPATH Diagnosis:** inflammation MPATH:212

Definitive Diagnosis:

Gastritis, suppurative

Histopathology Comments:

This lesion is most commonly associated with Helicobacter infection. Further investigation is suggested using histochemistry (Silver stain) or colony fecal PCR. The presence of eosinophils suggest allergic cause.

Report Summary and Recommendation:

Meningitis (1/4) and periepididymitis (2/2) may be relevant in view of the various in-life immune phenotype.

Epididymis and brain: chronic inflammation MPATH:214