



# CMHD Pathology Report



## CMHD Pathology Core

Toronto Centre for  
Phenogenomics  
25 Orde St. 3rd fl.  
Toronto, Ont. M5T 3H7  
Tel.(416) 586-8375  
Fax (416) 586-5993

contact: Dr. Susan  
Newbigging  
email:  
[newbigging@lunenfeld.ca](mailto:newbigging@lunenfeld.ca)

## Principle Investigator: Dr. Colin McKerlie ICSIG

Institute: Sick Kids  
Address:

ReportID: Report Date: November 23,  
2011  
Pathologist: H. Adissu

## Mouse Genetics Project

Wellcome Trust Sanger  
Institute  
Wellcome Trust Genome  
Campus  
Hinxton, Cambridge  
CB10 1SA  
UK

email:  
[MGPenquiries@sanger.ac.uk](mailto:MGPenquiries@sanger.ac.uk)  
[Mouse Portal](#)  
[Europhenome](#)

CMHD LabID: N11-184

## Relevant History:

(Body Weight Curves; Indirect Calorimetry; Body Composition (DEXA); X-ray Imaging; Peripheral Blood Lymphocytes) Decreased body weight/length, increased T cell number, decreased respiratory quotient, multiple vertebral fusion/transformation, decreased rib number

## AnimalID: M00221134 Ppp5c homo

### Tissue Preservation and Staining:

Tissues not present in submission: Calvarium, ears, tongue, Harderian gland, zymbal gland, nasal sinuses, teeth, gall bladder.

### Histopathology Findings:

#### adrenal gland (MA:0000116)

##### Histopath Description:

Adrenal cortical cells immediately surrounding the medulla are vacuolated and contain fine granular golden brown cytoplasmic pigment. Rare mononuclear cells are present within this zone.

##### Morphological Diagnosis:

**Distribution:** Diffuse; **Severity:** no lesions; **MPATH Diagnosis:** degenerative change MPATH:14

##### Definitive Diagnosis:

Vacuolar degeneration of X-zone of the adenal gland with cytoplasmic ceroid accumulation (X-zone involution).

##### Histopathology Comments:

The X zone of the adrenal cortex disappears when males reach sexual maturity and females undergo their first pregnancy. The zone also disappears in virgin females, albeit graduall (Percy and Barthold, 2007).

#### liver (MA:0000358)

##### Histopath Description:

The overall hepatic lobular architecture is normal. Less than 5% of hepatocytes within the midzonal region contain large (8-12 um in diameter) intracytoplasmic clear vacuoles (macrovesicular lipid). Rare small clusters of lymphocytes are present.

##### Morphological Diagnosis:

**Distribution:** Multifocal; **Severity:** mild; **MPATH Diagnosis:** lipid deposition MPATH:42

##### Definitive Diagnosis:

Hepatic lipidosis

##### Histopathology Comments:

Hepatocellular vacuolar change of variable degree suggestive of lipidosis is present in all mice from WTSI, consistent with high lipid diet. The changes in this mouse are less severe.

#### liver (MA:0000358)

##### Histopath Description:

There are rare small mononuclear cells and neutrophils inflammatory cells within the liver.

##### Morphological Diagnosis:

**Duration:** Chronic-active; **Distribution:** Multifocal; **Severity:** mild; **MPATH Diagnosis:**

inflammation MPATH:212

**Definitive Diagnosis:**

Multifocal mononuclear inflammatory cell aggregates.

**lymph node (MA:0000139)**

**Histopath Description:**

The superficial cervical lymph nodes are enlarged more than two-fold and are markedly basophilic at low magnification Their architecture is altered by large numbers of monomorphic lymphocytes that fill and distend all the sinuses and elevate the capsule. The neoplastic cells have generally a scant amount of eosinophilic cytoplasm, medium sized round central nucleus with granular chromatin, and single variably distinct amphophilic nucleoli. Mitotic figures are (less than 1/HPF).

**Morphological Diagnosis:**

**MPATH Diagnosis:** lymphoma [obsolete use MPATH:516 or 535] MPATH:343

**Definitive Diagnosis:**

Lymphoma

**Histopathology Comments:**

The lesion is suggestive of an early lymphoma of the mesenteric lymph node.

**stomach (MA:0000353)**

**Histopath Description:**

There are low numbers of neutrophils within the deep lamina propria

**Morphological Diagnosis:**

**Duration:** Sub-acute; **Distribution:** Multifocal; **Severity:** mild; **MPATH Diagnosis:** inflammation MPATH:212

**Definitive Diagnosis:**

Gastritis, suppurative

**Histopathology Comments:**

This lesion is most commonly associated with Helicobacter infection. Further investigation is suggested using histochemistry (Silver stain) or colony fecal PCR.

**brain (MA:0000168)**

**Histopath Description:**

There is a mild enlargement of the lateral ventricle.

**Morphological Diagnosis:**

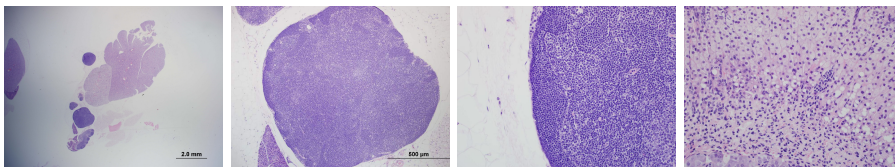
**Severity:** mild; **MPATH Diagnosis:** hydrocephalus MPATH:639

**Definitive Diagnosis:**

hydrocephalus, lateral ventricle

**Histopathology Comments:**

Variable degree of hydrocephalus is observed in a proportion of wild type C57 Black 6 mice.



Cervical lymph node, lymphoma, 1.25x, HE.

Cervical lymph node, lymphoma, 20x, HE.

Cervical lymph node, lymphoma, 40x, HE.

Adrenal gland, Vacuolar degeneration of X-zone of the adrenal gland, 40x, HE.

**Organ/Tissue Analyzed:**

There were no significant findings in the following tissues: Calvarium, brain, eyes, ears, tongue, Harderian gland, zymbal gland, salivary glands, nasal sinuses, teeth, trachea, lungs, heart, thymus, thyroid gland, parathyroid gland, spleen, gall bladder, exocrine and endocrine pancreas, esophagus, stomach, intestines, urinary organs and tract, reproductive organs, lymph nodes, spinal cord, bones, bone marrow, skeletal muscles, brown fat, and skin.

**AnimalID: M00221133 Ppp5c homo**

**Tissue Preservation and Staining:**

Thyoid gland is not present in section. There is artifactual separation of dermis and hypodermis. Tissues not present in the submission: Calvarium, ears, tongue, Harderian gland, zymbal gland, nasal sinuses, teeth,

gall bladder.

### Histopathology Findings:

#### lymph node (MA:0000139)

##### Histopath Description:

The mesenteric lymph node is enlarged more than two-fold. Its architecture is altered by large numbers of monomorphic lymphocytes that fill and distend all the sinuses and elevate the capsule. The neoplastic cells have generally a scant amount of eosinophilic cytoplasm, medium sized round central nucleus with granular chromatin, and single variably distinct amphophilic nucleoli. Mitotic figures are (less than 1/HPF).

##### Morphological Diagnosis:

**MPATH Diagnosis:** lymphoma [obsolete use MPATH:516 or 535] MPATH:343

##### Definitive Diagnosis:

Lymphoma

##### Histopathology Comments:

The lesion is suggestive of an early lymphoma of the mesenteric lymph node.

#### adrenal gland (MA:0000116)

##### Histopath Description:

Adrenal cortical cells immediately surrounding the medulla are vacuolated and contain fine granular golden brown cytoplasmic pigment. Rare mononuclear cells are present within this zone.

##### Morphological Diagnosis:

**Distribution:** Diffuse; **Severity:** no lesions; **MPATH Diagnosis:** degenerative change MPATH:14

##### Definitive Diagnosis:

Vacuolar degeneration of X-zone of the adrenal gland with cytoplasmic ceroid accumulation (X-zone involution).

##### Histopathology Comments:

The X zone of the adrenal cortex disappears when males reach sexual maturity and females undergo their first pregnancy. The zone also disappears in virgin females, albeit gradually (Percy and Barthold, 2007).

#### liver (MA:0000358)

##### Histopath Description:

The overall hepatic lobular architecture is normal. Diffusely, hepatocytes contain intracytoplasmic clear vacuoles (lipid). The lipid vacuoles within the midzonal and periportal regions are small (2-3 um in diameter) and surround a central nucleus (interpreted as microvesicular lipid). The lipid vacuoles within the portal areas are large (8-12 um in diameter) and displace the nucleus to the margin (macrovesicular lipid). There are rare perivascular mononuclear inflammatory cells.

##### Morphological Diagnosis:

**Distribution:** Diffuse; **Severity:** moderate; **MPATH Diagnosis:** lipid deposition MPATH:42

##### Definitive Diagnosis:

Hepatic lipidosis

##### Histopathology Comments:

Hepatocellular vacuolar change of variable degree suggestive of lipidosis is present in all mice from WTSI, consistent with high lipid diet.

#### brain (MA:0000168)

##### Histopath Description:

There is a mild enlargement of the lateral ventricle.

##### Morphological Diagnosis:

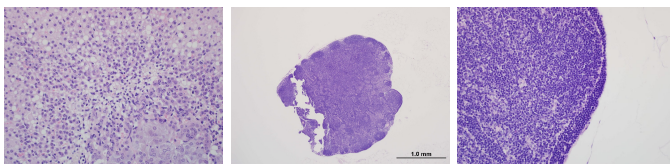
**Severity:** mild; **MPATH Diagnosis:** hydrocephalus MPATH:639

##### Definitive Diagnosis:

hydrocephalus, lateral ventricle

##### Histopathology Comments:

Variable degree of hydrocephalus is observed in a proportion of wild type C57 Black 6 mice.



Adrenal gland,

Mesenteric lymph

Mesenteric lymph

Vacuolar degeneration of X-zone of the adrenal gland, 40x, HE.	node, lymphoma, 4x, HE.	node, lymphoma, 40x, HE.
--	-------------------------	--------------------------

### Organ/Tissue Analyzed:

There were no significant findings in the following tissues: Calvarium, brain, eyes, ears, tongue, Harderian gland, zymbal gland, salivary glands, nasal sinuses, teeth, trachea, lungs, heart, thymus, thyroid gland, parathyroid gland, spleen, gall bladder, exocrine and endocrine pancreas, esophagus, stomach, intestines, urinary organs and tract, reproductive organs, spinal cord, bones, bone marrow, skeletal muscles, brown fat, and skin.

**AnimalID: M00221124 Ppp5c homo**

### Tissue Preservation and Staining:

There is artifactual separation of dermis and hypodermis. Tissues not present in submission: Calvarium, ears, tongue, Harderian gland, zymbal gland, nasal sinuses, teeth, gall bladder.

### Histopathology Findings:

#### liver (MA:0000358)

##### Histopath Description:

The overall hepatic lobular architecture is normal. Diffusely, hepatocytes contain intracytoplasmic clear vacuoles (lipid). The lipid vacuoles within the midzonal and periportal regions are small (2-3 um in diameter) and surround a central nucleus (interpreted as microvesicular lipid). The lipid vacuoles within the portal areas are large (8-12 um in diameter) and displace the nucleus to the margin (macrovesicular lipid). There are rare perivascular mononuclear inflammatory cells.

##### Morphological Diagnosis:

**Distribution:** Diffuse; **Severity:** moderate; **MPATH Diagnosis:** lipid deposition MPATH:42

##### Definitive Diagnosis:

Hepatic lipidosis

##### Histopathology Comments:

Hepatocellular vacuolar change of variable degree suggestive of lipidosis is present in all mice from WTSI, consistent with high lipid diet.

#### testis (MA:0000411)

##### Histopath Description:

Within the seminiferous tubule are present occasional large (100 um diameter) multinucleated cells. Nuclei are mostly located in the center surrounded by granular eosinophilic cytoplasm.

##### Morphological Diagnosis:

**Distribution:** Multifocal; **Severity:** no lesions;

##### Definitive Diagnosis:

Multinucleated cells within the seminiferous tubule

##### Histopathology Comments:

see comment in other lines.

#### salivary gland (MA:0000346)

##### Histopath Description:

There is a focal interstitial aggregate of histiocytes and lymphocytes.

##### Morphological Diagnosis:

**Duration:** Chronic; **Distribution:** Focal; **Severity:** mild; **MPATH Diagnosis:** inflammation MPATH:212

##### Definitive Diagnosis:

Interstitial histiocytic and lymphocytic sialadenitis

##### Histopathology Comments:

This is a common and insignificant incidental finding in mice.

#### mesenteric lymph node (MA:0002829)

##### Histopath Description:

The lymph node is enlarged (nearly 2.5x normal). There is a diffuse and marked increase in the paracortical and medullary areas and cellularity; these cells are organized as prominent chords, and they are larger and blast-like. Lymphoid follicles are increased in size and some have germinal centers.

##### Morphological Diagnosis:

**Distribution:** Diffuse; **Severity:** mild; **MPATH Diagnosis:** hyperplasia MPATH:134

##### Definitive Diagnosis:

Lymphoid hyperplasia



node, hyperplasia,  
note a prominent  
paracortical cord,  
40x, HE.

node, hyperplasia,  
4x, HE.

### Organ/Tissue Analyzed:

There were no significant findings in the following tissues: Calvarium, brain, eyes, ears, tongue, Harderian gland, zymbal gland, salivary glands, nasal sinuses, teeth, trachea, lungs, heart, thymus, thyroid gland, parathyroid gland, spleen, liver, gall bladder, exocrine and endocrine pancreas, esophagus, stomach, intestines, urinary organs and tract, adrenal gland, reproductive organs, lymph nodes, spinal cord, bones, bone marrow, skeletal muscles, brown fat, and skin.

### Summary:

Hyperplastic and early neoplastic changes are present within the mesenteric lymph nodes in this line. It should be noted that mesenteric lymph nodes can be dramatically variable within an animal and between animals due to the constant exposure of various antigenic substances in the intestinal lumen. For this reason, comparison of nodes between the mutant lines and a cohort wild type control is required to identify genotype effect. Note the following wild type mice have early lymphoma of at least a single lymph node, mainly those of the mesenteric and pancreatic lymph nodes (M00438199 Psmb2 WT; M00451965 Trrap WT; M00387957 Btbd12 WT; M00558161 Gap43 WT; and M00405977 Snip1 WT).

Hyperplastic and early neoplastic changes are present within lymph nodes in this line. Multinucleated cells within the seminiferous tubule are noted in nearly all WTSI lines; these cells are likely of spermatid origin.

### Report Summary and Recommendation:

Hyperplastic and early neoplastic changes are present within the mesenteric lymph nodes in this line. This finding may explain the increased T cell numbers observed in-life. It should be noted that mesenteric lymph nodes can be dramatically variable within an animal and between animals due to the constant exposure of various antigenic substances in the intestinal lumen. For this reason, comparison of nodes between the mutant lines and a cohort wild type control is required to identify genotype effect. Note the following wild type mice have early lymphoma of at least a single lymph node, mainly those of the mesenteric and pancreatic lymph nodes (M00438199 Psmb2 WT; M00451965 Trrap WT; M00387957 Btbd12 WT; M00558161 Gap43 WT; and M00405977 Snip1 WT).

There are no histological findings to explain decreased respiratory quotient. The skeletal abnormalities observed in-life could not be confirmed by histology from the submitted samples.

Lymph node: precursor b cell neoplasms MPATH:517