



# CMHD Pathology Report



## CMHD Pathology Core

Toronto Centre for  
Phenogenomics  
25 Orde St. 3rd fl.  
Toronto, Ont. M5T 3H7  
Tel.(416) 586-8375  
Fax (416) 586-5993

contact: Dr. Susan  
Newbigging  
email:  
[newbigging@lunenfeld.ca](mailto:newbigging@lunenfeld.ca)

## Principle Investigator: Dr. Jacqui White

Institute: Wellcome Trust Sanger Institute  
Address: Attn: Linda Read Wellcome Trust  
Genome Campus Hinxton Cambridge CB10  
1SA, UK

ReportID: Report Date: April 12, 2013  
Pathologist: H. Adissu

## Mouse Genetics Project

Wellcome Trust Sanger  
Institute  
Wellcome Trust Genome  
Campus  
Hinxton, Cambridge  
CB10 1SA  
UK

email:  
[MGPenquiries@sanger.ac.uk](mailto:MGPenquiries@sanger.ac.uk)  
[Mouse Portal](#)  
[Europhenome](#)

CMHD LabID: n13-237

## Relevant History:

kyphosis  
scoliosis  
abnormal spine curvature

## AnimalID: M00197282 (Female)

### Histopathology Findings:

#### liver (MA:0000358)

##### Histopath Description:

Moderate lipidosis

##### Morphological Diagnosis:

**Distribution:** multifocal; **Severity:** moderate;

##### Definitive Diagnosis:

Hepatic lipidosis

##### Histopathology Comments:

Hepatic lipidosis is due to high-fat diet.

#### salivary gland (MA:0000346)

##### Histopath Description:

There is a focal well-demarcated aggregate of macrophages and neutrophils within the interstitium.

##### Morphological Diagnosis:

**Duration:** chronic-active; **Distribution:** focal; **Severity:** mild;

##### Definitive Diagnosis:

Monocytic and neutrophilic cell infiltrate

20x

40x

#### brain (MA:0000168)

##### Histopath Description:

The third and lateral ventricles are notably dilated.

##### Morphological Diagnosis:

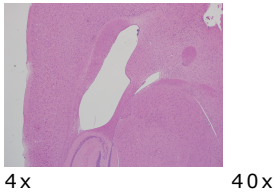
**Distribution:** generalized; **Severity:** mild;

##### Definitive Diagnosis:

Hydrocephalus

##### Histopathology Comments:

C57BL/6 mice have larger cerebral ventricles than other strains.



### thymus (MA:0000142)

#### Histopath Description:

There is a 150 um diameter epithelial cyst.

#### Morphological Diagnosis:

**Distribution:** focal; **MPATH Diagnosis:** cyst MPATH:62

#### Definitive Diagnosis:

Epithelial cyst

#### Histopathology Comments:

This is a developmental abnormality commonly seen in mice.

### cervical lymph node (MA:0000736)

#### Histopath Description:

The lymph node architecture is altered by the presence of large numbers lymphocytes filling and distending all the sinuses and elevating the capsule. The neoplastic cells have generally a scant amount of eosinophilic cytoplasm, medium sized round central nucleus with granular chromatin and single variably distinct amphophilic nucleoli. There is moderate anisocytosis and anisokaryosis. Mitosis is rare (less than 1/HPF).

#### Morphological Diagnosis:

**Severity:** moderate; **MPATH Diagnosis:** lymphoid neoplasms MPATH:513

#### Definitive Diagnosis:

Lymphoma

### Organ/Tissue Analyzed:

Brain, trigeminal ganglion, eyes, salivary glands, trachea, lungs, heart, thymus, thyroid gland, parathyroid gland, exocrine and endocrine pancreas, esophagus, stomach, small intestine, large intestine, liver, spleen, kidneys, adrenal gland, lymph nodes, spinal cord, sternum, femur and tibia with associated skeletal muscles, brown fat, pinna, skin, uterus, oviduct and ovary.

### AnimalID: M00197358 (Female)

#### Histopathology Findings:

##### liver (MA:0000358)

#### Histopath Description:

Diffuse lipidosis

#### Morphological Diagnosis:

**Distribution:** diffuse; **Severity:** severe; **MPATH Diagnosis:** steatosis MPATH:622

#### Definitive Diagnosis:

Diffuse hepatic steatosis

##### brain (MA:0000168)

#### Histopath Description:

The third and lateral ventricles are notably dilated. The white matter seems to be enlarged whereas cerebral cortex seems normal, and the cerebellum locates caudally than normal (cerebellar coning).

#### Morphological Diagnosis:

**Distribution:** generalized; **Severity:** moderate;

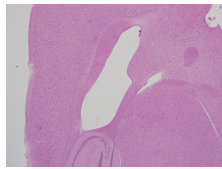
#### Definitive Diagnosis:

Hydrocephalus

#### Histopathology Comments:

C57BL/6 mice have larger cerebral ventricles than other strains, but the ventricular dilation is excessive. The lesion in brain is common spontaneous finding in C57BL/6 mice. There are basophilic neurons in parietal cerebrum, and they are artifact from handling.





1.25x

4x

40x

**Organ/Tissue Analyzed:**

Brain, trigeminal ganglion, eyes, salivary glands, trachea, lungs, heart, thymus, thyroid gland, parathyroid gland, exocrine and endocrine pancreas, esophagus, stomach, small intestine, large intestine, liver, spleen, kidneys, adrenal gland, lymph nodes, spinal cord, sternum, femur and tibia with associated skeletal muscles, brown fat, pinna, skin, uterus, oviduct and ovary.

**AnimalID: M00197254 (Male)****Histopathology Findings:****liver (MA:0000358)****Histopath Description:**

Diffuse lipidosis

**Morphological Diagnosis:**

**Distribution:** diffuse; **Severity:** severe; **MPATH Diagnosis:** steatosis MPATH:622

**Definitive Diagnosis:**

Diffuse hepatic steatosis

**brain (MA:0000168)****Histopath Description:**

The third and lateral ventricles are notably dilated. The white matter seems to be enlarged whereas cerebral cortex seems normal, and the cerebellum locates caudally than normal (cerebellar coning).

**Morphological Diagnosis:**

**Distribution:** generalized; **Severity:** moderate;

**Definitive Diagnosis:**

Hydrocephalus

**Histopathology Comments:**

C57BL/6 mice have larger cerebral ventricles than other strains.

**retina (MA:0000276)****Histopath Description:**

Involving one eye, there are clusters of external nuclear structures within the internal plexiform layer.

**Morphological Diagnosis:**

**Distribution:** Focal; **Severity:** mild;

**Definitive Diagnosis:**

Retinal dysplasia

**Organ/Tissue Analyzed:**

Brain, trigeminal ganglion, eyes, salivary glands, trachea, lungs, heart, thymus, thyroid gland, parathyroid gland, exocrine and endocrine pancreas, esophagus, stomach, small intestine, large intestine, liver, gall bladder, spleen, kidneys, adrenal gland, lymph nodes, spinal cord, sternum, femur and tibia with associated skeletal muscles, brown fat, pinna, skin, testis, epididymis, seminal vesicle, and prostate.

**AnimalID: M00197257 (Male)****Histopathology Findings:****liver (MA:0000358)****Histopath Description:**

Diffuse lipidosis

**Morphological Diagnosis:**

**Distribution:** diffuse; **Severity:** severe; **MPATH Diagnosis:** steatosis MPATH:622

**Definitive Diagnosis:**

Diffuse hepatic steatosis

**stomach (MA:0000353)****Histopath Description:**

There is focal infiltration of eosinophils and neutrophils between mucosal and muscularis mucosae. The inflammatory cells mildly infiltrate into the the mucosa.

**Morphological Diagnosis:**

**Duration:** chronic-active; **Distribution:** focal; **Severity:** mild;

**Definitive Diagnosis:**

eosinophilic gastritis

**lymph node (MA:0000139)****Histopath Description:**

The mesenteric lymph node is enlarged (greater than three-fold). There are multiple follicles with large germinal centers. The sinuses contain large numbers of mature lymphocytes and plasma cells

**Morphological Diagnosis:**

**Duration:** Sub-acute; **Distribution:** Diffuse; **Severity:** moderate;

**Definitive Diagnosis:**

Lymphoid hyperplasia

**Histopathology Comments:**

The changes in the mesenteric lymph node are suggestive of draining of a regional inflammatory process. However, such a process was not observed in the tissues examined.

**brain (MA:0000168)****Histopath Description:**

The third and lateral ventricles are notably dilated. The white matter seems to be enlarged whereas cerebral cortex seems normal, and the cerebellum locates caudally than normal (cerebellar coning).

**Morphological Diagnosis:**

**Distribution:** generalized; **Severity:** moderate;

**Definitive Diagnosis:**

Hydrocephalus (spontaneous finding)

**Histopathology Comments:**

C57BL/6 mice have larger cerebral ventricles than other strains, but the ventricular dilation is excessive. The lesion in brain is common spontaneous finding in C57BL/6 mice. There are basophilic neurons in parietal cerebrum, and they are artifact from handling.

**Organ/Tissue Analyzed:**

Brain, trigeminal ganglion, eyes, salivary glands, trachea, lungs, heart, thymus, thyroid gland, parathyroid gland, exocrine and endocrine pancreas, esophagus, stomach, small intestine, large intestine, liver, gall bladder, spleen, kidneys, adrenal gland, lymph nodes, spinal cord, sternum, femur and tibia with associated skeletal muscles, brown fat, pinna, skin, testis, epididymis, seminal vesicle, and prostate.

**Report Summary and Recommendation:**

Lesions in this line are considered incidental and/or attributable to strain background. The skeletal phenotypes described in this line are difficult to capture on histopathology.