



# CMHD Pathology Report



## CMHD Pathology Core

Toronto Centre for  
Phenogenomics  
25 Orde St. 3rd fl.  
Toronto, Ont. M5T 3H7  
Tel.(416) 586-8375  
Fax (416) 586-5993

contact: Dr. Susan  
Newbigging  
email:  
[newbigging@lunenfeld.ca](mailto:newbigging@lunenfeld.ca)

## Principle Investigator: Dr. Colin McKerlie ICSIG

Institute: Sick Kids  
Address:

ReportID: Report Date: November 23,  
2011  
Pathologist: H. Adissu

## Mouse Genetics Project

Wellcome Trust Sanger  
Institute  
Wellcome Trust Genome  
Campus  
Hinxton, Cambridge  
CB10 1SA  
UK

email:  
[MGPenquiries@sanger.ac.uk](mailto:MGPenquiries@sanger.ac.uk)  
[Mouse Portal](#)  
[Europhenome](#)

CMHD LabID: N11-370

## Relevant History:

(Fertility) Abnormal fertility; homozygous male infertility, abnormal behaviour, hyperactivity, increased T cells in males, abnormal lens morphology, cataract

**AnimalID: M00359927 Usp42 hom**

## Histopathology Findings:

### liver (MA:0000358)

#### Histopath Description:

There is diffuse hepatic lipidosis.

#### Morphological Diagnosis:

**Distribution:** Diffuse; **Severity:** severe; **MPATH Diagnosis:** lipid deposition MPATH:42

#### Definitive Diagnosis:

Hepatic liposis

### liver (MA:0000358)

#### Histopath Description:

There is diffuse hepatic lipidosis.

#### Morphological Diagnosis:

**Distribution:** Diffuse; **Severity:** severe; **MPATH Diagnosis:** lipid deposition MPATH:42

#### Definitive Diagnosis:

Hepatic liposis

### stomach (MA:0000353)

#### Histopath Description:

There are low numbers of neutrophils and moderate numbers of eosinophils within the lamina propria of the glandular region at the limiting ridge.

#### Morphological Diagnosis:

**Duration:** Sub-acute; **Distribution:** Multifocal; **Severity:** mild; **MPATH Diagnosis:** inflammation MPATH:212

#### Definitive Diagnosis:

Gastritis, suppurative

#### Histopathology Comments:

This lesion is most commonly associated with Helicobacter infection. Further investigation is suggested using histochemistry (Silver stain) or colony fecal PCR. The presence of eosinophils suggest allergic cause.

### stomach (MA:0000353)

#### Histopath Description:

There are low numbers of neutrophils and moderate numbers of eosinophils within the lamina propria of the glandular region at the limiting ridge.

**Morphological Diagnosis:**

**Duration:** Sub-acute; **Distribution:** Multifocal; **Severity:** mild; **MPATH Diagnosis:** inflammation MPATH:212

**Definitive Diagnosis:**

Gastritis, suppurative

**Histopathology Comments:**

This lesion is most commonly associated with Helicobacter infection. Further investigation is suggested using histochemistry (Silver stain) or colony fecal PCR. The presence of eosinophils suggest allergic cause.

**ovary (MA:0000384)****Histopath Description:**

Within the ovary is a large corporal lutea and few compressed growing follicles at the margin.

**ovary (MA:0000384)****Histopath Description:**

Within the ovary is a large corporal lutea and few compressed growing follicles at the margin.

**AnimalID: M00359924 Usp42 hom****Histopathology Findings:****liver (MA:0000358)****Histopath Description:**

There is diffuse hepatic lipidosis.

**Morphological Diagnosis:**

**Distribution:** Diffuse; **Severity:** severe; **MPATH Diagnosis:** lipid deposition MPATH:42

**Definitive Diagnosis:**

Hepatic lipiposis

**liver (MA:0000358)****Histopath Description:**

There is diffuse hepatic lipidosis.

**Morphological Diagnosis:**

**Distribution:** Diffuse; **Severity:** severe; **MPATH Diagnosis:** lipid deposition MPATH:42

**Definitive Diagnosis:**

Hepatic lipiposis

**stomach (MA:0000353)****Histopath Description:**

There are low numbers of neutrophils and moderate numbers of eosinophils within the lamina propria of the glandular region at the limiting ridge.

**Morphological Diagnosis:**

**Duration:** Sub-acute; **Distribution:** Multifocal; **Severity:** mild; **MPATH Diagnosis:** inflammation MPATH:212

**Definitive Diagnosis:**

Gastritis, suppurative

**Histopathology Comments:**

This lesion is most commonly associated with Helicobacter infection. Further investigation is suggested using histochemistry (Silver stain) or colony fecal PCR. The presence of eosinophils suggest allergic cause.

**stomach (MA:0000353)****Histopath Description:**

There are low numbers of neutrophils and moderate numbers of eosinophils within the lamina propria of the glandular region at the limiting ridge.

**Morphological Diagnosis:**

**Duration:** Sub-acute; **Distribution:** Multifocal; **Severity:** mild; **MPATH Diagnosis:**

inflammation MPATH:212

**Definitive Diagnosis:**

Gastritis, suppurative

**Histopathology Comments:**

This lesion is most commonly associated with Helicobacter infection. Further investigation is suggested using histochemistry (Silver stain) or colony fecal PCR. The presence of eosinophils suggest allergic cause.

**ovary (MA:0000384)**

**Histopath Description:**

Within the ovary is a large corpora lutea and few compressed growing follicles at the margin.

**ovary (MA:0000384)**

**Histopath Description:**

Within the ovary is a large corporal lutea and few compressed growing follicles at the margin.

**brain (MA:0000168)**

**Histopath Description:**

There is a mild enlargement of the lateral ventricle.

**Morphological Diagnosis:**

**Severity:** mild; **MPATH Diagnosis:** hydrocephalus MPATH:639

**Definitive Diagnosis:**

hydrocephalus, lateral ventricle

**Histopathology Comments:**

Variable degree of hydrocephalus is observed in a proportion of wild type C57 Black 6 mice.

**brain (MA:0000168)**

**Histopath Description:**

There is a mild enlargement of the lateral ventricle.

**Morphological Diagnosis:**

**Severity:** mild; **MPATH Diagnosis:** hydrocephalus MPATH:639

**Definitive Diagnosis:**

hydrocephalus, lateral ventricle

**Histopathology Comments:**

Variable degree of hydrocephalus is observed in a proportion of wild type C57 Black 6 mice.

---

**AnimalID: M00359916 Usp42 hom**

**Histopathology Findings:**

**liver (MA:0000358)**

**Histopath Description:**

There is diffuse hepatic lipidosis.

**Morphological Diagnosis:**

**Distribution:** Diffuse; **Severity:** severe; **MPATH Diagnosis:** lipid deposition MPATH:42

**Definitive Diagnosis:**

Hepatic lipiposis

**liver (MA:0000358)**

**Histopath Description:**

There is diffuse hepatic lipidosis.

**Morphological Diagnosis:**

**Distribution:** Diffuse; **Severity:** severe; **MPATH Diagnosis:** lipid deposition MPATH:42

**Definitive Diagnosis:**

Hepatic lipiposis

**testis (MA:0000411)****Histopath Description:**

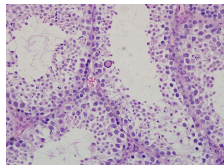
There are numerous multinucleated spermatids with pyknotic nuclei and vesicular cytoplasm. Numerous spermatids with hypereosinophilic cytoplasm and pyknotic nuclei are present (apoptosis). Spermatocytes are absent or rare within the seminiferous tubule. Occasional seroti cell vacuolation is present.

**Morphological Diagnosis:**

**Distribution:** Diffuse; **Severity:** severe; **MPATH Diagnosis:** degenerative change MPATH:14

**Definitive Diagnosis:**

Testicular degeneration and Testicular atrophy and lack of spermatogenesis.



Testis-Testicular degeneration and Testicular atrophy and lack of spermatogenesis, 40x

**testis (MA:0000411)****Histopath Description:**

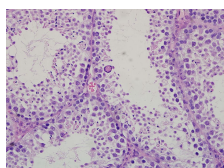
There are numerous multinucleated spermatids with pyknotic nuclei and vesicular cytoplasm. Numerous spermatids with hypereosinophilic cytoplasm and pyknotic nuclei are present (apoptosis). Spermatocytes are absent or rare within the seminiferous tubule. Occasional seroti cell vacuolation is present.

**Morphological Diagnosis:**

**Distribution:** Diffuse; **Severity:** severe; **MPATH Diagnosis:** degenerative change MPATH:14

**Definitive Diagnosis:**

Testicular degeneration and Testicular atrophy and lack of spermatogenesis.



Testis-Testicular degeneration and Testicular atrophy and lack of spermatogenesis, 40x

**epididymal duct (MA:0001735)****Histopath Description:**

Scattered cell debris are present within the tail of epididymis; spermatocytes are not present.

**Morphological Diagnosis:**

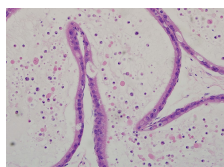
**Distribution:** Diffuse; **Severity:** severe; **MPATH Diagnosis:** hypoplasia MPATH:133

**Definitive Diagnosis:**

Epididymal aspermia

**Histopathology Comments:**

The absence of spermatocytes is consistent with the observed seminiferous atrophy.



Epididymal duct- Epididymal aspermia, 40x

**epididymal duct (MA:0001735)****Histopath Description:**

Scattered cell debris are present within the tail of epididymis; spermatocytes are not present.

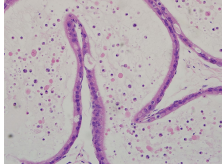


**Morphological Diagnosis:****Distribution:** Diffuse; **Severity:** severe; **MPATH Diagnosis:** hypoplasia MPATH:133**Definitive Diagnosis:**

Epididymal aspermia

**Histopathology Comments:**

The absence of spermatocytes is consistent with the observed seminiferous atrophy.



Epididymal duct-  
Epididymal  
aspermia, 40x

**stomach (MA:0000353)****Histopath Description:**

There are low numbers of neutrophils and moderate numbers of eosinophils within the lamina propria of the glandular region at the limiting ridge.

**Morphological Diagnosis:****Duration:** Sub-acute; **Distribution:** Multifocal; **Severity:** mild; **MPATH Diagnosis:** inflammation MPATH:212**Definitive Diagnosis:**

Gastritis, suppurative

**Histopathology Comments:**

This lesion is most commonly associated with Helicobacter infection. Further investigation is suggested using histochemistry (Silver stain) or colony fecal PCR. The presence of eosinophils suggest allergic cause.

**stomach (MA:0000353)****Histopath Description:**

There are low numbers of neutrophils and moderate numbers of eosinophils within the lamina propria of the glandular region at the limiting ridge.

**Morphological Diagnosis:****Duration:** Sub-acute; **Distribution:** Multifocal; **Severity:** mild; **MPATH Diagnosis:** inflammation MPATH:212**Definitive Diagnosis:**

Gastritis, suppurative

**Histopathology Comments:**

This lesion is most commonly associated with Helicobacter infection. Further investigation is suggested using histochemistry (Silver stain) or colony fecal PCR. The presence of eosinophils suggest allergic cause.

**AnimalID: M00358301 Usp42 hom****Tissue Preservation and Staining:**

There is artefactual separation of the dermis from the hypodermis

**Histopathology Findings:****pancreas (MA:0000120)****Histopath Description:**

There is focally extensive 200x 150 um necrosis admixed with large numbers of neutrophils within the pancreas parenchyma (appears to center on an islet).

**Morphological Diagnosis:****Duration:** Acute; **Distribution:** Focal; **Severity:** mild; **MPATH Diagnosis:** inflammation MPATH:212**Definitive Diagnosis:**

Necrosuppurative pancreatitis, focal

**liver (MA:0000358)****Histopath Description:**

There is diffuse hepatic lipidosis.

**Morphological Diagnosis:**

**Distribution:** Diffuse; **Severity:** severe; **MPATH Diagnosis:** lipid deposition MPATH:42

**Definitive Diagnosis:**

Hepatic liposis

**testis (MA:0000411)**

**Histopath Description:**

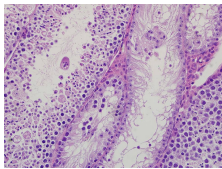
There are numerous multinucleated spermatids with pyknotic nuclei and vesicular cytoplasm. Numerous spermatids with hypereosinophilic cytoplasm and pyknotic nuclei are present (apoptosis). Spermatocytes are absent or rare within the seminiferous tubule. Occasional Sertoli cell vacuolation is present.

**Morphological Diagnosis:**

**Distribution:** Diffuse; **Severity:** severe; **MPATH Diagnosis:** degenerative change MPATH:14

**Definitive Diagnosis:**

Testicular degeneration and Testicular atrophy and lack of spermatogenesis.



Testis-Testicular degeneration and Testicular atrophy and lack of spermatogenesis. 40x

**testis (MA:0000411)**

**Histopath Description:**

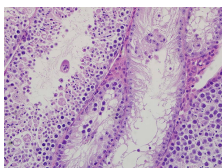
There are numerous multinucleated spermatids with pyknotic nuclei and vesicular cytoplasm. Numerous spermatids with hypereosinophilic cytoplasm and pyknotic nuclei are present (apoptosis). Spermatocytes are absent or rare within the seminiferous tubule. Occasional Sertoli cell vacuolation is present.

**Morphological Diagnosis:**

**Distribution:** Diffuse; **Severity:** severe; **MPATH Diagnosis:** degenerative change MPATH:14

**Definitive Diagnosis:**

Testicular degeneration and Testicular atrophy and lack of spermatogenesis.



Testis-Testicular degeneration and Testicular atrophy and lack of spermatogenesis. 40x

**epididymal duct (MA:0001735)**

**Histopath Description:**

Scattered cell debris are present within the tail of epididymis; spermatocytes are not present.

**Morphological Diagnosis:**

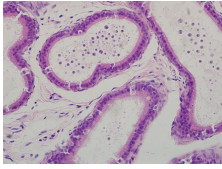
**Distribution:** Diffuse; **Severity:** severe; **MPATH Diagnosis:** hypoplasia MPATH:133

**Definitive Diagnosis:**

Epididymal aspermia

**Histopathology Comments:**

The absence of spermatocytes is consistent with the observed seminiferous atrophy.



Epididymal duct-  
Epididymal  
aspermia, 40x

#### epididymal duct (MA:0001735)

##### Histopath Description:

Scattered cell debris are present within the tail of epididymis; spermatocytes are not present.

##### Morphological Diagnosis:

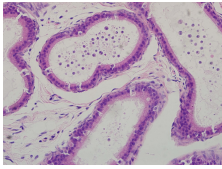
**Distribution:** Diffuse; **Severity:** severe; **MPATH Diagnosis:** hypoplasia MPATH:133

##### Definitive Diagnosis:

Epididymal aspermia

##### Histopathology Comments:

The absence of spermatocytes is consistent with the observed seminiferous atrophy.



Epididymal duct-  
Epididymal  
aspermia, 40x

#### eye (MA:0000261)

##### Histopath Description:


The iris is focally hyperplastic and adhered to the cornea

##### Morphological Diagnosis:


**Distribution:** focally extensive; **Severity:** moderate; **MPATH Diagnosis:** hyperplasia MPATH:134

##### Definitive Diagnosis:

Iridial hyperplasia and anterior synechia



Iris, eye 1, normal  
iris, 10x



Iris, eye 2, iris  
hyperplasia and  
anterior synechia,  
10x

#### Report Summary and Recommendation:

Testicular degeneration and epididymal hypospermia is present in this line, consistent with abnormal fertility/fecundity observed during in-life phenotype.

Testis: Degenerative change : MPATH:14