



# CMHD Pathology Report



## CMHD Pathology Core

Toronto Centre for  
Phenogenomics  
25 Orde St. 3rd fl.  
Toronto, Ont. M5T 3H7  
Tel.(416) 586-8375  
Fax (416) 586-5993

contact: Dr. Susan  
Newbigging  
email:  
[newbigging@lunenfeld.ca](mailto:newbigging@lunenfeld.ca)

## Principle Investigator: Dr. Jacqui White

Institute: Wellcome Trust Sanger Institute  
Address: Attn: Linda Read Wellcome Trust  
Genome Campus Hinxton Cambridge CB10  
1SA, UK

ReportID: Report Date: August 22, 2013  
Pathologist: Dr. H. Adissu

## Mouse Genetics Project

Wellcome Trust Sanger  
Institute  
Wellcome Trust Genome  
Campus  
Hinxton, Cambridge  
CB10 1SA  
UK

email:  
[MGPenquiries@sanger.ac.uk](mailto:MGPenquiries@sanger.ac.uk)  
[Mouse Portal](#)  
[Europhenome](#)

CMHD LabID: N13-492

## Relevant History:

Phenotypes:

hypoferremia  
mydriasis  
impaired pupillary reflex  
abnormal placement of pupils  
abnormal iris morphology  
eyelids fail to open  
corneal opacity  
abnormal cornea morphology  
decreased body length  
decreased mean corpuscular volume  
decreased mean corpuscular hemoglobin  
vertebral fusion  
scoliosis  
abnormal spine curvature  
partial lethality  
eye development abnormalities  
fetal edema  
partial lethality  
abnormal cornea morphology  
abnormal vitreous body

## AnimalID: M00633323 (Male)

### Histopathology Findings:

#### testis (MA:0000411)

#### Histopath Description:

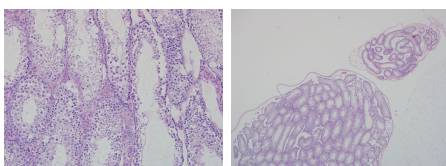
The seminiferous tubule is multifocally vacuolated. Spermatozoa are absent in the lumen and there is no evidence of differentiation of spermatids to spermatozoa. There are numerous apoptotic spermatids and occasional multinucleated spermatids. The epididymis is devoid of spermatozoa and contains cytoplasmic and nuclear debris.

#### Morphological Diagnosis:

**Distribution:** diffuse; **Severity:** extreme;

#### Definitive Diagnosis:

Testicular degeneration and atrophy with absence of spermiogenesis; epididymal aspermia



Testis, testicular  
degeneration and  
atrophy with  
absence of  
spermiogenesis,

Testis and  
epididymis,  
degeneration and  
atrophy and  
epididymal

20x, HE

aspermia, 4x, HE

**liver (MA:0000358)****Histopath Description:**

diffuse lipidosis

**Morphological Diagnosis:****Distribution:** diffuse; **Severity:** severe; **MPATH Diagnosis:** steatosis MPATH:622**Definitive Diagnosis:**

Hepatic lipidosis

**brain (MA:0000168)****Histopath Description:**

There is mild dilation of the lateral ventricles

**Morphological Diagnosis:****Distribution:** bilateral; **Severity:** mild;**Definitive Diagnosis:**

Dilation of the brain ventricles

**Histopathology Comments:**

Mild dilation of the lateral ventricles is a background condition in mice of C57BL/6N background (Brayton et al., 2004).

**aorta (MA:0000062)****Histopath Description:**

The base of the aorta is segmentally thickened by fibroplasia and the wall is disrupted by deeply eosinophilic hyaline to fibrinoid material (fibrinoid necrosis).

**Morphological Diagnosis:****Distribution:** focally extensive; **Severity:** moderate; **MPATH Diagnosis:** vasculitis MPATH:201**Definitive Diagnosis:**

Aortitis, proliferative and necrotizing

**Histopathology Comments:**

Inflammatory lesions of small and medium-sized arteries are common in many strains of laboratory mice. The distribution of affected vessels is quite variable and could involve arteries of the heart among others. Lesions may involve multiple vessels, hence termed "polyarteritis." The etiology of polyarteritis is not known, but thought to be immune complex-mediated. It is common in mice that are prone to autoimmune disease, including MRL and NZB mice. Polyarteritis is usually an incidental finding (Percy and Barthold. 2007).

**Organ/Tissue Analyzed:**

Histopathology examination included the following organs and tissues: brain, trigeminal ganglion, eyes, salivary glands, trachea, lungs, heart, thymus, thyroid gland, parathyroid gland, exocrine and endocrine pancreas, oesophagus, stomach, small intestine, large intestine, liver, gall bladder, spleen, kidneys, adrenal gland, lymph nodes, spinal cord, bone marrow, sternum, femur and tibia with associated skeletal muscles, brown fat, pinna, skin, testis, epididymis, seminal vesicle, and prostate.

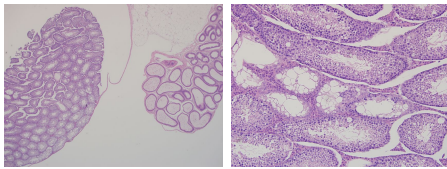
---

**AnimalID: M00589354 (Male)****Histopathology Findings:****testis (MA:0000411)****Histopath Description:**

The seminiferous tubule is multifocally vacuolated. Spermatozoa are minimal to absent in the lumen and there is minimal differentiation of spermatids to spermatozoa. There are numerous apoptotic spermatids and occasional multinucleated spermatids. The epididymis is devoid of spermatozoa and contains cytoplasmic and nuclear debris.

**Morphological Diagnosis:****Distribution:** diffuse; **Severity:** extreme;**Definitive Diagnosis:**

Testicular degeneration and atrophy with absence of spermiogenesis; epididymal aspermia



Testis and epididymis, degeneration and atrophy and epididymal aspermia, 4x, HE

Testis, testicular degeneration and atrophy with absence of spermiogenesis, 20x, HE

### liver (MA:0000358)

#### Histopath Description:

diffuse lipidosis

#### Morphological Diagnosis:

**Distribution:** diffuse; **Severity:** severe; **MPATH Diagnosis:** steatosis MPATH:622

#### Definitive Diagnosis:

Hepatic lipidosis

### eye (MA:0000261)

#### Histopath Description:

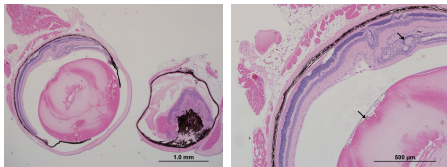
The posterior retina is dysplastic with extensive multifocal retinal folding and rosette formation. There is mild cataractous change at the posterior margin of the lens

#### Morphological Diagnosis:

**Distribution:** multifocal to coalescing; **Severity:** severe;

#### Definitive Diagnosis:

Retinal dysplasia; cataract



Two eyes, microphthalmia (right); retinal dysplasia (left), 4x, HE

Marked retinal dysplasia with rosette formation; mild posterior cataract, 10x, HE

### eye (MA:0000261)

#### Histopath Description:

The other eye is small (nearly half the normal size). The retina is thrown into folds and disorganized mass and is adhered to a small piece of lens material (containing degenerate lens proteins or Morgagnian globules). Other ocular structures including the anterior uvea are disorganized.

#### Morphological Diagnosis:

**Distribution:** diffuse; **Severity:** extreme;

#### Definitive Diagnosis:

Microphthalmia

### brain (MA:0000168)

#### Histopath Description:

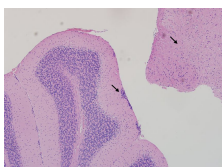
There are three foci of aggregates of granular cells in the within the outer aspect of the molecular layer.

#### Morphological Diagnosis:

**Distribution:** multifocal; **Severity:** mild;

#### Definitive Diagnosis:

Cerebellar granular cell heterotopia



Brain, cerebellum,

heterotopic granular  
cells, 10x, HE

### Organ/Tissue Analyzed:

Histopathology examination included the following organs and tissues: brain, trigeminal ganglion, eyes, salivary glands, trachea, lungs, heart, thymus, thyroid gland, parathyroid gland, exocrine and endocrine pancreas, oesophagus, stomach, small intestine, large intestine, liver, gall bladder, spleen, kidneys, adrenal gland, lymph nodes, spinal cord, bone marrow, sternum, femur and tibia with associated skeletal muscles, brown fat, pinna, skin, testis, epididymis, seminal vesicle, and prostate.

### AnimalID: M00547941 (Male)

### Histopathology Findings:

#### testis (MA:0000411)

##### Histopath Description:

Normal

##### Morphological Diagnosis:

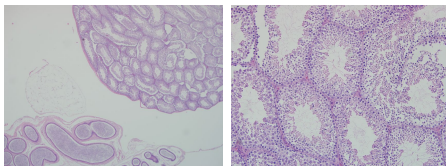
**Severity:** no lesions;

##### Definitive Diagnosis:

Normal testis

##### Histopathology Comments:

compare to the other two male mice



Testis and  
epididymis,  
normal,4x, HE

Testis, normal, 20x,  
HE

#### lymph node (MA:0000139)

##### Histopath Description:

The mesenteric lymph node is markedly enlarged (greater than four fold). The medulla is particularly expanded by chords and sheets of plasmotoid cells. There are prominent germinal centers within the medulla

##### Morphological Diagnosis:

**Distribution:** Diffuse; **Severity:** moderate; **MPATH Diagnosis:** hyperplasia MPATH:134

##### Definitive Diagnosis:

Lymphoid hyperplasia

##### Histopathology Comments:

The changes in the mesenteric lymph node are suggestive of draining of a regional inflammatory process. However, such a process was not observed in the tissues examined. Early marginal center lymphoma is suspected.

#### liver (MA:0000358)

##### Histopath Description:

diffuse lipidosis

##### Morphological Diagnosis:

**Distribution:** diffuse; **Severity:** severe; **MPATH Diagnosis:** steatosis MPATH:622

##### Definitive Diagnosis:

Hepatic lipidosis

#### retina (MA:0000276)

##### Histopath Description:

Involving one eye, there are clusters of external nuclear structures within the internal plexiform layer.

##### Morphological Diagnosis:

**Distribution:** Focal; **Severity:** mild;

##### Definitive Diagnosis:

Retinal dysplasia



**brain (MA:0000168)****Histopath Description:**

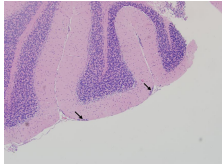
There are two small foci of aggregates of granular cells in the within the outer aspect of the molecular layer.

**Morphological Diagnosis:**

**Distribution:** multifocal; **Severity:** mild;

**Definitive Diagnosis:**

Cerebellar granular cell heterotopia



Brain, cerebellum,  
heterotopic granular  
cells, 10x, HE

**Organ/Tissue Analyzed:**

Histopathology examination included the following organs and tissues: brain, trigeminal ganglion, eyes, salivary glands, trachea, lungs, heart, thymus, thyroid gland, parathyroid gland, exocrine and endocrine pancreas, oesophagus, stomach, small intestine, large intestine, liver, gall bladder, spleen, kidneys, adrenal gland, lymph nodes, spinal cord, bone marrow, sternum, femur and tibia with associated skeletal muscles, brown fat, pinna, skin, testis, epididymis, seminal vesicle, and prostate.

**AnimalID: M00736694 (Female)****Histopathology Findings:****liver (MA:0000358)****Histopath Description:**

mild lipidosis

**Morphological Diagnosis:**

**Distribution:** multifocal; **Severity:** mild;

**Definitive Diagnosis:**

mild hepatic lipidosis

**lymph node (MA:0000139)****Histopath Description:**

The mesenteric lymph node is markedly enlarged (greater than four fold). The medulla is particularly expanded by chords and sheets of plasmotoid cells. There are prominent germinal centers within the medulla

**Morphological Diagnosis:**

**Distribution:** Diffuse; **Severity:** moderate; **MPATH Diagnosis:** hyperplasia MPATH:134

**Definitive Diagnosis:**

Lymphoid hyperplasia

**Histopathology Comments:**

The changes in the mesenteric lymph node are suggestive of draining of a regional inflammatory process. However, such a process was not observed in the tissues examined. Early maginal center lymphoma is suspected.

**brain (MA:0000168)****Histopath Description:**

There is mild dilation of the lateral ventricles

**Morphological Diagnosis:**

**Distribution:** bilateral; **Severity:** mild;

**Definitive Diagnosis:**

Dilation of the brain ventricles

**Histopathology Comments:**

Mild dilation of the lateral ventricles is a background condition in mice of C57BL/6N background (Brayton et al., 2004).

**Organ/Tissue Analyzed:**

Histopathology examination included the following organs and tissues: brain, trigeminal ganglion, eyes, salivary glands, trachea, lungs, heart, thymus, thyroid gland, parathyroid gland, exocrine and endocrine pancreas, oesophagus, stomach, small intestine, large intestine, liver, gall bladder, spleen, kidneys, adrenal gland, lymph nodes, spinal cord, bone marrow, sternum, femur and tibia with associated skeletal muscles, brown fat, pinna, skin, uterus, oviduct, and ovary, and mammary gland.

**Report Summary and Recommendation:**

Three male mice are submitted. The two homozygotes show severe seminiferous degenerative and atrophic changes with absence of spermatogenesis. This is unexpected phenotype in absence of reported infertility in this line. The heterozygous male mice has no testicular lesion.

Two mice have cerebellar granule cell heterotopia. The lesions are mild and their functional effect (if any) is doubtful. Aberrant granule cells in the cerebellar molecular layer are rare in C57BL/6J mice. They have been described in 'nervous' (nr/nr) mutant mice of the Balb/cGr strain. Similar heterotopic cells are also present in normal mice of the Balb/cGr and C3Heb/FeJ strains, although to a much lesser degree (Landis, 1973).

One of the homozygous mouse has severe ocular abnormalities (unilateral microphthalmia and marked retinal dysplasia with cataractous lenticular changes in the contralateral eye). Lesion may explain the ocular abnormalities in this line.

Aortic vasculitis is seen in one of the homozygotes - in view of fetal edema and partial lethality, this lesion may signify vascular abnormality in homozygotes. Note that this lesion may rarely be seen in WTcontrols.

**Line summary**

1. Testicular degeneration and atrophy with epididymal aspermia (2/3 male mice)
2. Cerebellar granular cell heterotopia (2/4)
3. Microphthalmia (1/4); Retinal dysplasia (2/4); Cataract (2/4)
4. Aortic vasculitis (1/4)

Other lesions are attributable to diet or strain background.

**References:**

S.C. Landis, Granule cell heterotopia in normal and nervous mutant mice of the BALB/c strain, Brain Research, Volume 61, 26 October 1973, Pages 175-189