



CMHD Pathology Report



CMHD Pathology Core

Toronto Centre for
Phenogenomics
25 Orde St. 3rd fl.
Toronto, Ont. M5T 3H7
Tel.(416) 586-8375
Fax (416) 586-5993

contact: Dr. Susan
Newbigging
email:
newbigging@lunenfeld.ca

Principle Investigator: Dr. Jacqui White

Institute: Wellcome Trust Sanger Institute
Address: Attn: Linda Read Wellcome Trust
Genome Campus Hinxton Cambridge CB10
1SA, UK

ReportID: Report Date: February 21,
2014
Pathologist: Dr. H. Adissu

Mouse Genetics Project

Wellcome Trust Sanger
Institute
Wellcome Trust Genome
Campus
Hinxton, Cambridge
CB10 1SA
UK

email:
MGPenquiries@sanger.ac.uk
[Mouse Portal](#)
[Europhenome](#)

CMHD LabID: N13-927

Relevant History:

Phenotypes:
scoliosis
abnormal spine curvature
increased susceptibility to bacterial infection

AnimalID: M00338688 (Male)

Histopathology Findings:

sternum (MA:0001331)

Histopath Description:

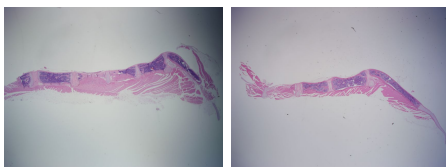
Normal

Definitive Diagnosis:

Normal sternum

Histopathology Comments:

Included for comparison



Sternum, normal,
1.25x, HE.

Sternum, WT,
normal, 1.25x, HE.

eye (MA:0000261)

Histopath Description:

Involving one eye, there are clusters of external nuclear structures within the internal plexiform layer.

Morphological Diagnosis:

Distribution: multifocal; **Severity:** mild; **MPATH Process Term:** developmental dysplasia
MPATH:64

Definitive Diagnosis:

Retinal dysplasia

liver (MA:0000358)

Histopath Description:

diffuse lipidosis

Morphological Diagnosis:

Distribution: diffuse; **Severity:** extreme; **MPATH Diagnosis:** steatosis MPATH:622; **MPATH Process Term:** lipid deposition MPATH:42

Definitive Diagnosis:

Hepatic lipidosis

Histopathology Comments:

This is dietary steatosis

Organ/Tissue Analyzed:

Histopathology examination included the following organs and tissues: brain, trigeminal ganglion, eyes, salivary glands, trachea, lungs, heart, thymus, thyroid gland, parathyroid gland, exocrine and endocrine pancreas, oesophagus, stomach, small intestine, large intestine, liver, gall bladder, spleen, kidneys, adrenal gland, lymph nodes, spinal cord, bone marrow, sternum, femur and tibia with associated skeletal muscles, brown fat, pinna, skin, testis, epididymis, seminal vesicle, and prostate.

AnimalID: M00338718 (Male)

Histopathology Findings:

sternum (MA:0001331)

Histopath Description:

The sternum is moderately curved outwardly

Morphological Diagnosis:

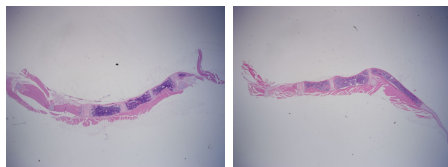
Severity: moderate; **MPATH Process Term:** developmental and structural abnormality
MPATH:55

Definitive Diagnosis:

Curved sternum

Histopathology Comments:

This lesion is suggestive of pectus carinatum (outward protrusion of the sternum)



Sternum, outward curving (protrusion), 1.25x, HE. Sternum, WT, normal, 1.25x, HE.

liver (MA:0000358)

Histopath Description:

diffuse lipidosi

Morphological Diagnosis:

Distribution: diffuse; **Severity:** extreme; **MPATH Diagnosis:** steatosis MPATH:622; **MPATH Process Term:** lipid deposition MPATH:42

Definitive Diagnosis:

Hepatic lipidosi

Histopathology Comments:

This is dietary steatosis

brain (MA:0000168)

Histopath Description:

There is marked dilation of the lateral ventricles

Morphological Diagnosis:

Distribution: diffuse; **Severity:** severe; **MPATH Diagnosis:** hydrocephalus MPATH:639; **MPATH Process Term:** degenerative change MPATH:14

Definitive Diagnosis:

Dilation of the brain ventricles

Histopathology Comments:

Mild to moderate dilation of the ventricles is a background condition in mice of C57BL/6N background

Organ/Tissue Analyzed:

Histopathology examination included the following organs and tissues: brain, trigeminal ganglion, eyes, salivary glands, trachea, lungs, heart, thymus, thyroid gland, parathyroid gland, exocrine and endocrine pancreas, oesophagus, stomach, small intestine, large intestine, liver, gall bladder, spleen, kidneys, adrenal gland, lymph nodes, spinal cord, bone marrow, sternum, femur and tibia with associated skeletal muscles, brown fat, pinna, skin, testis, epididymis, seminal vesicle, and prostate.

AnimalID: M00427392 (Female)**Histopathology Findings:****sternum (MA:0001331)****Histopath Description:**

The sternum is moderately curved outwardly

Morphological Diagnosis:

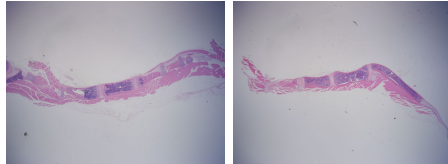
Severity: moderate; **MPATH Process Term:** developmental and structural abnormality
MPATH:55

Definitive Diagnosis:

Curved sternum

Histopathology Comments:

This lesion is suggestive of pectus carinatum (outward protrusion of the sternum)



Sternum, outward curving (protrusion), 1.25x, HE. Sternum, WT, normal, 1.25x, HE.

liver (MA:0000358)**Histopath Description:**

diffuse lipidosis

Morphological Diagnosis:

Distribution: diffuse; **Severity:** extreme; **MPATH Diagnosis:** steatosis MPATH:622; **MPATH Process Term:** lipid deposition MPATH:42

Definitive Diagnosis:

Hepatic lipidosis

Histopathology Comments:

This is dietary steatosis

brain (MA:0000168)**Histopath Description:**

There is marked dilation of the lateral ventricles

Morphological Diagnosis:

Distribution: diffuse; **Severity:** severe; **MPATH Diagnosis:** hydrocephalus MPATH:639;
MPATH Process Term: degenerative change MPATH:14

Definitive Diagnosis:

Dilation of the brain ventricles

Histopathology Comments:

Mild to moderate dilation of the ventricles is a background condition in mice of C57BL/6N background

stomach (MA:0000353)**Histopath Description:**

mild neutrophilic gastritis.

Morphological Diagnosis:

Distribution: multifocal; **Severity:** mild; **MPATH Process Term:** inflammation MPATH:212

Definitive Diagnosis:

Mild neutrophilic gastritis

Organ/Tissue Analyzed:

Histopathology examination included the following organs and tissues: brain, trigeminal ganglion, eyes, salivary glands, trachea, lungs, heart, thymus, thyroid gland, parathyroid gland, exocrine and endocrine pancreas, oesophagus, stomach, small intestine, large intestine, liver, gall bladder, spleen, kidneys, adrenal gland, lymph nodes, spinal cord, bone marrow, sternum, femur and tibia with associated skeletal muscles, brown fat, pinna, skin, uterus, oviduct, and ovary, and mammary gland.

AnimalID: M00427393 (Female)**Histopathology Findings:**

sternum (MA:0001331)**Histopath Description:**

The sternum is moderately curved outwardly

Morphological Diagnosis:

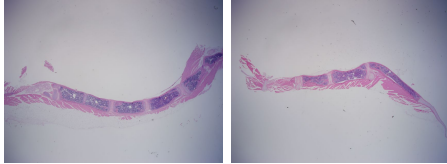
Severity: moderate; **MPATH Process Term:** developmental and structural abnormality
MPATH:55

Definitive Diagnosis:

Curved sternum

Histopathology Comments:

This lesion is suggestive of pectus carinatum (outward protrusion of the sternum)



Sternum, outward curving (protrusion), 1.25x, HE. Sternum, WT, normal, 1.25x, HE.

liver (MA:0000358)**Histopath Description:**

diffuse lipidosis

Morphological Diagnosis:

Distribution: diffuse; **Severity:** extreme; **MPATH Diagnosis:** steatosis MPATH:622; **MPATH Process Term:** lipid deposition MPATH:42

Definitive Diagnosis:

Hepatic lipidosis

Histopathology Comments:

This is dietary steatosis

eye (MA:0000261)**Histopath Description:**

Involving one eye, there are clusters of external nuclear structures within the internal plexiform layer.

Morphological Diagnosis:

Distribution: multifocal; **Severity:** mild; **MPATH Process Term:** developmental dysplasia
MPATH:64

Definitive Diagnosis:

Retinal dysplasia

Organ/Tissue Analyzed:

Histopathology examination included the following organs and tissues: brain, trigeminal ganglion, eyes, salivary glands, trachea, lungs, heart, thymus, thyroid gland, parathyroid gland, exocrine and endocrine pancreas, oesophagus, stomach, small intestine, large intestine, liver, gall bladder, spleen, kidneys, adrenal gland, lymph nodes, spinal cord, bone marrow, sternum, femur and tibia with associated skeletal muscles, brown fat, pinna, skin, uterus, oviduct, and ovary, and mammary gland.

Report Summary and Recommendation:

Outward protrusion or curving of the sternum is present in three mice. This sternal deformity is consistent with pectus carinatum. In humans, this deformity is associated with vertebral deformities such as scoliosis (as is the case in this mouse line). We did not see morphological correlate to increased susceptibility to bacterial infection.

Line summary:

Sternum: Sternal deformity (pectus carinatum) 3/4