



CMHD Pathology Report



CMHD Pathology Core

Toronto Centre for
Phenogenomics
25 Orde St. 3rd fl.
Toronto, Ont. M5T 3H7
Tel.(416) 586-8375
Fax (416) 586-5993

contact: Dr. Susan
Newbigging
email:
newbigging@lunenfeld.ca

Principle Investigator: Dr. Jacqui White

Institute: Wellcome Trust Sanger Institute
Address: Attn: Linda Read Wellcome Trust
Genome Campus Hinxton Cambridge CB10
1SA, UK

ReportID: Report Date: May 09, 2013
Pathologist: Dr. H. Adissu

Mouse Genetics Project

Wellcome Trust Sanger
Institute
Wellcome Trust Genome
Campus
Hinxton, Cambridge
CB10 1SA
UK

email:
MGPenquiries@sanger.ac.uk
[Mouse Portal](#)
[Europhenome](#)

CMHD LabID: N13-249

Relevant History:

Phenotype:

Increased NK cell number
abnormal drinking behavior
polyuria

AnimalID: M00511843 (Male)

Histopathology Findings:

liver (MA:0000358)

Histopath Description:

moderate lipidosis

Morphological Diagnosis:

Distribution: diffuse; **Severity:** severe; **MPATH Diagnosis:** steatosis MPATH:622

Definitive Diagnosis:

Hepatic lipidosis

kidney (MA:0000368)

Histopath Description:

There is focal atypical epithelial hyperplasia surrounded by thick layer of fibrosis.

Morphological Diagnosis:

Distribution: focally extensive; **Severity:** mild;

Definitive Diagnosis:

Tubular hyperplasia with peritubular fibrosis

Histopathology Comments:

This change is consistent with regenerative hyperplasia following a tubular damage. The cause is not evident in the sections examined.

brain (MA:0000168)

Histopath Description:

There is a 500 um cyst at the median eminence distal to the hypothalamus. The cyst is lined by a simple ciliated cuboidal to low columnar epithelium with occasional Goblet cells. The cyst contains eosinophilic granular material.

Morphological Diagnosis:

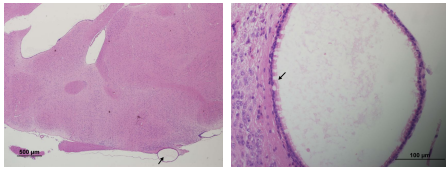
Distribution: focal; **MPATH Diagnosis:** cyst MPATH:62

Definitive Diagnosis:

Rathke's cleft cyst

Histopathology Comments:

Rathke's cysts originate from remnants of Rathke's pouch which appears during the early embryonic life as an outgrowth of stomodeum. Rathke's cleft cysts are most often small and asymptomatic. Occasionally they become large enough to cause symptoms by compression of intrasellar and suprasellar structures. The cyst in this mouse is considered small and benign.



Brain, Rathke's cyst, 40x, HE

Brain, Rathke's cyst, note ciliated epithelium with goblet cells, 40x, HE

brain (MA:0000168)

Histopath Description:

There is mild dilation of the lateral ventricles

Morphological Diagnosis:

Distribution: bilateral; **Severity:** mild;

Definitive Diagnosis:

Dilation of the brain ventricles

Histopathology Comments:

Mild dilation of the lateral ventricles is a background condition in mice of C57BL/6N background (Brayton et al., 2004).

AnimalID: M00511845 (Male)

Histopathology Findings:

liver (MA:0000358)

Histopath Description:

moderate lipidosis

Morphological Diagnosis:

Distribution: diffuse; **Severity:** severe; **MPATH Diagnosis:** steatosis MPATH:622

Definitive Diagnosis:

Hepatic lipidosis

brain (MA:0000168)

Histopath Description:

There is mild dilation of the lateral ventricles

Morphological Diagnosis:

Distribution: bilateral; **Severity:** mild;

Definitive Diagnosis:

Dilation of the brain ventricles

Histopathology Comments:

Mild dilation of the lateral ventricles is a background condition in mice of C57BL/6N background (Brayton et al., 2004).

kidney (MA:0000368)

Histopath Description:

Rare papillary tubules contain granular basophilic material that variably occludes lumina (mineral).

Morphological Diagnosis:

Distribution: multifocal; **Severity:** mild; **MPATH Diagnosis:** mineralisation MPATH:555

Definitive Diagnosis:

Renal papillary intratubular mineral deposits

Histopathology Comments:

Focal mineralization of renal papillary collecting tubules is occasionally seen in rodents.

thymus (MA:0000142)

Histopath Description:

There is a 100 um diameter epithelial cyst.

Morphological Diagnosis:

Distribution: focal; **MPATH Diagnosis:** cyst MPATH:62

Definitive Diagnosis:

Epithelial cyst

Histopathology Comments:

This is a developmental abnormality commonly seen in mice.

lymph node (MA:0000139)

Histopath Description:

The mesenteric lymph node is enlarged (greater than three-fold). There are multiple follicles with large germinal centers. The sinuses contain large numbers of mature lymphocytes.

Morphological Diagnosis:

Duration: Sub-acute; **Distribution:** Diffuse; **Severity:** moderate; **MPATH Diagnosis:** hyperplasia MPATH:134

Definitive Diagnosis:

Lymphoid hyperplasia.

Histopathology Comments:

The changes in the mesenteric lymph node are suggestive of draining of a regional inflammatory process. However, such a process was not observed in the tissues examined.

stomach (MA:0000353)

Histopath Description:

moderate neutrophilic gastritis

Morphological Diagnosis:

Distribution: multifocal to coalescing; **Severity:** moderate;

Definitive Diagnosis:

Gastritis, neutrophilic

testis (MA:0000411)

Histopath Description:

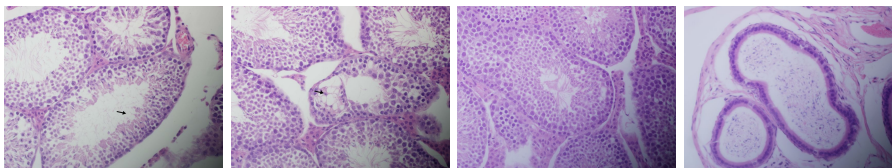
There are rare foci of vacuolar degeneration and atrophy of the seminiferous tubules. Numerous seminiferous tubules lack maturing spermatids and spermatocytes. The epididymis contains fewer spermatocytes (compare with WT control).

Morphological Diagnosis:

Distribution: multifocal; **Severity:** moderate;

Definitive Diagnosis:

Testicular degeneration and atrophy

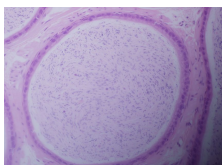


Testis, note few spermatocytes and maturing spermatids, 40x, HE

Testis, degeneration and atrophy, focal, 40x, HE

Testis, wildtype, normal, note maturing spermatids and numerous spermatocytes, 40x, HE

Epididymal duct, hypospermia, 40x, HE



Epididymal duct, wildtype, normal, note abundant spermatocytes, 40x, HE

AnimalID: M00342687 (Female)

Histopathology Findings:**liver (MA:0000358)****Histopath Description:**

moderate lipidosis

Morphological Diagnosis:

Distribution: diffuse; **Severity:** severe; **MPATH Diagnosis:** steatosis MPATH:622

Definitive Diagnosis:

Hepatic lipidosis

brain (MA:0000168)**Histopath Description:**

There is mild dilation of the lateral ventricles

Morphological Diagnosis:

Distribution: bilateral; **Severity:** mild;

Definitive Diagnosis:

Dilation of the brain ventricles

Histopathology Comments:

Mild dilation of the lateral ventricles is a background condition in mice of C57BL/6N background (Brayton et al., 2004).

AnimalID: M00342686 (Female)**Histopathology Findings:****liver (MA:0000358)****Histopath Description:**

moderate lipidosis

Morphological Diagnosis:

Distribution: diffuse; **Severity:** severe; **MPATH Diagnosis:** steatosis MPATH:622

Definitive Diagnosis:

Hepatic lipidosis

brain (MA:0000168)**Histopath Description:**

There is mild dilation of the lateral ventricles

Morphological Diagnosis:

Distribution: bilateral; **Severity:** mild;

Definitive Diagnosis:

Dilation of the brain ventricles

Histopathology Comments:

Mild dilation of the lateral ventricles is a background condition in mice of C57BL/6N background (Brayton et al., 2004).

Report Summary and Recommendation:

We did not find morphological correlates to increased number of NK cells. Routine HE histopathology is not sensitive enough to detect variations in the population of classes and/or subclasses of lymphocytes within hemolymphatic tissues. We also did not find histological correlates to the abnormal drinking behavior and polyuria observed during clinical phenotyping. The Rathke's cyst observed in one mouse is benign and do no happen to have compressive and destructive effect on overlying hypothalamic nuclei. Hence its potential effect, if any, on hypothalamic function (such as thirst regulation) is uncertain. Testicular degeneration and atrophy was noted in one male mouse. Other lesions are considered incidental and are attributable to diet or strain background.