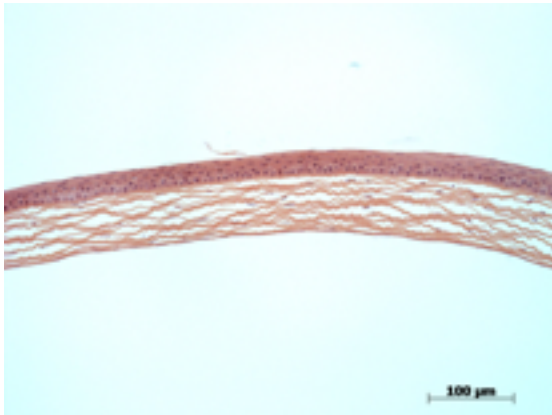


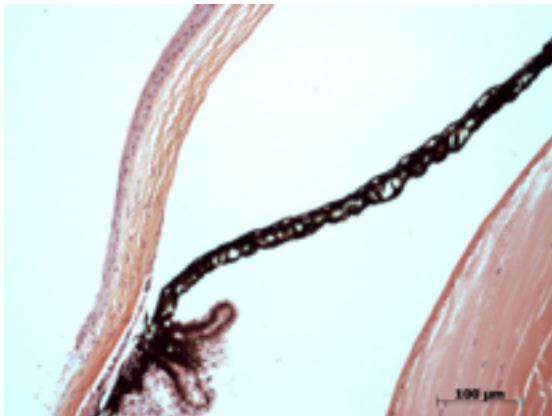
Abnormal Findings: None.

EYE Phenotype



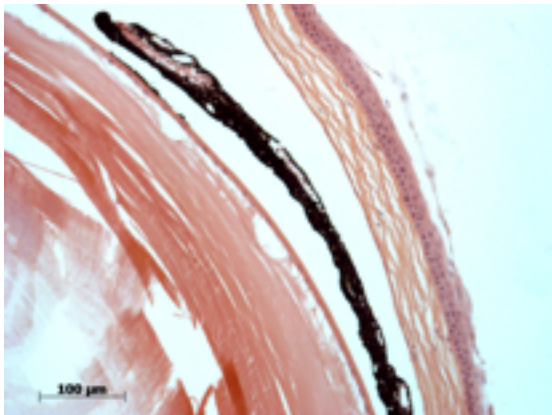
Cornea:

6/6. Normal corneal epithelium, stroma, and endothelium.



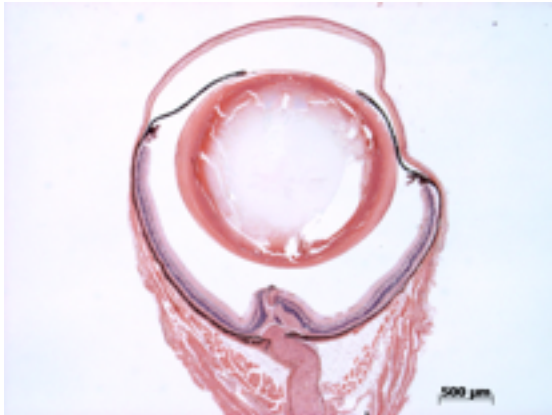
Anterior chamber:

6/6. The anterior chamber was of normal depth without cells, and the angle appeared open.



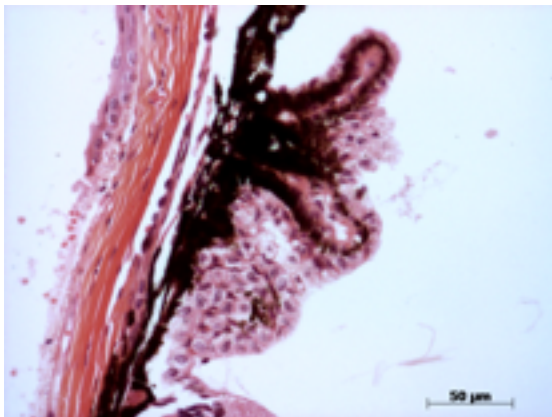
Iris:

6/6. The iris showed normal pigmentation without rubeosis or pupillary membranes.



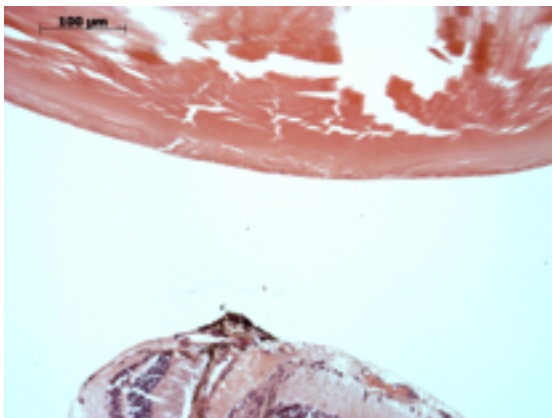
Lens:

6/6. No cataract was observed.



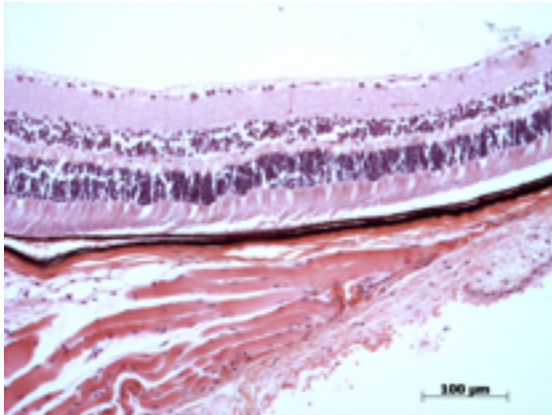
Ciliary body:

6/6. Normal stroma, pigmented and nonpigmented layers were present along with cilia.



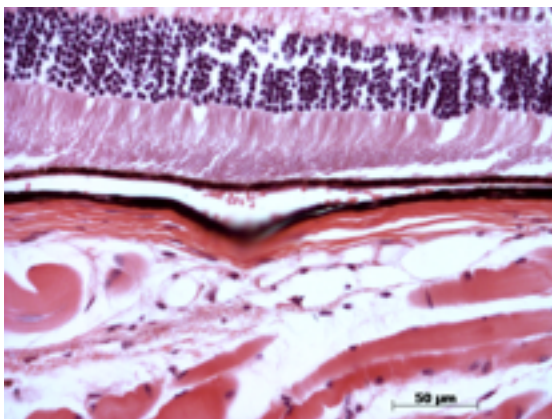
Vitreous:

6/6. No abnormal opacities or cells.



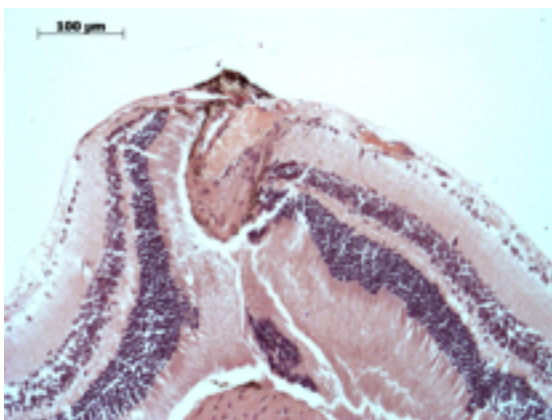
Retina:

6/6. The retinal ganglion, inner nuclear and photoreceptor layers are normal.



Retinal pigment epithelium and Choroid:

6/6. Normal pigmentation. Bruch's membrane is intact. No neovascular membranes were noted.



Optic Nerve:

6/6. The nerve is normal.

Methods. 6 eyes from 3 male mice were enucleated by blunt dissection and fixed. Pupil-optic nerve sections were processed with hematoxylin and eosin, and standard images were captured under light microscopy for review.