



CMHD Pathology Report



CMHD Pathology Core

Toronto Centre for
Phenogenomics
25 Orde St. 3rd fl.
Toronto, Ont. M5T 3H7
Tel.(416) 586-8375
Fax (416) 586-5993

contact: Dr. Susan
Newbigging
email:
newbigging@lunenfeld.ca

Principle Investigator: Dr. Jacqui White

Institute: Wellcome Trust Sanger Institute
Address: Attn: Linda Read Wellcome Trust
Genome Campus Hinxton Cambridge CB10
1SA, UK

ReportID: Report Date: February 13,
2014
Pathologist: Dr. H. Adissu

Mouse Genetics Project

Wellcome Trust Sanger
Institute
Wellcome Trust Genome
Campus
Hinxton, Cambridge
CB10 1SA
UK

email:
MGPenquiries@sanger.ac.uk
[Mouse Portal](#)
[Europhenome](#)

CMHD LabID: N13-921

Relevant History:

increased thermal nociceptive threshold
abnormal gait
abnormal fertility/fecundity
abnormal corneal stroma morphology
abnormal eye morphology
abnormal lens morphology
abnormal primary vitreous morphology
abnormal retina morphology

AnimalID: M00784987 (Male)

Histopathology Findings:

testis (MA:0000411)

Histopath Description:

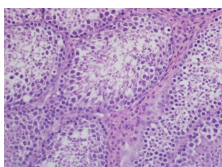
Diffusely seminiferous tubules contain few maturing spermatocytes. Necrotic spermatids are multifocally observed. The epididymis contains abundant cellular debris, but no spermatocytes. Elongated spermatids are inappropriately present within deep layers (spermatid retention).

Morphological Diagnosis:

Distribution: multifocal to coalescing; **Severity:** severe; **MPATH Process Term:** degenerative change MPATH:14

Definitive Diagnosis:

Seminiferous tubule-spermatid necrosis and decreased spermiogenesis; epididymal aspermia.



Testis, seminiferous
tubule-spermatid
necrosis and
decreased
spermiogenesis,
40x, HE epididymal
aspermia.

epididymal duct (MA:0001735)

Histopath Description:

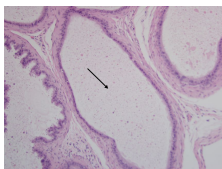
The epididymis is devoid of spermatocytes and contains abundant cellular debris and proteinaceous fluid.

Morphological Diagnosis:

Severity: extreme;

Definitive Diagnosis:

Epididymal aspermia



Epididymis,
epididymal
aspermia, 20x, HE.

brain (MA:0000168)

Histopath Description:

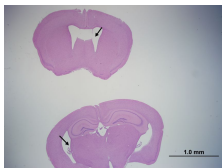
There is moderate dilation of the lateral ventricles. The periventricular neuropil is rarefied.

Morphological Diagnosis:

Duration: Chronic; **Distribution:** Bilateral; **Severity:** moderate; **MPATH Diagnosis:** hydrocephalus MPATH:639; **MPATH Process Term:** degenerative change MPATH:14

Definitive Diagnosis:

Bilateral hydrocephalus of the lateral ventricles, mild



Brain, bilateral
hydrocephalus of
the lateral
ventricles, mild,
1.25x

eye (MA:0000261)

Histopath Description:

A 100 stalk of fibrous connective tissue containing a small artery in the center extends from the area of the optic disc towards the posterior vitreous. A small fragment of fibrous tissue is freely present within the vitreous anterior to this stalk (assumed to be extension of the stalk).

Morphological Diagnosis:

MPATH Diagnosis: developmental and structural abnormality MPATH:55; **MPATH Process Term:** developmental and structural abnormality MPATH:55

Definitive Diagnosis:

Persistent hyaloid artery

Histopathology Comments:

hyaloid artery remnant is a rare condition in which there remain some parts of the hyaloid artery. The posterior hyaloid vascular system of mice usually undergoes involution in the first month of life (Richard et al., 2000).

liver (MA:0000358)

Histopath Description:

Marked lipidosi

Morphological Diagnosis:

Distribution: diffuse; **Severity:** severe; **MPATH Diagnosis:** lipid deposition MPATH:42; **MPATH Process Term:** lipid deposition MPATH:42

Definitive Diagnosis:

Hepatic lipidosi

Organ/Tissue Analyzed:

Histopathology examination included the following organs and tissues: brain, trigeminal ganglion, eyes, salivary glands, trachea, lungs, heart, thymus, thyroid gland, parathyroid gland, exocrine and endocrine pancreas, oesophagus, stomach, small intestine, large intestine, liver, gall bladder, spleen, kidneys, adrenal gland, lymph nodes, spinal cord, bone marrow, sternum, femur and tibia with associated skeletal muscles, brown fat, pinna, skin, testis, epididymis, seminal vesicle, and prostate.

AnimalID: M00632675 (Male)

Histopathology Findings:

testis (MA:0000411)

Histopath Description:

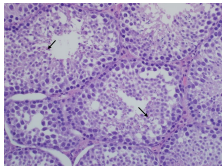
Diffusely seminiferous tubules contain few maturing spermatocytes. Necrotic spermatids are multifocally observed. The epididymis contains abundant cellular debris, but no spermatocytes. Elongated spermatids are inappropriately present within deep layers (spermatid retention).

Morphological Diagnosis:

Distribution: multifocal to coalescing; **Severity:** severe; **MPATH Process Term:** degenerative change MPATH:14

Definitive Diagnosis:

Seminiferous tubule-spermatid necrosis and decreased spermiogenesis; epididymal aspermia.



Testis, seminiferous tubule-spermatid necrosis and decreased spermiogenesis, 40x, HE

epididymal duct (MA:0001735)**Histopath Description:**

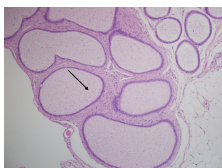The epididymis is devoid of spermatocytes and contains abundant cellular debris and proteinaceous fluid.

Morphological Diagnosis:

Severity: extreme;

Definitive Diagnosis:

Epididymal aspermia



Epididymis, epididymal aspermia, 20x, HE.

brain (MA:0000168)**Histopath Description:**

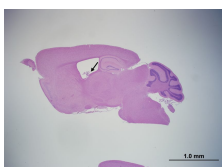
There is moderate dilation of the lateral ventricles. The periventricular neuropil is rarefied.

Morphological Diagnosis:

Duration: Chronic; **Distribution:** Bilateral; **Severity:** mild; **MPATH Diagnosis:** hydrocephalus MPATH:639; **MPATH Process Term:** degenerative change MPATH:14

Definitive Diagnosis:

Bilateral hydrocephalus of the lateral ventricles, mild



Brain, bilateral hydrocephalus of the lateral ventricles, mild, 1.25x

liver (MA:0000358)**Histopath Description:**

Severe lipodosis

Morphological Diagnosis:

Distribution: diffuse; **Severity:** extreme; **MPATH Diagnosis:** lipid deposition MPATH:42; **MPATH Process Term:** lipid deposition MPATH:42

Definitive Diagnosis:

Hepatic lipodosis

Organ/Tissue Analyzed:

Histopathology examination included the following organs and tissues: brain, trigeminal ganglion, eyes, salivary glands, trachea, lungs, heart, thymus, thyroid gland, parathyroid gland, exocrine and endocrine pancreas, oesophagus, stomach, small intestine, large intestine, liver, gall bladder, spleen, kidneys, adrenal gland, lymph nodes, spinal cord, bone marrow, sternum, femur and tibia with associated skeletal muscles, brown fat, pinna, skin, testis, epididymis, seminal vesicle, and prostate.

AnimalID: M00608217 (Female)**Histopathology Findings:****brain (MA:0000168)****Histopath Description:**

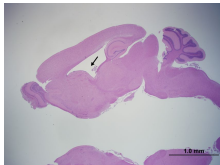
There is mild dilation of the lateral ventricles. The periventricular neuropil is rarefied.

Morphological Diagnosis:

Duration: Chronic; **Distribution:** Bilateral; **Severity:** mild; **MPATH Diagnosis:** hydrocephalus MPATH:639; **MPATH Process Term:** degenerative change MPATH:14

Definitive Diagnosis:

Bilateral hydrocephalus of the lateral ventricles, mild



Brain, bilateral hydrocephalus of the lateral ventricles, mild, 1.25x

liver (MA:0000358)**Histopath Description:**

Severe lipidosis

Morphological Diagnosis:

Distribution: diffuse; **Severity:** extreme; **MPATH Diagnosis:** lipid deposition MPATH:42; **MPATH Process Term:** lipid deposition MPATH:42

Definitive Diagnosis:

Hepatic lipidosis

spleen (MA:0000141)**Histopath Description:**

Mild erythropoiesis-erythroid and megakaryocytic

Morphological Diagnosis:

Distribution: multifocal to coalescing; **Severity:** mild; **MPATH Diagnosis:** extramedullary hemopoiesis MPATH:595; **MPATH Process Term:** hyperplasia MPATH:134

Definitive Diagnosis:

Mild erythropoiesis-erythroid and megakaryocytic

eye (MA:0000261)**Histopath Description:**

Involving one eye, there are clusters of external nuclear structures within the internal plexiform layer.

Morphological Diagnosis:

Distribution: multifocal; **Severity:** mild; **MPATH Process Term:** developmental dysplasia MPATH:64

Definitive Diagnosis:

Retinal dysplasia

Organ/Tissue Analyzed:

Histopathology examination included the following organs and tissues: brain, trigeminal ganglion, eyes, salivary glands, trachea, lungs, heart, thymus, thyroid gland, parathyroid gland, exocrine and endocrine pancreas, oesophagus, stomach, small intestine, large intestine, liver, gall bladder, spleen, kidneys, adrenal gland, lymph nodes, spinal cord, bone marrow, sternum, femur and tibia with associated skeletal muscles, brown fat, pinna, skin, uterus, oviduct, and ovary, and mammary gland.

AnimalID: M00602618 (Female)

Histopathology Findings:

brain (MA:0000168)

Histopath Description:

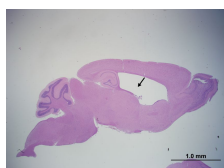There is moderate dilation of the lateral ventricles. The periventricular neuropil is rarefied.

Morphological Diagnosis:

Duration: Chronic; **Distribution:** Bilateral; **Severity:** moderate; **MPATH Diagnosis:** hydrocephalus MPATH:639; **MPATH Process Term:** degenerative change MPATH:14

Definitive Diagnosis:

Bilateral hydrocephalus of the lateral ventricles, mild



Brain, bilateral hydrocephalus of the lateral ventricles, moderate, 1.25x

liver (MA:0000358)

Histopath Description:

Severe lipidosi

Morphological Diagnosis:

Distribution: diffuse; **Severity:** extreme; **MPATH Diagnosis:** lipid deposition MPATH:42; **MPATH Process Term:** lipid deposition MPATH:42

Definitive Diagnosis:

Hepatic lipidosi

spleen (MA:0000141)

Histopath Description:

Mild erythropoiesis

Morphological Diagnosis:

Distribution: multifocal to coalescing; **Severity:** mild; **MPATH Diagnosis:** extramedullary hemopoiesis MPATH:595; **MPATH Process Term:** hyperplasia MPATH:134

Definitive Diagnosis:

Mild erythropoiesis

Organ/Tissue Analyzed:

Histopathology examination included the following organs and tissues: brain, trigeminal ganglion, eyes, salivary glands, trachea, lungs, heart, thymus, thyroid gland, parathyroid gland, exocrine and endocrine pancreas, oesophagus, stomach, small intestine, large intestine, liver, gall bladder, spleen, kidneys, adrenal gland, lymph nodes, spinal cord, bone marrow, sternum, femur and tibia with associated skeletal muscles, brown fat, pinna, skin, uterus, oviduct, and ovary, and mammary gland.

Report Summary and Recommendation:

Seminiferous tubule-spermatid necrosis, retention and decreased spermiogenesis with epididymal aspermia were noted in both males consistent with abnormal fertility/fecundity in this line. Mild to moderate hydrocephalus was noted in all mice in this line. Mild dilation of the brain ventricles is considered incidental in C57B6/N mice. However, the lesion is more severe in this line and may explain some of the locomotory or neurological abnormalities observed by clinical phenotyping. Retinal dysplasia and persistent hyaloid artery are incidentally seen in this strain. These lesions unlikely explain the various eye abnormalities observed in this line.

Line summary:

Testis: Teticular degeneration, spermatogenic abnormality, spermiation defect (2/2)
Brain: Hydrocephalus (4/4).