



CMHD Pathology Report



CMHD Pathology Core

Toronto Centre for
Phenogenomics
25 Orde St. 3rd fl.
Toronto, Ont. M5T 3H7
Tel.(416) 586-8375
Fax (416) 586-5993

contact: Dr. Susan
Newbigging
email:
newbigging@lunenfeld.ca

Principle Investigator: Dr. Jacqui White

Institute: Wellcome Trust Sanger Institute
Address: Attn: Linda Read Wellcome Trust
Genome Campus Hinxton Cambridge CB10
1SA, UK

ReportID: Report Date: March 19, 2014
Pathologist: Dr. H. Adissu

Mouse Genetics Project

Wellcome Trust Sanger
Institute
Wellcome Trust Genome
Campus
Hinxton, Cambridge
CB10 1SA
UK

email:
MGPenquiries@sanger.ac.uk
[Mouse Portal](#)
[Europhenome](#)

CMHD LabID: N13-1257

Relevant History:

Phenotypes:

decreased body weight
absent pinna reflex
trunk curl
impaired righting response
decreased grip strength
improved glucose tolerance
decreased body weight
decreased percent body fat
decreased total body fat amount
hyperactivity
increased energy expenditure
increased carbon dioxide production
increased oxygen consumption
increased fluid intake
decreased circulating amylase level
decreased circulating triglyceride level
decreased circulating potassium level
decreased circulating cholesterol level
increased circulating chloride level
abnormal brainstem auditory evoked potential

AnimalID: M01183795 (Male)

Histopathology Findings:

spleen (MA:0000141)

Histopath Description:

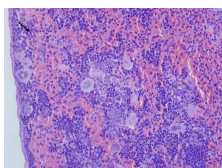
Moderate erythropoiesis, granulopoiesis, and megakaryopoiesis

Morphological Diagnosis:

Distribution: multifocal to coalescing; **Severity:** moderate; **MPATH Diagnosis:** extramedullary hemopoiesis MPATH:595; **MPATH Process Term:** hyperplasia MPATH:134

Definitive Diagnosis:

Moderate erythropoiesis, granulopoiesis, and megakaryopoiesis



Spleen, moderate
erythropoiesis,
granulopoiesis, and
megakaryopoiesis,
40x, HE

mesenteric lymph node (MA:0002829)

Histopath Description:

The mesenteric lymph node is markedly enlarged (greater than four-fold). The medulla is expanded by chords and sheets of lymphocytes. There are multiple germinal centers.

Morphological Diagnosis:

Distribution: Diffuse; **Severity:** moderate; **MPATH Diagnosis:** hyperplasia MPATH:134;
MPATH Process Term: hyperplasia MPATH:134

Definitive Diagnosis:

Lymphoid hyperplasia with medullary plasmacytosis.

Histopathology Comments:

The changes in the mesenteric lymph node are suggestive of draining of a regional inflammatory process. However, such a process was not observed in the tissues examined.

Organ/Tissue Analyzed:

Histopathology examination included the following organs and tissues: brain, trigeminal ganglion, eyes, salivary glands, trachea, lungs, heart, thymus, thyroid gland, parathyroid gland, exocrine and endocrine pancreas, oesophagus, stomach, small intestine, large intestine, liver, gall bladder, spleen, kidneys, adrenal gland, lymph nodes, spinal cord, bone marrow, sternum, femur and tibia with associated skeletal muscles, brown fat, pinna, skin, testis, epididymis, seminal vesicle, and prostate.

AnimalID: M01183770 (Male)**Histopathology Findings:****spleen (MA:0000141)****Histopath Description:**

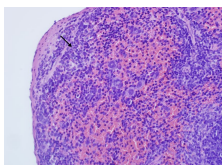
Moderate erythropoiesis, granulopoiesis, and megakaryopoiesis

Morphological Diagnosis:

Distribution: multifocal to coalescing; **Severity:** moderate; **MPATH Diagnosis:** extramedullary hemopoiesis MPATH:595; **MPATH Process Term:** hyperplasia MPATH:134

Definitive Diagnosis:

Moderate erythropoiesis, granulopoiesis, and megakaryopoiesis



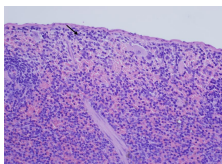
Spleen, moderate erythropoiesis, granulopoiesis, and megakaryopoiesis, 40x, HE

Organ/Tissue Analyzed:

Histopathology examination included the following organs and tissues: brain, trigeminal ganglion, eyes, salivary glands, trachea, lungs, heart, thymus, thyroid gland, parathyroid gland, exocrine and endocrine pancreas, oesophagus, stomach, small intestine, large intestine, liver, gall bladder, spleen, kidneys, adrenal gland, lymph nodes, spinal cord, bone marrow, sternum, femur and tibia with associated skeletal muscles, brown fat, pinna, skin, testis, epididymis, seminal vesicle, and prostate.

AnimalID: M01183775 (Female)**Histopathology Findings:****spleen (MA:0000141)****Definitive Diagnosis:**

Normal



Spleen, normal, 40x, HE

Organ/Tissue Analyzed:

Histopathology examination included the following organs and tissues: brain, trigeminal ganglion, eyes, salivary glands, trachea, lungs, heart, thymus, thyroid gland, parathyroid gland, exocrine and endocrine pancreas, oesophagus, stomach, small intestine, large intestine, liver, gall bladder, spleen, kidneys, adrenal gland, lymph nodes, spinal cord, bone marrow, sternum, femur and tibia with associated skeletal muscles, brown fat, pinna, skin, uterus, oviduct, and ovary, and mammary gland.

AnimalID: M01183778 (Female)**Histopathology Findings:****adrenal gland (MA:0000116)****Histopath Description:**

There is a small, well-circumscribed mass in the cortex. It is encapsulated by a thin layer of pale eosinophilic material and fusiform cells (connective tissue with fibroblasts) and is made of nests of polygonal cells interspersed by a very thin fibrovascular membrane. The architecture is reminiscent of the zona glomerulosa and zona fasciculate of the mature adrenal gland.

Morphological Diagnosis:

Distribution: focal; **MPATH Process Term:** developmental and structural abnormality
MPATH:55

Definitive Diagnosis:

accessory adrenal cortical tissue

Histopathology Comments:

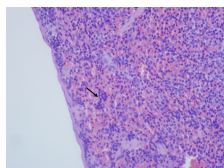
This is an incidental finding

spleen (MA:0000141)**Histopath Description:**

Normal

Definitive Diagnosis:

Normal



Spleen, normal,
40x, HE

Organ/Tissue Analyzed:

Histopathology examination included the following organs and tissues: brain, trigeminal ganglion, eyes, salivary glands, trachea, lungs, heart, thymus, thyroid gland, parathyroid gland, exocrine and endocrine pancreas, oesophagus, stomach, small intestine, large intestine, liver, gall bladder, spleen, kidneys, adrenal gland, lymph nodes, spinal cord, bone marrow, sternum, femur and tibia with associated skeletal muscles, brown fat, pinna, skin, uterus, oviduct, and ovary, and mammary gland.

Report Summary and Recommendation:

Trilineage erythropoiesis is present in two mice. We did not observe morphological explanation for the various phenotypes in this line. The auricular tissues are not available to rule out potential otitis or other conductive causes of absent pinna reflex.

Line summary:

Spleen, trilineage hematopoiesis (2/4)