



CMHD Pathology Report



CMHD Pathology Core

Toronto Centre for
Phenogenomics
25 Orde St. 3rd fl.
Toronto, Ont. M5T 3H7
Tel.(416) 586-8375
Fax (416) 586-5993

contact: Dr. Susan
Newbigging
email:
newbigging@lunenfeld.ca

Principle Investigator: Dr. Jacqui White

Institute: Wellcome Trust Sanger Institute
Address: Attn: Linda Read Wellcome Trust
Genome Campus Hinxton Cambridge CB10
1SA, UK

ReportID: Report Date: October 15, 2013
Pathologist: Dr. H. Adissu

Mouse Genetics Project

Wellcome Trust Sanger
Institute
Wellcome Trust Genome
Campus
Hinxton, Cambridge
CB10 1SA
UK

email:
MGPenquiries@sanger.ac.uk
[Mouse Portal](#)
[Europeome](#)

CMHD LabID: N13-699

Relevant History:

Phenotypes:

decreased circulating cholesterol level
decreased circulating LDL cholesterol level
preweaning lethality

AnimalID: M00712927 (Female)

Histopathology Findings:

liver (MA:0000358)

Histopath Description:

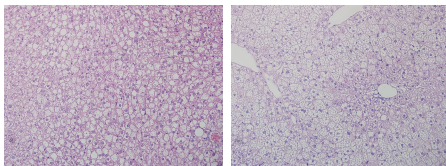
diffuse lipidosis

Morphological Diagnosis:

Distribution: diffuse; **Severity:** extreme; **MPATH Diagnosis:** steatosis MPATH:622; **MPATH Process Term:** lipid deposition MPATH:42

Definitive Diagnosis:

hepatic steatosis



Liver, severe
lipidosis, 20x, HE

Liver, WT, severe
lipidosis, 20x, HE

spleen (MA:0000141)

Histopath Description:

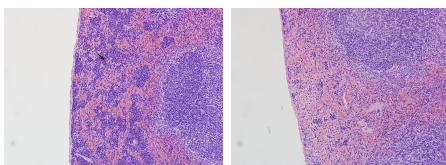
moderate erythropoiesis

Morphological Diagnosis:

Distribution: multifocal to coalescing; **Severity:** moderate; **MPATH Diagnosis:** extramedullary hemopoiesis MPATH:595; **MPATH Process Term:** hyperplasia MPATH:134

Definitive Diagnosis:

moderate erythropoiesis

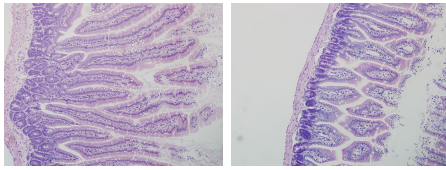


spleen, moderate
erythropoiesis, 20x,
HE

Spleen, WT, normal
low level
erythropoiesis, 20x,
HE

intestine (MA:0000328)**Histopath Description:**

Normal



Duodenum, 20x, HE Duodenum, WT, 20x, HE

Organ/Tissue Analyzed:

Histopathology examination included the following organs and tissues: brain, trigeminal ganglion, eyes, salivary glands, trachea, lungs, heart, thymus, thyroid gland, parathyroid gland, exocrine and endocrine pancreas, oesophagus, stomach, small intestine, large intestine, liver, gall bladder, spleen, kidneys, adrenal gland, lymph nodes, spinal cord, bone marrow, sternum, femur and tibia with associated skeletal muscles, brown fat, pinna, skin, uterus, oviduct, and ovary, and mammary gland.

AnimalID: M00712928 (Female)**Histopathology Findings:****liver (MA:0000358)****Histopath Description:**

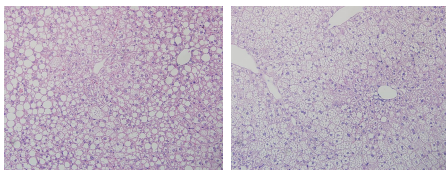
diffuse lipidosi

Morphological Diagnosis:

Distribution: diffuse; **Severity:** extreme; **MPATH Diagnosis:** steatosis MPATH:622; **MPATH Process Term:** lipid deposition MPATH:42

Definitive Diagnosis:

hepatic steatosis



Liver, severe lipidosi, 20x, HE Liver, WT, severe lipidosi, 20x, HE

spleen (MA:0000141)**Histopath Description:**

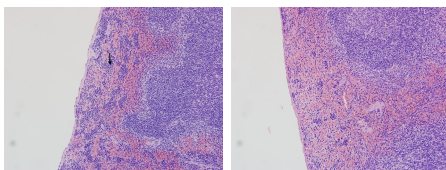
mild erythropoiesi

Morphological Diagnosis:

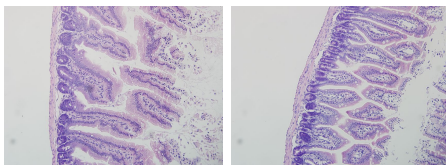
Distribution: multifocal to coalescing; **Severity:** moderate; **MPATH Diagnosis:** extramedullary hemopoiesi MPATH:595; **MPATH Process Term:** hyperplasia MPATH:134

Definitive Diagnosis:

mild erythropoiesi



spleen, mild erythropoiesi, 20x, HE Spleen, WT, normal low level erythropoiesi, 20x, HE

intestine (MA:0000328)

Duodenum, 20x, HE Duodenum, 20x, HE

Organ/Tissue Analyzed:

Histopathology examination included the following organs and tissues: brain, trigeminal ganglion, eyes, salivary glands, trachea, lungs, heart, thymus, thyroid gland, parathyroid gland, exocrine and endocrine pancreas, oesophagus, stomach, small intestine, large intestine, liver, gall bladder, spleen, kidneys, adrenal gland, lymph nodes, spinal cord, bone marrow, sternum, femur and tibia with associated skeletal muscles, brown fat, pinna, skin, uterus, oviduct, and ovary, and mammary gland.

AnimalID: M00748140 (Male)**Histopathology Findings:****liver (MA:0000358)****Histopath Description:**

very minimal lipidosis

Morphological Diagnosis:

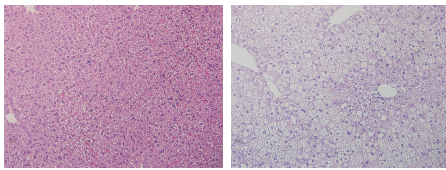
Distribution: multifocal; **Severity:** mild; **MPATH Process Term:** lipid deposition MPATH:42

Definitive Diagnosis:

Minimal hepatic lipidosis

Histopathology Comments:

Hepatic lipidosis is minimal in this mouse despite high fat diet



Liver, minimal
lipidosis, 20x, HE

Liver, WT, severe
lipidosis, 20x, HE

intestine (MA:0000328)**Histopath Description:**

Villi contain abundant lipid vacuoles that occasionally coalesced into multiloculated large vacuoles.

Morphological Diagnosis:

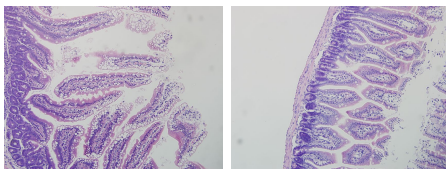
Distribution: multifocal to coalescing; **Severity:** extreme; **MPATH Process Term:** lipid deposition MPATH:42

Definitive Diagnosis:

Duodenal lipidosis

Histopathology Comments:

Note that this change could be seen in WT mouse post-feeding (see summary for more detail discussion)



Duodenum,
intestinal lipidosis,
20x, HE

Duodenum, 20x, HE

peritoneal cavity (MA:0000054)**Histopath Description:**

There is extensive chronic pyogranulomatous retroperitonitis with adhesion of the seminal vesicle and the colon. Foreign bodies consistent with hair fragments are detected by polarized light.

Morphological Diagnosis:

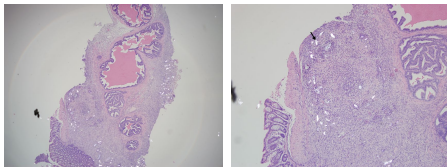
Distribution: focally extensive; **Severity:** extreme; **MPATH Process Term:** inflammation MPATH:212

Definitive Diagnosis:

Pyogranulomatous retroperitonitis with intralesional hair fragments; extensive adhesion of colon and seminal vesicles.

Histopathology Comments:

The lesion was likely caused by a penetrating injury in the distal colon



Colon and seminal vesicle, retroperitonitis, 4x, HE

Colon and seminal vesicle, retroperitonitis, note foreign bodies, 10x, HE

spleen (MA:0000141)

Histopath Description:

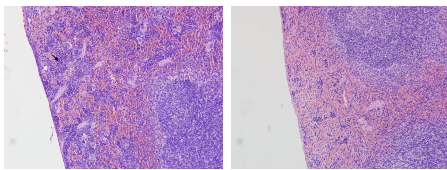
moderate erythropoiesis and megakaryopoiesis

Morphological Diagnosis:

Distribution: multifocal to coalescing; **Severity:** moderate; **MPATH Diagnosis:** extramedullary hemoipoiesis MPATH:595; **MPATH Process Term:** hyperplasia MPATH:134

Definitive Diagnosis:

moderate erythropoiesis and megakaryopoiesis



spleen, moderate erythropoiesis and megakaryopoiesis, 20x, HE

Spleen, WT, normal low level erythropoiesis, 20x, HE

bone marrow (MA:0000134)

Histopath Description:

There is a marked increase in granulocytic myeloid cell population (myeloid erythroid ratio of estimated 6:1 to 8:1)

Morphological Diagnosis:

Severity: severe; **MPATH Diagnosis:** hyperplasia MPATH:134; **MPATH Process Term:** hyperplasia MPATH:134

Definitive Diagnosis:

Granulocytic myeloid hypoplasia (erythroid hypoplasia)

Histopathology Comments:

The myeloid granulocytic hyperplasia is likely in response to increased demand associated with retroperitonitis and auricular dermatitis (see below).

ear (MA:0000236)

Histopath Description:

Multifocally there are serocellular crusts (scabs) on the ear skin. There are low numbers of mononuclear and rare polymorphonuclear inflammatory cells within the dermis. The epidermis is multifocally hyperplastic.

Morphological Diagnosis:

Distribution: multifocal; **Severity:** mild; **MPATH Diagnosis:** inflammation MPATH:212; **MPATH Process Term:** inflammation MPATH:212

Definitive Diagnosis:

Dermatitis with epidermal hyperplasia

Organ/Tissue Analyzed:

Histopathology examination included the following organs and tissues: brain, trigeminal ganglion, eyes, salivary glands, trachea, lungs, heart, thymus, thyroid gland, parathyroid gland, exocrine and endocrine pancreas, oesophagus, stomach, small intestine, large intestine, liver, gall bladder, spleen, kidneys, adrenal gland, lymph nodes, spinal cord, bone marrow, sternum, femur and tibia with associated skeletal muscles, brown fat, pinna, skin, testis, epididymis, seminal vesicle, and prostate.

AnimalID: M00753859 (Male)

Histopathology Findings:

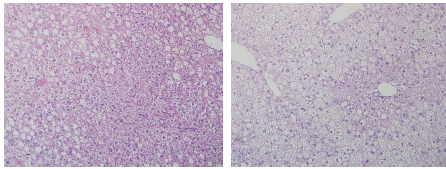
liver (MA:0000358)

Histopath Description:

moderate lipidosis

Morphological Diagnosis:**Distribution:** multifocal to coalescing; **Severity:** moderate; **MPATH Diagnosis:** steatosis MPATH:622; **MPATH Process Term:** lipid deposition MPATH:42**Definitive Diagnosis:**

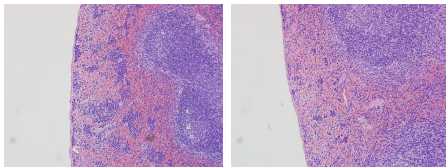
hepatic steatosis

Liver, moderate
lipidosis, 20x, HELiver, severe
lipidosis, 20x, HE**spleen (MA:0000141)****Histopath Description:**

mild erythropoiesis

Morphological Diagnosis:**Distribution:** multifocal to coalescing; **Severity:** moderate; **MPATH Diagnosis:** extramedullary hemopoiesis MPATH:595; **MPATH Process Term:** hyperplasia MPATH:134**Definitive Diagnosis:**

mild erythropoiesis

Spleen, mild
erythropoiesis, 20x,
HESpleen, WT, normal
low level
erythropoiesis, 20x,
HE**retina (MA:0000276)****Histopath Description:**

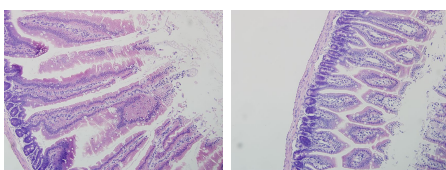
Involving one eye, there are clusters of external nuclear structures within the internal and outer plexiform layer.

Morphological Diagnosis:**Distribution:** Focal; **Severity:** mild; **MPATH Process Term:** developmental dysplasia MPATH:64**Definitive Diagnosis:**

Retinal dysplasia

intestine (MA:0000328)**Histopath Description:**

Normal



Duodenum, 20x, HE

Duodenum, 20x, HE

Organ/Tissue Analyzed:

Histopathology examination included the following organs and tissues: brain, trigeminal ganglion, eyes, salivary glands, trachea, lungs, heart, thymus, thyroid gland, parathyroid gland, exocrine and endocrine pancreas, oesophagus, stomach, small intestine, large intestine, liver, gall bladder, spleen, kidneys, adrenal gland, lymph nodes, spinal cord, bone marrow, sternum, femur and tibia with associated skeletal muscles, brown fat, pinna, skin, testis, epididymis, seminal vesicle, and prostate.

Report Summary and Recommendation:

There is absence of hepatic lipidosis in one male and moderate lipidosis in another. Male mice normally show more severe hepatic lipidosis under high fat diet; hence the changes are consistent with the clinical biochemistry in male mice in this line (decreased circulating cholesterol level decreased circulating LDL cholesterol level in males). The variation in the histopath phenotype. Intestinal (duodenal) villar lipidosis is evident in the mouse with minimal lipidosis. It is not certain whether this represents a lipid malabsorption. Intestinal lipidosis is seen in WT mice on high fat diet post feeding. Hence the intestinal lipidosis in this mouse may be the result of a periportem feeding; thus should be interpreted with caution.

Mild to marked extramedullary erythropoiesis and megakaryopoiesis is seen in all mice.

There are no lesions predictive of homozygous lethality at P14. Analysis of preweaning homozygous animals is required to determine cause of mortality.

Line summary:

Liver: minimal to moderate lipidosis (2/4)

Spleen: Mild to marked extramedullary hematopoiesis (4/4)