



CMHD Pathology Report



CMHD Pathology Core

Toronto Centre for
Phenogenomics
25 Orde St. 3rd fl.
Toronto, Ont. M5T 3H7
Tel.(416) 586-8375
Fax (416) 586-5993

contact: Dr. Susan
Newbigging
email:
newbigging@lunenfeld.ca

Principle Investigator: Dr. Jacqui White

Institute: Wellcome Trust Sanger Institute
Address: Attn: Linda Read Wellcome Trust
Genome Campus Hinxton Cambridge CB10
1SA, UK

ReportID: Report Date: February 13,
2014
Pathologist: Dr. H. Adissu

Mouse Genetics Project

Wellcome Trust Sanger
Institute
Wellcome Trust Genome
Campus
Hinxton, Cambridge
CB10 1SA
UK

email:
MGPenquiries@sanger.ac.uk
[Mouse Portal](#)
[Europhenome](#)

CMHD LabID: N13-918

Relevant History:

Phenotypes:

abnormal body weight MP:0001259
abnormal eyelid morphology
corneal opacity
decreased survivor rate

AnimalID: M00765606 (Male)

Histopathology Findings:

liver (MA:0000358)

Histopath Description:

Mild lipidosi

Morphological Diagnosis:

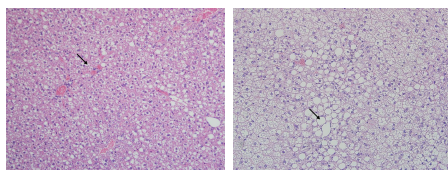
Distribution: multifocal to coalescing; **Severity:** mild; **MPATH Diagnosis:** lipid deposition
MPATH:42; **MPATH Process Term:** lipid deposition MPATH:42

Definitive Diagnosis:

Hepatic lipidosi

Histopathology Comments:

The level of lipid deposition is minimal in light of the high fat diet.



Liver, minimal
lipidosi, 20x, HE

Liver, WT, severe
lipidosi, 20x, HE

testis (MA:0000411)

Histopath Description:

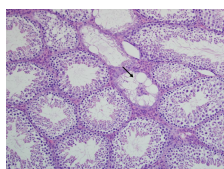
Nearly 10% of the seminiferous tubules are vacuolated and atrophic with empty lumen.

Morphological Diagnosis:

Distribution: Multifocal; **Severity:** mild; **MPATH Diagnosis:** atrophy MPATH:127; **MPATH Process Term:** atrophy MPATH:127

Definitive Diagnosis:

Testicular degeneration and atrophy



Testis, multifocal

seminiferous
atrophy, 20x, HE

Organ/Tissue Analyzed:

Histopathology examination included the following organs and tissues: brain, trigeminal ganglion, eyes, salivary glands, trachea, lungs, heart, thymus, thyroid gland, parathyroid gland, exocrine and endocrine pancreas, oesophagus, stomach, small intestine, large intestine, liver, gall bladder, spleen, kidneys, adrenal gland, lymph nodes, spinal cord, bone marrow, sternum, femur and tibia with associated skeletal muscles, brown fat, pinna, skin, testis, epididymis, seminal vesicle, and prostate.

AnimalID: M00765605 (Female)

Histopathology Findings:

liver (MA:0000358)

Histopath Description:

Mild lipidosis

Morphological Diagnosis:

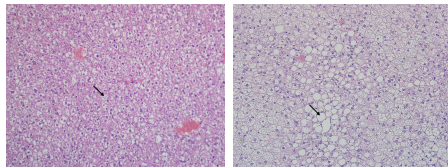
Distribution: multifocal to coalescing; **Severity:** mild; **MPATH Diagnosis:** lipid deposition MPATH:42; **MPATH Process Term:** lipid deposition MPATH:42

Definitive Diagnosis:

Hepatic lipidosis

Histopathology Comments:

The level of lipid deposition is minimal in light of the high fat diet.



Liver, WT, minimal
lipidosis, 20x, HE

Liver, WT, severe
lipidosis, 20x, HE

brain (MA:0000168)

Histopath Description:

There is moderate dilation of the fourth ventricle

Morphological Diagnosis:

Distribution: diffuse; **Severity:** mild; **MPATH Process Term:** degenerative change MPATH:14

Definitive Diagnosis:

Dilation of the brain ventricles

Histopathology Comments:

Mild dilation of the ventricles is a background condition in mice of C57BL/6N background

Organ/Tissue Analyzed:

Histopathology examination included the following organs and tissues: brain, trigeminal ganglion, eyes, salivary glands, trachea, lungs, heart, thymus, thyroid gland, parathyroid gland, exocrine and endocrine pancreas, oesophagus, stomach, small intestine, large intestine, liver, gall bladder, spleen, kidneys, adrenal gland, lymph nodes, spinal cord, bone marrow, sternum, femur and tibia with associated skeletal muscles, brown fat, pinna, skin, uterus, oviduct, and ovary, and mammary gland.

AnimalID: M00679782 (Female)

Histopathology Findings:

liver (MA:0000358)

Histopath Description:

Marked hepatic lipidosis

Morphological Diagnosis:

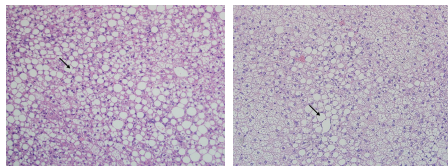
Distribution: Diffuse; **Severity:** severe; **MPATH Diagnosis:** steatosis MPATH:622; **MPATH Process Term:** lipid deposition MPATH:42

Definitive Diagnosis:

Hepatic lipidosis

Histopathology Comments:

Hepatocellular vacuolar change of variable degree suggestive of lipidosis is present in all mice from WTSI, consistent with high lipid diet.

Liver, WT, severe
lipidosis, 20x, HELiver, WT, severe
lipidosis, 20x, HE**spleen (MA:0000141)****Histopath Description:**

mild erythropoiesis

Morphological Diagnosis:**Distribution:** multifocal to coalescing; **Severity:** moderate; **MPATH Diagnosis:** extramedullary hemopoiesis MPATH:595; **MPATH Process Term:** hyperplasia MPATH:134**Definitive Diagnosis:**

mild erythropoiesis

lymph node (MA:0000139)**Histopath Description:**

Overall, the mesenteric lymph node is distinctly basophilic. Its architecture is disrupted by diffuse sheets of monotypic round cells that distended the subcapsular, medullary and occasional transverse sinuses. The cells have scant or no visible cytoplasm, round nuclei with stippled chromatin and a central distinct nucleolus (interpreted as lymphocytes). Rare apoptotic bodies and mitotic figures are present within occasional germinal centers.

Morphological Diagnosis:**MPATH Diagnosis:** lymphoid neoplasms MPATH:513; **MPATH Process Term:** neoplasia MPATH:218**Definitive Diagnosis:**

Lymphoma

Histopathology Comments:

The presence of diffuse sheets of monomorphic lymphocytes within the sinuses is suggestive of lymphoma. Note all mice in this line have mesenteric lymphoma.

Organ/Tissue Analyzed:

Histopathology examination included the following organs and tissues: brain, trigeminal ganglion, eyes, salivary glands, trachea, heart, thymus, thyroid gland, parathyroid gland, exocrine and endocrine pancreas, oesophagus, stomach, small intestine, large intestine, liver, gall bladder, spleen, kidneys, adrenal gland, lymph nodes, spinal cord, bone marrow, sternum, femur and tibia with associated skeletal muscles, brown fat, pinna, skin, uterus, oviduct, and ovary, and mammary gland.

AnimalID: M00679781 (Female)**Histopathology Findings:****liver (MA:0000358)****Histopath Description:**

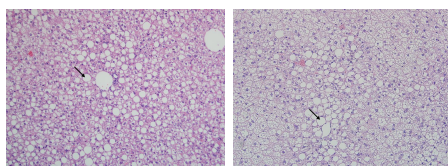
Marked hepatic lipidosis

Morphological Diagnosis:**Distribution:** Diffuse; **Severity:** severe; **MPATH Diagnosis:** steatosis MPATH:622; **MPATH Process Term:** lipid deposition MPATH:42**Definitive Diagnosis:**

Hepatic lipidosis

Histopathology Comments:

Hepatocellular vacuolar change of variable degree suggestive of lipidosis is present in all mice from WTS1, consistent with high lipid diet.

Liver, WT, severe
lipidosis, 20x, HELiver, WT, severe
lipidosis, 20x, HE

Organ/Tissue Analyzed:

Histopathology examination included the following organs and tissues: brain, trigeminal ganglion, eyes, salivary glands, trachea, lungs, heart, thymus, thyroid gland, parathyroid gland, exocrine and endocrine pancreas, oesophagus, stomach, small intestine, large intestine, liver, gall bladder, spleen, kidneys, adrenal gland, lymph nodes, spinal cord, bone marrow, sternum, femur and tibia with associated skeletal muscles, brown fat, pinna, skin, uterus, oviduct, and ovary, and mammary gland.

Report Summary and Recommendation:

Minimal hepatic lipidosis is observed in two males. Males are more susceptible to hepatic dietary lipidosis. Hence, this observation in males may have significance to the abnormal body weight observed in this line. One male have multifocal seminiferous atrophy in the testis. The cornea is within normal limits. The eyelids are not available for histopathology analysis to explain the abnormal eyelid morphology detected in clinical phenotyping. We did not see lesions that explain or are predictive of decreased survival rate in this line.

Line summary:

Liver: Minimal lipidosis (2/4)

Testis: Seminiferous atrophy, multifocal (1/2).