



CMHD Pathology Report



CMHD Pathology Core

Toronto Centre for
Phenogenomics
25 Orde St. 3rd fl.
Toronto, Ont. M5T 3H7
Tel.(416) 586-8375
Fax (416) 586-5993

contact: Dr. Susan
Newbigging
email:
newbigging@lunenfeld.ca

Principle Investigator: Dr. Jacqui White

Institute: Wellcome Trust Sanger Institute
Address: Attn: Linda Read Wellcome Trust
Genome Campus Hinxton Cambridge CB10
1SA, UK

ReportID: Report Date: February 13,
2014
Pathologist: Dr. H. Adissu

Mouse Genetics Project

Wellcome Trust Sanger
Institute
Wellcome Trust Genome
Campus
Hinxton, Cambridge
CB10 1SA
UK

email:
MGPenquiries@sanger.ac.uk
[Mouse Portal](#)
[Europhenome](#)

CMHD LabID: N13-919

Relevant History:

Phenotype:

decreased circulating alkaline phosphatase level
hypoalbuminemia

AnimalID: M00716088 (Male)

Histopathology Findings:

liver (MA:0000358)

Histopath Description:

Mild lipidosis

Morphological Diagnosis:

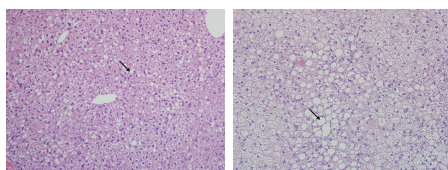
Distribution: multifocal to coalescing; **Severity:** mild; **MPATH Diagnosis:** lipid deposition
MPATH:42; **MPATH Process Term:** lipid deposition MPATH:42

Definitive Diagnosis:

Hepatic lipidosis

Histopathology Comments:

The level of lipid deposition is minimal in light of the high fat diet.



Liver, minimal
lipidosis, 20x, HE

Liver, WT, severe
lipidosis, 20x, HE

pancreas (MA:0000120)

Histopath Description:

Multifocal perivascular chronic inflammatory aggregates

Morphological Diagnosis:

Distribution: multifocal; **Severity:** mild; **MPATH Process Term:** inflammation MPATH:212

Definitive Diagnosis:

Multifocal perivascular chronic inflammatory aggregates

Histopathology Comments:

incidental

lymph node (MA:0000139)

Histopath Description:

Overall, the mesenteric lymph node is distinctly basophilic. Its architecture is disrupted by diffuse sheets of monotypic round cells that distended the subcapsular, medullary and occasional transverse sinuses. The cells have scant or no visible cytoplasm, round nuclei with stippled chromatin and a central distinct nucleolus (interpreted as lymphocytes). Rare apoptotic bodies and mitotic figures are

present within occasional germinal centers.

Morphological Diagnosis:

MPATH Diagnosis: lymphoid neoplasms MPATH:513; **MPATH Process Term:** neoplasia MPATH:218

Definitive Diagnosis:

Lymphoma

Histopathology Comments:

The presence of diffuse sheets of monomorphic lymphocytes within the sinuses is suggestive of lymphoma. Note all mice in this line have mesenchymal lymphoma.

Organ/Tissue Analyzed:

Histopathology examination included the following organs and tissues: brain, trigeminal ganglion, eyes, salivary glands, trachea, lungs, heart, thymus, thyroid gland, parathyroid gland, exocrine and endocrine pancreas, oesophagus, stomach, small intestine, large intestine, liver, gall bladder, spleen, kidneys, adrenal gland, lymph nodes, spinal cord, bone marrow, sternum, femur and tibia with associated skeletal muscles, brown fat, pinna, skin, testis, epididymis, seminal vesicle, and prostate.

AnimalID: M00771547 (Male)

Histopathology Findings:

liver (MA:0000358)

Histopath Description:

Mild lipidosis

Morphological Diagnosis:

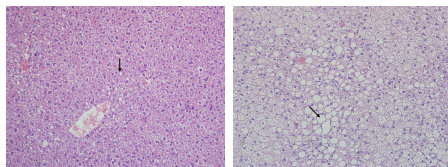
Distribution: multifocal to coalescing; **Severity:** mild; **MPATH Diagnosis:** lipid deposition MPATH:42; **MPATH Process Term:** lipid deposition MPATH:42

Definitive Diagnosis:

Hepatic lipidosis

Histopathology Comments:

The level of lipid deposition is minimal in light of the high fat diet.



Liver, minimal lipidosis, 20x, HE

Liver, WT, severe lipidosis, 20x, HE

brain (MA:0000168)

Histopath Description:

There is moderate dilation of the fourth ventricle

Morphological Diagnosis:

Distribution: diffuse; **Severity:** mild; **MPATH Process Term:** degenerative change MPATH:14

Definitive Diagnosis:

Dilation of the brain ventricles

Histopathology Comments:

Mild dilation of the ventricles is a background condition in mice of C57BL/6N background

Organ/Tissue Analyzed:

Histopathology examination included the following organs and tissues: brain, trigeminal ganglion, eyes, salivary glands, trachea, lungs, heart, thymus, thyroid gland, parathyroid gland, exocrine and endocrine pancreas, oesophagus, stomach, small intestine, large intestine, liver, gall bladder, spleen, kidneys, adrenal gland, lymph nodes, spinal cord, bone marrow, sternum, femur and tibia with associated skeletal muscles, brown fat, pinna, skin, testis, epididymis, seminal vesicle, and prostate.

AnimalID: M00716092 (Female)

Histopathology Findings:

liver (MA:0000358)

Histopath Description:

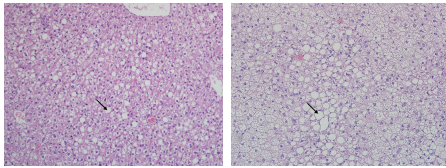
Moderate lipidosis

Morphological Diagnosis:

Distribution: multifocal to coalescing; **Severity:** moderate; **MPATH Diagnosis:** lipid deposition MPATH:42; **MPATH Process Term:** lipid deposition MPATH:42

Definitive Diagnosis:

Hepatic lipidosis



Liver, moderate
lipidosis, 20x, HE

Liver, WT, severe
lipidosis, 20x, HE

lymph node (MA:0000139)**Histopath Description:**

The mesenteric lymph node is markedly enlarged (greater than four fold). The medulla is particularly expanded by chords and sheets of plasmotoid cells. There are prominent germinal centers within the medulla

Morphological Diagnosis:

Distribution: Diffuse; **Severity:** moderate; **MPATH Diagnosis:** hyperplasia MPATH:134; **MPATH Process Term:** hyperplasia MPATH:134

Definitive Diagnosis:

Lymphoid hyperplasia

Histopathology Comments:

The changes in the mesenteric lymph node are suggestive of draining of a regional inflammatory process. However, such a process was not observed in the tissues examined. Early maginal center lymphoma is suspected.

Organ/Tissue Analyzed:

Histopathology examination included the following organs and tissues: brain, trigeminal ganglion, eyes, salivary glands, trachea, lungs, heart, thymus, thyroid gland, parathyroid gland, exocrine and endocrine pancreas, oesophagus, stomach, small intestine, large intestine, liver, gall bladder, spleen, kidneys, adrenal gland, lymph nodes, spinal cord, bone marrow, sternum, femur and tibia with associated skeletal muscles, brown fat, pinna, skin, uterus, oviduct, and ovary, and mammary gland.

AnimalID: M00748455 (Female)**Histopathology Findings:****liver (MA:0000358)****Histopath Description:**

Mild lipidosis

Morphological Diagnosis:

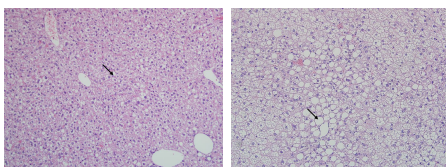
Distribution: multifocal to coalescing; **Severity:** mild; **MPATH Diagnosis:** lipid deposition MPATH:42; **MPATH Process Term:** lipid deposition MPATH:42

Definitive Diagnosis:

Hepatic lipidosis

Histopathology Comments:

The level of lipid deposition is minimal in light of the high fat diet.



Liver, minimal
lipidosis, 20x, HE

Liver, WT, severe
lipidosis, 20x, HE

brain (MA:0000168)**Histopath Description:**

There is moderate dilation of the fourth ventricle

Morphological Diagnosis:

Distribution: diffuse; **Severity:** mild; **MPATH Process Term:** degenerative change MPATH:14

Definitive Diagnosis:

Dilation of the brain ventricles

Histopathology Comments:

Mild dilation of the ventricles is a background condition in mice of C57BL/6N background

Lymph node (MA:0000139)**Histopath Description:**

Overall, the mesenteric lymph node is distinctly basophilic. Its architecture is disrupted by diffuse sheets of monotypic round cells that distended the subcapsular, medullary and occasional transverse sinuses. The cells have scant or no visible cytoplasm, round nuclei with stippled chromatin and a central distinct nucleolus (interpreted as lymphocytes). Rare apoptotic bodies and mitotic figures are present within occasional germinal centers.

Morphological Diagnosis:

MPATH Diagnosis: lymphoid neoplasms MPATH:513; **MPATH Process Term:** neoplasia MPATH:218

Definitive Diagnosis:

Lymphoma

Histopathology Comments:

The presence of diffuse sheets of monomorphic lymphocytes within the sinuses is suggestive of lymphoma. Note all mice in this line have mesenteric lymphoma.

Organ/Tissue Analyzed:

Histopathology examination included the following organs and tissues: brain, trigeminal ganglion, eyes, salivary glands, trachea, lungs, heart, thymus, thyroid gland, parathyroid gland, exocrine and endocrine pancreas, oesophagus, stomach, small intestine, large intestine, liver, gall bladder, spleen, kidneys, adrenal gland, lymph nodes, spinal cord, bone marrow, sternum, femur and tibia with associated skeletal muscles, brown fat, pinna, skin, uterus, oviduct, and ovary, and mammary gland.

Report Summary and Recommendation:

Minimal hepatic lipidosis is observed in three mice despite high fat diet. Low level of albumin (hypoalbuminemia) may result in decreased fatty acid transportation. The minimal hepatic lipidosis may also be a reflection of poor condition secondary to hypoalbuminemia. The cause for hypoalbuminemia is not certain. The kidney and the liver are within normal limit, except the minimal lipidosis in the latter. This suggests that there may be a problem of protein assimilation in this animal. One possible cause of protein assimilation is low stomach acid production/hypochlorhydria. This abnormality could also explain the decreased circulating alkaline phosphatase level. The stomach is apparently normal, but we could not rule out functional abnormality.

Line summary:

Liver: Minimal lipidosis (3/4)