



CMHD Pathology Report



CMHD Pathology Core

Toronto Centre for
Phenogenomics
25 Orde St. 3rd fl.
Toronto, Ont. M5T 3H7
Tel.(416) 586-8375
Fax (416) 586-5993

contact: Dr. Susan
Newbigging
email:
newbigging@lunenfeld.ca

Principle Investigator: Dr. Jacqui White

Institute: Wellcome Trust Sanger Institute
Address: Attn: Linda Read Wellcome Trust
Genome Campus Hinxton Cambridge CB10
1SA, UK

ReportID: Report Date: January 07, 2014
Pathologist: Dr. H. Adissu

Mouse Genetics Project

Wellcome Trust Sanger
Institute
Wellcome Trust Genome
Campus
Hinxton, Cambridge
CB10 1SA
UK

email:
MGPenquiries@sanger.ac.uk
[Mouse Portal](#)
[Europhenome](#)

CMHD LabID: N13-706

Relevant History:

Phenotype

decreased granulocyte number

decreased NK cell number.

Mouse M00921319, "Seminal Vesicles - small seminal vesicle [MP:0001157]. left side, Testis+Epididymus - abnormal epididymis morphology [MP:0002631]. left epididymis enlarged"

AnimalID: M00921319 (Male)

Histopathology Findings:

lymph node (MA:0000139)

Histopath Description:

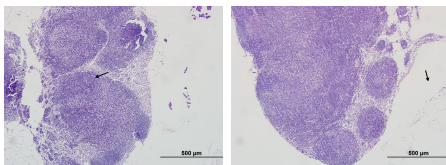
The mesenteric lymph nodes is small and depleted.

Morphological Diagnosis:

Distribution: Diffuse; **Severity:** moderate; **MPATH Diagnosis:** hypoplasia MPATH:133; **MPATH Process Term:** hypoplasia MPATH:133

Definitive Diagnosis:

Lymphoid hypoplasia



Mesenteric lymph node, lymphoid hypoplasia, 10x, HE Mesenteric lymph node, normal, 10x, HE

epididymis (MA:0000397)

Histopath Description:

There is focal granulomatous inflammation within the interstitium of the tail of the epididymis. Rare spermatozoa are present within the center of the inflammation.

Morphological Diagnosis:

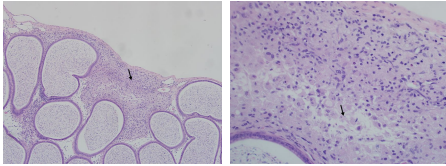
Distribution: focally extensive; **Severity:** mild; **MPATH Process Term:** inflammation MPATH:212

Definitive Diagnosis:

Granulomatous periepididymitis with intralesional spermatozoa (sperm granuloma)

Histopathology Comments:

Sperm granulomas are caused by leakage of spermatozoa into the interstitium following traumatic injury to the epididymal ducts or following blockage of ducts. The lesion is consistent with abnormal epididymal morphology observed on gross examination.



Tail of epididymis,
sperm granuloma,
10x, HE

Tail of epididymis,
sperm granuloma,
40x, HE

liver (MA:0000358)

Histopath Description:

diffuse lipidosis

Morphological Diagnosis:

Distribution: diffuse; **Severity:** extreme; **MPATH Diagnosis:** steatosis MPATH:622; **MPATH Process Term:** lipid deposition MPATH:42

Definitive Diagnosis:

hepatic steatosis

retina (MA:0000276)

Histopath Description:

There are multifocal retinal folds involving the outer nuclear layer

Morphological Diagnosis:

Distribution: multifocal; **Severity:** mild;

Definitive Diagnosis:

Retinal folding (dysplasia)

Organ/Tissue Analyzed:

Histopathology examination included the following organs and tissues: brain, trigeminal ganglion, eyes, salivary glands, trachea, lungs, heart, thymus, thyroid gland, parathyroid gland, exocrine and endocrine pancreas, oesophagus, stomach, small intestine, large intestine, liver, gall bladder, spleen, kidneys, adrenal gland, lymph nodes, spinal cord, bone marrow, sternum, femur and tibia with associated skeletal muscles, brown fat, pinna, skin, testis, epididymis, seminal vesicle, and prostate.

AnimalID: M00921320 (Male)

Tissue Preservation and Staining:

Mesenteric lymph node is not available for analysis

Histopathology Findings:

kidney (MA:0000368)

Histopath Description:

In one of the kidneys, the renal pelvis is markedly dilated and compressing the adjacent tubules.

Morphological Diagnosis:

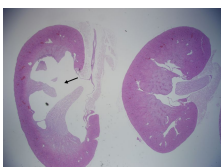
Duration: chronic; **Distribution:** unilateral; **Severity:** severe; **MPATH Diagnosis:** hydronephrosis MPATH:635;

Definitive Diagnosis:

hydronephrosis, moderate

Histopathology Comments:

The lesion was likely caused by obstructive lesion in the distal ureter; proximal ureter is unremarkable



Kidney,
hydronephrosis,
1.25x, HE

liver (MA:0000358)

Histopath Description:

diffuse lipidosis

Morphological Diagnosis:

Distribution: diffuse; **Severity:** extreme; **MPATH Diagnosis:** steatosis MPATH:622; **MPATH**

Process Term: lipid deposition MPATH:42

Definitive Diagnosis:
hepatic steatosis

Organ/Tissue Analyzed:

Histopathology examination included the following organs and tissues: brain, trigeminal ganglion, eyes, salivary glands, trachea, lungs, heart, thymus, thyroid gland, parathyroid gland, exocrine and endocrine pancreas, oesophagus, stomach, small intestine, large intestine, liver, gall bladder, spleen, kidneys, adrenal gland, lymph nodes, spinal cord, bone marrow, sternum, femur and tibia with associated skeletal muscles, brown fat, pinna, skin, testis, epididymis, seminal vesicle, and prostate.

AnimalID: M00926733 (Female)

Histopathology Findings:

lymph node (MA:0000139)

Histopath Description:

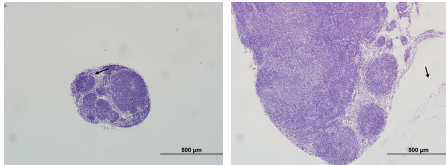
A very small piece of the mesenteric lymph nodes is available; it appears mildly depleted

Morphological Diagnosis:

Distribution: Diffuse; **Severity:** mild; **MPATH Diagnosis:** hypoplasia MPATH:133; **MPATH Process Term:** hypoplasia MPATH:133

Definitive Diagnosis:

Lymphoid hypoplasia



Mesenteric lymph node, lymphoid

hypoplasia, 10x, HE

Mesenteric lymph node, lnormal, 10x,

HE

liver (MA:0000358)

Histopath Description:

diffuse lipodosis

Morphological Diagnosis:

Distribution: diffuse; **Severity:** extreme; **MPATH Diagnosis:** steatosis MPATH:622; **MPATH Process Term:** lipid deposition MPATH:42

Definitive Diagnosis:

hepatic steatosis

spleen (MA:0000141)

Histopath Description:

mild erythroipoiesis

Morphological Diagnosis:

Distribution: multifocal to coalescing; **Severity:** moderate; **MPATH Diagnosis:** extramedullary hemopoiesis MPATH:595; **MPATH Process Term:** hyperplasia MPATH:134

Definitive Diagnosis:

mild erythroipoiesis

stomach (MA:0000353)

Histopath Description:

mild neutrophilic gastritis; there is also mild epithelial proteinosis

Morphological Diagnosis:

Distribution: multifocal; **Severity:** mild; **MPATH Process Term:** inflammation MPATH:212

Definitive Diagnosis:

Mild neutrophilic gastritis with epithelial proteinosis

Organ/Tissue Analyzed:

Histopathology examination included the following organs and tissues: brain, trigeminal ganglion, eyes,

salivary glands, trachea, lungs, heart, thymus, thyroid gland, parathyroid gland, exocrine and endocrine pancreas, oesophagus, stomach, small intestine, large intestine, liver, gall bladder, spleen, kidneys, adrenal gland, lymph nodes, spinal cord, bone marrow, sternum, femur and tibia with associated skeletal muscles, brown fat, pinna, skin, uterus, oviduct, and ovary, and mammary gland.

AnimalID: M00926732 (Female)

Histopathology Findings:

lymph node (MA:0000139)

Histopath Description:

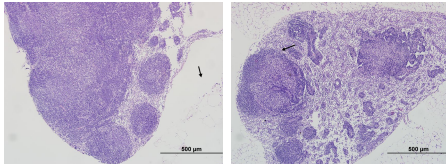
The mesenteric lymph nodes is small and depleted.

Morphological Diagnosis:

Distribution: Diffuse; **Severity:** moderate; **MPATH Diagnosis:** hypoplasia MPATH:133; **MPATH Process Term:** hypoplasia MPATH:133

Definitive Diagnosis:

Lymphoid hypoplasia



Mesenteric lymph node, normal, 10x, HE

Mesenteric lymph node, lymphoid hypoplasia, 10x, HE

liver (MA:0000358)

Histopath Description:

diffuse lipodosis

Morphological Diagnosis:

Distribution: diffuse; **Severity:** extreme; **MPATH Diagnosis:** steatosis MPATH:622; **MPATH Process Term:** lipid deposition MPATH:42

Definitive Diagnosis:

hepatic steatosis

Organ/Tissue Analyzed:

Histopathology examination included the following organs and tissues: brain, trigeminal ganglion, eyes, salivary glands, trachea, lungs, heart, thymus, thyroid gland, parathyroid gland, exocrine and endocrine pancreas, oesophagus, stomach, small intestine, large intestine, liver, gall bladder, spleen, kidneys, adrenal gland, lymph nodes, spinal cord, bone marrow, sternum, femur and tibia with associated skeletal muscles, brown fat, pinna, skin, uterus, oviduct, and ovary, and mammary gland.

Report Summary and Recommendation:

Lesion suggestive of lymphoid hypoplasia was noted in three mice. This finding should be interpreted with caution as it is based on a single section of a single lymph node. Systemic analysis of multiple lymph nodes is required to diagnose lymphoid hypoplasia with confidence.

The relationship between this finding and decreased NK cell number is not certain, although NK cells are known to reside and differentiate in the lymph nodes (Fehniger et al., 2003; Freud et al., 2005). There are no findings in the bone marrow and spleen to explain decreased granulocyte number.

Other lesions in this line are considered incidental and/or attributable to strain background.

Summary: Mesenteric lymph node - lymphoid hypoplasia (3/4)

References:

Fehniger TA, Cooper MA, Nuovo GJ, et al. CD56bright natural killer cells are present in human lymph nodes and are activated by T cell-derived IL-2: a potential new link between adaptive and innate immunity. *Blood*. 2003;101:3052-3057. Freud AG, Becknell B, Roychowdhury S, et al. A human CD34(+) subset resides in lymph nodes and differentiates into CD56bright natural killer cells. *Immunity*. 2005;22:295-304.