



# CMHD Pathology Report



## CMHD Pathology Core

Toronto Centre for  
Phenogenomics  
25 Orde St. 3rd fl.  
Toronto, Ont. M5T 3H7  
Tel.(416) 586-8375  
Fax (416) 586-5993

contact: Dr. Susan  
Newbigging  
email:  
[newbigging@lunenfeld.ca](mailto:newbigging@lunenfeld.ca)

## Principle Investigator: Dr. Jacqui White

Institute: Wellcome Trust Sanger Institute  
Address: Attn: Linda Read Wellcome Trust  
Genome Campus Hinxton Cambridge CB10  
1SA, UK

ReportID: Report Date: January 28, 2014  
Pathologist: Dr. H. Adissu

## Mouse Genetics Project

Wellcome Trust Sanger  
Institute  
Wellcome Trust Genome  
Campus  
Hinxton, Cambridge  
CB10 1SA  
UK

email:  
[MGPenquiries@sanger.ac.uk](mailto:MGPenquiries@sanger.ac.uk)  
[Mouse Portal](#)  
[Europhenome](#)

CMHD LabID: N13-912

## Relevant History:

Phenotype:

MP:0001325 abnormal retina morphology  
MP:0005103 abnormal retinal pigmentation  
MP:0010770 preweaning lethality  
MP:0008762 embryonic lethality

## AnimalID: M01102806 (Male)

### Histopathology Findings:

#### retina (MA:0000276)

##### Histopath Description:

There are clusters of external nuclear structures within the layer of rods and cons.

##### Morphological Diagnosis:

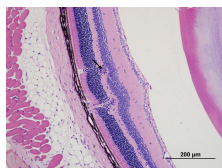
**Distribution:** Focal; **Severity:** mild; **MPATH Diagnosis:** developmental and structural abnormality MPATH:55; **MPATH Process Term:** developmental and structural abnormality MPATH:55

##### Definitive Diagnosis:

Retinal dysplasia

##### Histopathology Comments:

Retinal dysplasia is reported as a background lesion in C57BL/6N lines ( Mattapallil et al., 2012).



Retina, dysplasia,  
20x, HE

## Lymph node (MA:0000139)

##### Histopath Description:

The mesenteric lymph node is markedly enlarged (greater than four fold). The medulla is particularly expanded by chords and sheets of plasmotoid cells. There are prominent germinal centers within the medulla

##### Morphological Diagnosis:

**Distribution:** Diffuse; **Severity:** moderate; **MPATH Diagnosis:** hyperplasia MPATH:134;  
**MPATH Process Term:** hyperplasia MPATH:134

##### Definitive Diagnosis:

Lymphoid hyperplasia

##### Histopathology Comments:

The changes in the mesenteric lymph node are suggestive of draining of a regional inflammatory process. However, such a process was not observed in the tissues examined. Early marginal center lymphoma is suspected.

**brain (MA:0000168)****Histopath Description:**

There is moderate dilation of the fourth ventricle

**Morphological Diagnosis:**

**Distribution:** diffuse; **Severity:** moderate; **MPATH Process Term:** degenerative change  
MPATH:14

**Definitive Diagnosis:**

Dilation of the brain ventricles

**Histopathology Comments:**

Mild dilation of the ventricles is a background condition in mice of C57BL/6N background

**Organ/Tissue Analyzed:**

Histopathology examination included the following organs and tissues: brain, trigeminal ganglion, eyes, salivary glands, trachea, lungs, heart, thymus, thyroid gland, parathyroid gland, exocrine and endocrine pancreas, oesophagus, stomach, small intestine, large intestine, liver, gall bladder, spleen, kidneys, adrenal gland, lymph nodes, spinal cord, bone marrow, sternum, femur and tibia with associated skeletal muscles, brown fat, pinna, skin, testis, epididymis, seminal vesicle, and prostate.

---

**AnimalID: M01102832 (Male)****Histopathology Findings:****brain (MA:0000168)****Histopath Description:**

There is moderate dilation of the fourth ventricle

**Morphological Diagnosis:**

**Distribution:** diffuse; **Severity:** moderate; **MPATH Process Term:** degenerative change  
MPATH:14

**Definitive Diagnosis:**

Dilation of the brain ventricles

**Histopathology Comments:**

Mild dilation of the ventricles is a background condition in mice of C57BL/6N background

**lymph node (MA:0000139)****Histopath Description:**

The mesenteric lymph node is markedly enlarged (greater than four fold). The medulla is particularly expanded by chords and sheets of plasmotoid cells. There are prominent germinal centers within the medulla

**Morphological Diagnosis:**

**Distribution:** Diffuse; **Severity:** moderate; **MPATH Diagnosis:** hyperplasia MPATH:134;  
**MPATH Process Term:** hyperplasia MPATH:134

**Definitive Diagnosis:**

Lymphoid hyperplasia

**Histopathology Comments:**

The changes in the mesenteric lymph node are suggestive of draining of a regional inflammatory process. However, such a process was not observed in the tissues examined. Early marginal center lymphoma is suspected.

**Organ/Tissue Analyzed:**

Histopathology examination included the following organs and tissues: brain, trigeminal ganglion, eyes, salivary glands, trachea, lungs, heart, thymus, thyroid gland, parathyroid gland, exocrine and endocrine pancreas, oesophagus, stomach, small intestine, large intestine, liver, gall bladder, spleen, kidneys, adrenal gland, lymph nodes, spinal cord, bone marrow, sternum, femur and tibia with associated skeletal muscles, brown fat, pinna, skin, testis, epididymis, seminal vesicle, and prostate.

---

**AnimalID: M01102838 (Female)****Histopathology Findings:****brain (MA:0000168)****Histopath Description:**

There is mild dilation of the fourth ventricle

**Morphological Diagnosis:****Severity:** mild; **MPATH Process Term:** degenerative change MPATH:14**Definitive Diagnosis:**

Dilation of the brain ventricles

**Histopathology Comments:**

Mild dilation of the ventricles is a background condition in mice of C57BL/6N background

**lymph node (MA:0000139)****Histopath Description:**

The mesenteric lymph node is markedly enlarged (greater than four fold). The medulla is particularly expanded by chords and sheets of plasmotoid cells. There are prominent germinal centers within the medulla

**Morphological Diagnosis:****Distribution:** Diffuse; **Severity:** moderate; **MPATH Diagnosis:** hyperplasia MPATH:134;  
**MPATH Process Term:** hyperplasia MPATH:134**Definitive Diagnosis:**

Lymphoid hyperplasia

**Histopathology Comments:**

The changes in the mesenteric lymph node are suggestive of draining of a regional inflammatory process. However, such a process was not observed in the tissues examined. Early marginal center lymphoma is suspected.

**Organ/Tissue Analyzed:**

Histopathology examination included the following organs and tissues: brain, trigeminal ganglion, eyes, salivary glands, trachea, lungs, heart, thymus, thyroid gland, parathyroid gland, exocrine and endocrine pancreas, oesophagus, stomach, small intestine, large intestine, liver, gall bladder, spleen, kidneys, adrenal gland, lymph nodes, spinal cord, bone marrow, sternum, femur and tibia with associated skeletal muscles, brown fat, pinna, skin, uterus, oviduct, and ovary, and mammary gland.

---

**AnimalID: M01102807 (Female)****Histopathology Findings:****retina (MA:0000276)****Histopath Description:**

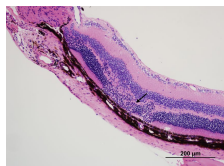
There are multifocal clusters of external nuclear structures within the layer of rods and cons.

**Morphological Diagnosis:****Distribution:** Focal; **Severity:** mild; **MPATH Diagnosis:** developmental and structural abnormality MPATH:55; **MPATH Process Term:** developmental and structural abnormality MPATH:55**Definitive Diagnosis:**

Retinal dysplasia

**Histopathology Comments:**

Retinal dysplasia is reported as a background lesion in C57BL/6N lines ( Mattapallil et al., 2012).



Retina, dysplasia,  
20x, HE

**brain (MA:0000168)****Histopath Description:**

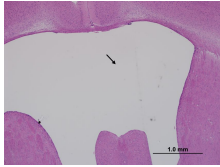
There is marked dilation of the lateral and third ventricles. The periventricular neuropil is vacuolated and rarefied and contains occasional swollen microglia

**Morphological Diagnosis:****Distribution:** diffuse; **Severity:** severe; **MPATH Diagnosis:** hydrocephalus MPATH:639;  
**MPATH Process Term:** degenerative change MPATH:14**Definitive Diagnosis:**

Hydrocephalus, triventricular

**Histopathology Comments:**

Hydrocephalus is seen as a background condition in mice of C57BL/6N background



Brain, laterl  
ventricles,  
hydrocephalus, 4x,  
HE

#### lymph node (MA:0000139)

##### Histopath Description:

The mesenteric lymph node is markedly enlarged (greater than four fold). The medulla is particularly expanded by chords and sheets of plasmotoid cells. There are promient germinal centers within the medulla

##### Morphological Diagnosis:

**Distribution:** Diffuse; **Severity:** moderate; **MPATH Diagnosis:** hyperplasia MPATH:134;  
**MPATH Process Term:** hyperplasia MPATH:134

##### Definitive Diagnosis:

Lymphoid hyperplasia

##### Histopathology Comments:

The changes in the mesenteric lymph node are suggestive of draining of a regional inflammatory process. However, such a process was not observed in the tissues examined. Early maginal center lymphoma is suspected.

#### parathyroid gland (MA:0000128)

##### Histopath Description:

The parathyroid gland is partially replaced by a lymphoid tissue reminiscent of thymic tissue.

##### Morphological Diagnosis:

**Distribution:** multifocal; **MPATH Process Term:** developmental and structural abnormality  
MPATH:55

##### Definitive Diagnosis:

Ectopic thymic tissue

##### Histopathology Comments:

incidental

#### Organ/Tissue Analyzed:

Histopathology examination included the following organs and tissues: brain, trigeminal ganglion, eyes, salivary glands, trachea, lungs, heart, thymus, thyroid gland, parathyroid gland, exocrine and endocrine pancreas, oesophagus, stomach, small intestine, large intestine, liver, gall bladder, spleen, kidneys, adrenal gland, lymph nodes, spinal cord, bone marrow, sternum, femur and tibia with associated skeletal muscles, brown fat, pinna, skin, uterus, oviduct, and ovary, and mammary gland.

#### Report Summary and Recommendation:

Mild dysplastic retinal lesions are present in two mice. The lesion may explain the abnormal retinal pigmentation/morphology documnted in clinical phenotyping. However, this finding should be cautiously interpreted in light of the high prevalence of similar lesions in this strain (C57BL/6N). Lymphoid hyperplasia was observed in all mice. Lymph node hyperplasia could also be seen in wildtype mice albeit at low pevalence (5-15% in various B6 WT strains we have analyzed). Hence this finding should be interpreted with caution.

We did not find lesions to explain preweaning and embryonic lethality in homozygotes. Analysis of homozygous embryos and preweaning pups may explain cause mortality. Other lesions are considered incidental.

##### Line summary:

Eye - retinal dysplasia (2/4)

Mesenetric lymph node: Lymphoid hyperplasia (4/4)