



# CMHD Pathology Report



## CMHD Pathology Core

Toronto Centre for  
Phenogenomics  
25 Orde St. 3rd fl.  
Toronto, Ont. M5T 3H7  
Tel.(416) 586-8375  
Fax (416) 586-5993

contact: Dr. Susan  
Newbigging  
email:  
[newbigging@lunenfeld.ca](mailto:newbigging@lunenfeld.ca)

## Principle Investigator: Dr. Jacqui White

Institute: Wellcome Trust Sanger Institute  
Address: Attn: Linda Read Wellcome Trust  
Genome Campus Hinxton Cambridge CB10  
1SA, UK

ReportID: Report Date: January 09, 2014  
Pathologist: Dr. H. Adissu

## Mouse Genetics Project

Wellcome Trust Sanger  
Institute  
Wellcome Trust Genome  
Campus  
Hinxton, Cambridge  
CB10 1SA  
UK

email:  
[MGPenquiries@sanger.ac.uk](mailto:MGPenquiries@sanger.ac.uk)  
[Mouse Portal](#)  
[Europhenome](#)

CMHD LabID: N13-712

## Relevant History:

Phenotypes

Heterozygotes: chromosomal instability

Homozygotes: preweaning lethality

## AnimalID: M00982402 (Male)

### Histopathology Findings:

#### brain (MA:0000168)

##### Histopath Description:

There is mild dilation of the lateral ventricles

##### Morphological Diagnosis:

**Distribution:** bilateral; **Severity:** mild; **MPATH Process Term:** degenerative change MPATH:14

##### Definitive Diagnosis:

Dilation of the brain ventricles

##### Histopathology Comments:

Mild dilation of the lateral ventricles is a background condition in mice of C57BL/6N background (Brayton et al., 2004).

#### eye (MA:0000261)

##### Histopath Description:

There is mild retinal fold at the posterior aspect

##### Morphological Diagnosis:

**Distribution:** focally extensive; **Severity:** mild; **MPATH Process Term:** developmental dysplasia MPATH:64

##### Definitive Diagnosis:

Retinal dysplasia

#### heart (MA:0000072)

##### Histopath Description:

There is a focally extensive inflammatory infiltrate within the epicardial aspect of the right ventricle composed of lymphocytes, macrophages and rare neutrophils; low grade fibrosis is also present.

##### Morphological Diagnosis:

**Distribution:** focally extensive; **Severity:** mild; **MPATH Diagnosis:** inflammation MPATH:212; **MPATH Process Term:** inflammation MPATH:212

##### Definitive Diagnosis:

Epicarditis, right ventricle

#### sternum (MA:0001331)

##### Histopath Description:

There is a full thickness fissure (fracture) within the sternal cartilage accompanied by necrotic

chromatin smear and multifocal degeneration and necrosis of the sternal cartilage. Within the adjacent soft tissue is focally extensive mild infiltration of neutrophils and mononuclear inflammatory cells accompanied by hemorrhage and fibroplasia. There is marked nodular hyperplasia of the cartilage tissue surrounding the fracture

**Morphological Diagnosis:**

**Distribution:** focally extensive; **Severity:** mild; **MPATH Diagnosis:** inflammation MPATH:212;  
**MPATH Process Term:** inflammation MPATH:212

**Definitive Diagnosis:**

Sternal osteoarthritis with sternal fracture with hemorrhage and fibroplasia

**Histopathology Comments:**

lesion was likely secondary to the sternal lesion (see above).

**testis (MA:0000411)**

**Histopath Description:**

Multifocally seminiferous tubules are dilated and there is minimal spermiogenesis in these dilated tubules

**Morphological Diagnosis:**

**Distribution:** multifocal; **Severity:** moderate; **MPATH Process Term:** degenerative change MPATH:14

**Definitive Diagnosis:**

Seminiferous dilation with minimal spermiogenesis

**Organ/Tissue Analyzed:**

Histopathology examination included the following organs and tissues: brain, trigeminal ganglion, eyes, salivary glands, trachea, lungs, heart, thymus, thyroid gland, parathyroid gland, exocrine and endocrine pancreas, oesophagus, stomach, small intestine, large intestine, liver, gall bladder, spleen, kidneys, adrenal gland, lymph nodes, spinal cord, bone marrow, sternum, femur and tibia with associated skeletal muscles, brown fat, pinna, skin, testis, epididymis, seminal vesicle, and prostate.

**AnimalID: M00982400 (Male)**

**Histopathology Findings:**

**lymph node (MA:0000139)**

**Histopath Description:**

The mesenteric lymph node is markedly enlarged (greater than four fold). The medulla is particularly expanded by chords and sheets of plasmotoid cells. There are prominent germinal centers within the medulla

**Morphological Diagnosis:**

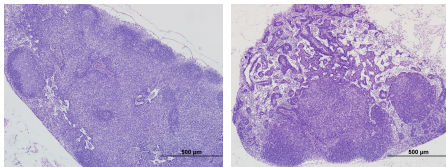
**Distribution:** Diffuse; **Severity:** moderate; **MPATH Diagnosis:** hyperplasia MPATH:134;  
**MPATH Process Term:** hyperplasia MPATH:134

**Definitive Diagnosis:**

Lymphoid hyperplasia

**Histopathology Comments:**

The changes in the mesenteric lymph node are suggestive of draining of a regional inflammatory process. However, such a process was not observed in the tissues examined. Early marginal center lymphoma is suspected.



Lymph node,  
hyperplasia, 10x,  
HE

Lymph node,  
normal, 10x, HE

**brain (MA:0000168)**

**Histopath Description:**

There is mild dilation of the lateral ventricles

**Morphological Diagnosis:**

**Distribution:** bilateral; **Severity:** mild; **MPATH Process Term:** degenerative change MPATH:14

**Definitive Diagnosis:**

Dilation of the brain ventricles

**Histopathology Comments:**

Mild dilation of the lateral ventricles is a background condition in mice of C57BL/6N background (Brayton et al., 2004).

### eye (MA:0000261)

#### Histopath Description:

There is mild retinal fold at the posterior aspect

#### Morphological Diagnosis:

**Distribution:** focally extensive; **Severity:** mild; **MPATH Process Term:** developmental dysplasia MPATH:64

#### Definitive Diagnosis:

Retinal dysplasia

### liver (MA:0000358)

#### Histopath Description:

Rare perivascular mononuclear inflammatory aggregates are present

#### Morphological Diagnosis:

**Duration:** chronic; **Distribution:** multifocal; **Severity:** mild; **MPATH Process Term:** inflammation MPATH:212

#### Definitive Diagnosis:

Perivascular inflammatory infiltrates

### Organ/Tissue Analyzed:

Histopathology examination included the following organs and tissues: brain, trigeminal ganglion, eyes, salivary glands, trachea, lungs, heart, thymus, thyroid gland, parathyroid gland, exocrine and endocrine pancreas, oesophagus, stomach, small intestine, large intestine, liver, gall bladder, spleen, kidneys, adrenal gland, lymph nodes, spinal cord, bone marrow, sternum, femur and tibia with associated skeletal muscles, brown fat, pinna, skin, testis, epididymis, seminal vesicle, and prostate.

### AnimalID: M00982952 (Female)

#### Histopathology Findings:

##### lymph node (MA:0000139)

#### Histopath Description:

The mesenteric lymph node is markedly enlarged (greater than four fold). The medulla is particularly expanded by chords and sheets of plasmotoid cells. There are prominent germinal centers within the medulla

#### Morphological Diagnosis:

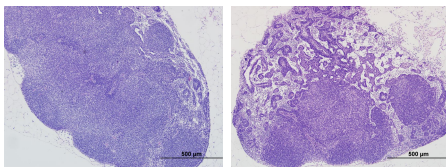
**Distribution:** Diffuse; **Severity:** moderate; **MPATH Diagnosis:** hyperplasia MPATH:134; **MPATH Process Term:** hyperplasia MPATH:134

#### Definitive Diagnosis:

Lymphoid hyperplasia

#### Histopathology Comments:

The changes in the mesenteric lymph node are suggestive of draining of a regional inflammatory process. However, such a process was not observed in the tissues examined. Early maginal center lymphoma is suspected.



Lymph node,  
hyperplasia, 10x,  
HE

Lymph node,  
normal, 10x, HE

### adrenal gland (MA:0000116)

#### Histopath Description:

There is a small, well-circumscribed mass in the cortex. It is encapsulated by a thin layer of pale eosinophilic material and fusiform cells (connective tissue with fibroblasts) and is made of nests of polygonal cells interspersed by a very thin fibrovascular membrane. The architecture is reminiscent of the zona glomerulosa and zona fasciculata of the mature adrenal gland.

#### Morphological Diagnosis:

**Distribution:** focal; **MPATH Process Term:** developmental and structural abnormality

MPATH:55

**Definitive Diagnosis:**

accessory adrenal cortical tissue

**Histopathology Comments:**

This is a common developmental abnormality.

**stomach (MA:0000353)**

**Histopath Description:**

mild neutrophilic gastritis; there is also mild epithelial proteinosis

**Morphological Diagnosis:**

**Distribution:** multifocal; **Severity:** mild; **MPATH Process Term:** inflammation MPATH:212

**Definitive Diagnosis:**

Mild neutrophilic gastritis with epithelial proteinosis

**retina (MA:0000276)**

**Histopath Description:**

Involving one eye, there are clusters of external nuclear structures within the internal and outer plexiform layer.

**Morphological Diagnosis:**

**Distribution:** Focal; **Severity:** mild; **MPATH Process Term:** developmental dysplasia MPATH:64

**Definitive Diagnosis:**

Retinal dysplasia

**brain (MA:0000168)**

**Histopath Description:**

There is mild dilation of the fourth ventricle

**Morphological Diagnosis:**

**Severity:** mild; **MPATH Process Term:** degenerative change MPATH:14

**Definitive Diagnosis:**

Dilation of the brain ventricles

**Histopathology Comments:**

Mild dilation of the ventricles is a background condition in mice of C57BL/6N background

**Organ/Tissue Analyzed:**

Histopathology examination included the following organs and tissues: brain, trigeminal ganglion, eyes, salivary glands, trachea, lungs, heart, thymus, thyroid gland, parathyroid gland, exocrine and endocrine pancreas, oesophagus, stomach, small intestine, large intestine, liver, gall bladder, spleen, kidneys, adrenal gland, lymph nodes, spinal cord, bone marrow, sternum, femur and tibia with associated skeletal muscles, brown fat, pinna, skin, uterus, oviduct, and ovary, and mammary gland.

---

**AnimalID: M00982403 (Female)**

**Histopathology Findings:**

**lymph node (MA:0000139)**

**Histopath Description:**

The mesenteric lymph node is markedly enlarged (greater than four fold). The medulla is particularly expanded by chords and sheets of plasmotoid cells. There are prominent germinal centers within the medulla

**Morphological Diagnosis:**

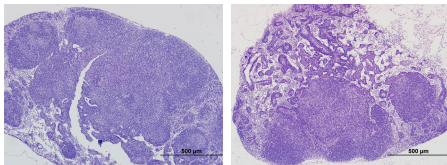
**Distribution:** Diffuse; **Severity:** moderate; **MPATH Diagnosis:** hyperplasia MPATH:134;  
**MPATH Process Term:** hyperplasia MPATH:134

**Definitive Diagnosis:**

Lymphoid hyperplasia

**Histopathology Comments:**

The changes in the mesenteric lymph node are suggestive of draining of a regional inflammatory process. However, such a process was not observed in the tissues examined. Early maginal center lymphoma is suspected.



Lymph node,  
hyperplasia, 10x,  
HE

Lymph node,  
normal, 10x, HE

### **liver (MA:0000358)**

#### **Histopath Description:**

Rare perivascular mononuclear inflammatory aggregates are present

#### **Morphological Diagnosis:**

**Duration:** chronic; **Distribution:** multifocal; **Severity:** mild; **MPATH Process Term:** inflammation MPATH:212

#### **Definitive Diagnosis:**

Perivascular inflammatory infiltrates

### **Organ/Tissue Analyzed:**

Histopathology examination included the following organs and tissues: brain, trigeminal ganglion, eyes, salivary glands, trachea, lungs, heart, thymus, thyroid gland, parathyroid gland, exocrine and endocrine pancreas, oesophagus, stomach, small intestine, large intestine, liver, gall bladder, spleen, kidneys, adrenal gland, lymph nodes, spinal cord, bone marrow, sternum, femur and tibia with associated skeletal muscles, brown fat, pinna, skin, uterus, oviduct, and ovary, and mammary gland.

### **Report Summary and Recommendation:**

Mesenteric lymph node hyperplasia was observed in three mice. Lymph node hyperplasia could also be seen in wildtype mice albeit at low prevalence (5-15% in various B6 WT strains we have analyzed). Hence this finding should be interpreted with caution. No morphological abnormalities were detected to predict preweaning lethality in homozygotes. Analysis of homozygous preweaning mice is recommended. Other lesions are incidental and are attributable to strain background.

Line summary: Lymph node (mesenteric) - lymphoid hyperplasia (3/4)