



CMHD Pathology Report



CMHD Pathology Core

Toronto Centre for
Phenogenomics
25 Orde St. 3rd fl.
Toronto, Ont. M5T 3H7
Tel.(416) 586-8375
Fax (416) 586-5993

contact: Dr. Susan
Newbigging
email:
newbigging@lunenfeld.ca

Principle Investigator: Dr. Jacqui White

Institute: Wellcome Trust Sanger Institute
Address: Attn: Linda Read Wellcome Trust
Genome Campus Hinxton Cambridge CB10
1SA, UK

ReportID: Report Date: not completed
Pathologist: Dr. H. Adissu

Mouse Genetics Project

Wellcome Trust Sanger
Institute
Wellcome Trust Genome
Campus
Hinxton, Cambridge
CB10 1SA
UK

email:
MGPenquiries@sanger.ac.uk
[Mouse Portal](#)
[Europhenome](#)

CMHD LabID: N13-914

Relevant History:

Phenotypes:
hypoalbuminemia
decreased circulating fructosamine level

AnimalID: M01012207 (Male)

Tissue Preservation and Staining:

A very small piece of kidney tissue was available for histopathology examination (considered non diagnostic).

Histopathology Findings:

brain (MA:0000168)

Histopath Description:

There is moderate dilation of the fourth ventricle

Morphological Diagnosis:

Distribution: diffuse; **Severity:** moderate; **MPATH Process Term:** degenerative change
MPATH:14

Definitive Diagnosis:

Dilation of the brain ventricles

Histopathology Comments:

Mild dilation of the ventricles is a background condition in mice of C57BL/6N background

Organ/Tissue Analyzed:

Histopathology examination included the following organs and tissues: brain, trigeminal ganglion, eyes, salivary glands, trachea, lungs, heart, thymus, thyroid gland, parathyroid gland, exocrine and endocrine pancreas, oesophagus, stomach, small intestine, large intestine, liver, gall bladder, spleen, kidneys, adrenal gland, lymph nodes, spinal cord, bone marrow, sternum, femur and tibia with associated skeletal muscles, brown fat, pinna, skin, testis, epididymis, seminal vesicle, and prostate.

AnimalID: M01012209 (Male)

Histopathology Findings:

aorta (MA:0000062)

Histopath Description:

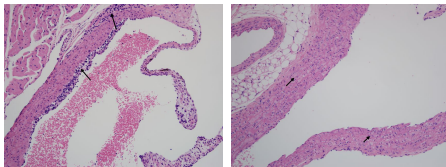
focally extensive proliferative and lymphocytic inflammation affecting the intima and inner media

Morphological Diagnosis:

Distribution: focally extensive; **Severity:** moderate; **MPATH Diagnosis:** vasculitis MPATH:201;
MPATH Process Term: inflammation MPATH:212

Definitive Diagnosis:

Proliferative and lymphocytic aortitis



Aorta, vasculitis,
20x, HE

Aorta, normal, 20x,
HE

kidney (MA:0000368)

Histopath Description:

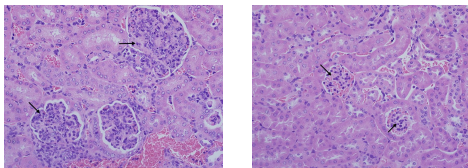
Severe generalized proliferative and membranous glomerulopathy with occasional nuclear fragments (necrosis) within the mesangium. There are occasional protein casts in collecting ducts

Morphological Diagnosis:

Distribution: generalized; **Severity:** extreme; **MPATH Diagnosis:** glomerulonephritis MPATH:197; **MPATH Process Term:** degenerative change MPATH:14

Definitive Diagnosis:

Membranoproliferative glomerulopathy



Kidney,
membranoproliferative
glomerulopathy, 40x,
HE

Kidney, glomeruli,
normal, 40x, HE

testis (MA:0000411)

Histopath Description:

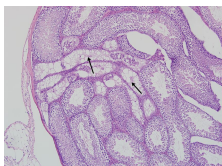
Nearly 10% of the seminiferous tubules in one of the testis are atrophic and vacuolated.

Morphological Diagnosis:

Distribution: multifocal; **Severity:** mild; **MPATH Process Term:** atrophy MPATH:127

Definitive Diagnosis:

Seminiferous tubule atrophy



Testis, multifocal
seminiferous
atrophy, 10x, HE

brain (MA:0000168)

Histopath Description:

There is moderate dilation of the fourth ventricle

Morphological Diagnosis:

Distribution: diffuse; **Severity:** moderate; **MPATH Process Term:** degenerative change MPATH:14

Definitive Diagnosis:

Dilation of the brain ventricles

Histopathology Comments:

Mild dilation of the ventricles is a background condition in mice of C57BL/6N background

salivary gland (MA:0000346)

Histopath Description:

There are multifocal perivascular mononuclear inflammatory cell aggregates.

Morphological Diagnosis:

Distribution: multifocal; **Severity:** mild; **MPATH Process Term:** inflammation MPATH:212

Definitive Diagnosis:

Interstitial inflammatory aggregates

Organ/Tissue Analyzed:

Histopathology examination included the following organs and tissues: brain, trigeminal ganglion, eyes, salivary glands, trachea, lungs, heart, thymus, thyroid gland, parathyroid gland, exocrine and endocrine pancreas, oesophagus, stomach, small intestine, large intestine, liver, gall bladder, spleen, kidneys, adrenal gland, lymph nodes, spinal cord, bone marrow, sternum, femur and tibia with associated skeletal muscles, brown fat, pinna, skin, testis, epididymis, seminal vesicle, and prostate.

AnimalID: M01038642 (Female)**Histopathology Findings:****aorta (MA:0000062)****Histopath Description:**

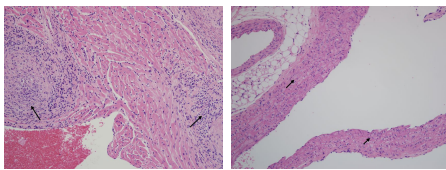
focally extensive proliferative and lymphocytic inflammation affecting the intima and inner media

Morphological Diagnosis:

Distribution: focally extensive; **Severity:** moderate; **MPATH Diagnosis:** vasculitis MPATH:201;
MPATH Process Term: inflammation MPATH:212

Definitive Diagnosis:

Proliferative and lymphocytic aortitis



Heart, blood vessels, vasculitis, 20x, HE. Aorta, WT, normal, 20x, HE.

mesenteric artery (MA:0002003)**Histopath Description:**

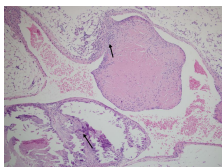
Vasculitis and mineralization

Morphological Diagnosis:

Distribution: multifocal; **Severity:** moderate; **MPATH Diagnosis:** vasculitis MPATH:201;
MPATH Process Term: infarction MPATH:124

Definitive Diagnosis:

Mesenteric vasculitis with thrombosis and mineralization



Mesenteric vessels, vasculitis with thrombosis and mineralization, 10x, HE

kidney (MA:0000368)**Histopath Description:**

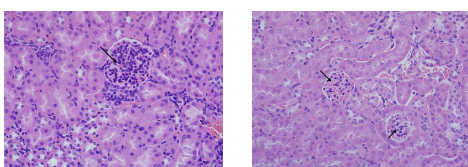
Mild generalized membranoproliferative glomerulopathy

Morphological Diagnosis:

Distribution: generalized; **Severity:** mild; **MPATH Diagnosis:** glomerulonephritis MPATH:197;
MPATH Process Term: degenerative change MPATH:14

Definitive Diagnosis:

Proliferative glomerulopathy



Kidney, membranoproliferative glomerulopathy, 40x, HE. Kidney, WT. glomeruli, normal, 40x, HE.

salivary gland (MA:0000346)**Histopath Description:**

There are multifocal perivascular mononuclear inflammatory cell aggregates.

Morphological Diagnosis:

Distribution: multifocal; **Severity:** mild; **MPATH Process Term:** inflammation MPATH:212

Definitive Diagnosis:

Interstitial inflammatory aggregates

brain (MA:0000168)**Histopath Description:**

There is moderate dilation of the fourth ventricle

Morphological Diagnosis:

Distribution: diffuse; **Severity:** moderate; **MPATH Process Term:** degenerative change MPATH:14

Definitive Diagnosis:

Dilation of the brain ventricles

Histopathology Comments:

Mild dilation of the ventricles is a background condition in mice of C57BL/6N background

lymph node (MA:0000139)**Histopath Description:**

The mesenteric lymph nodes is small and depleted.

Morphological Diagnosis:

Distribution: Diffuse; **Severity:** moderate; **MPATH Diagnosis:** hypoplasia MPATH:133; **MPATH Process Term:** hypoplasia MPATH:133

Definitive Diagnosis:

Lymphoid hypoplasia

Organ/Tissue Analyzed:

Histopathology examination included the following organs and tissues: brain, trigeminal ganglion, eyes, salivary glands, trachea, lungs, heart, thymus, thyroid gland, parathyroid gland, exocrine and endocrine pancreas, oesophagus, stomach, small intestine, large intestine, liver, gall bladder, spleen, kidneys, adrenal gland, lymph nodes, spinal cord, bone marrow, sternum, femur and tibia with associated skeletal muscles, brown fat, pinna, skin, uterus, oviduct, and ovary, and mammary gland.

AnimalID: M01038637 (Female)**Histopathology Findings:****aorta (MA:0000062)****Histopath Description:**

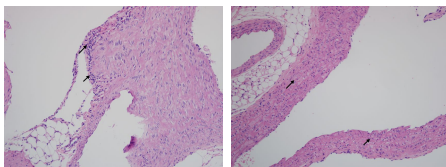
focally extensive proliferative and lymphocytic inflammation affecting the intima and inner media

Morphological Diagnosis:

Distribution: focally extensive; **Severity:** moderate; **MPATH Diagnosis:** vasculitis MPATH:201; **MPATH Process Term:** inflammation MPATH:212

Definitive Diagnosis:

Poliferative and lymphocytic aortitis



Aorta, vasculitis,
20x, HE

Aorta, WT, normal,
20x, HE.

mesenteric artery (MA:0002003)**Histopath Description:**

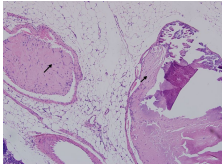
Vasculitis and mineralization

Morphological Diagnosis:

Distribution: multifocal; **Severity:** moderate; **MPATH Diagnosis:** vasculitis MPATH:201; **MPATH Process Term:** infarction MPATH:124

Definitive Diagnosis:

Mesenteric vasculitis with mineralization



Mesenteric vessels,
vasculitis with
thrombosis and
mineralization, 10x,
HE

pancreas (MA:0000120)**Histopath Description:**

Focal vasculitis

Morphological Diagnosis:**MPATH Diagnosis:** vasculitis MPATH:201; **MPATH Process Term:** inflammation MPATH:212**Definitive Diagnosis:**

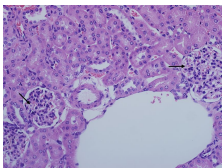
Vasculitis, interlobular arteriole

kidney (MA:0000368)**Histopath Description:**

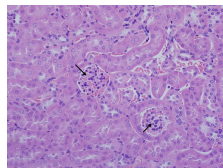
Mild generalized membranoproliferative glomerulopathy

Morphological Diagnosis:**Distribution:** generalized; **Severity:** mild; **MPATH Diagnosis:** glomerulonephritis MPATH:197; **MPATH Process Term:** degenerative change MPATH:14**Definitive Diagnosis:**

Proliferative glomerulopathy



Kidney,
membranoproliferative
glomerulopathy, 40x,
HE



Kidney, glomeruli,
normal, 40x, HE

lymph node (MA:0000139)**Histopath Description:**

Overall, the mesenteric lymph node is distinctly basophilic. Its architecture is disrupted by diffuse sheets of monotypic round cells that distended the subcapsular, medullary and occasional transverse sinuses. The cells have scant or no visible cytoplasm, round nuclei with stippled chromatin and a central distinct nucleolus (interpreted as lymphocytes). Rare apoptotic bodies and mitotic figures are present within occasional germinal centers.

Morphological Diagnosis:**MPATH Diagnosis:** lymphoid neoplasms MPATH:513; **MPATH Process Term:** neoplasia MPATH:218**Definitive Diagnosis:**

Lymphoma

Histopathology Comments:

The presence of diffuse sheets of monomorphic lymphocytes within the sinuses is suggestive of lymphoma. Note all mice in this line have mesenteric lymphoma.

brain (MA:0000168)**Histopath Description:**

There is moderate dilation of the fourth ventricle

Morphological Diagnosis:**Distribution:** diffuse; **Severity:** moderate; **MPATH Process Term:** degenerative change MPATH:14**Definitive Diagnosis:**

Dilation of the brain ventricles

Histopathology Comments:

Mild dilation of the ventricles is a background condition in mice of C57BL/6N background

Organ/Tissue Analyzed:

Histopathology examination included the following organs and tissues: brain, trigeminal ganglion, eyes, salivary glands, trachea, lungs, heart, thymus, thyroid gland, parathyroid gland, exocrine and endocrine pancreas, oesophagus, stomach, small intestine, large intestine, liver, gall bladder, spleen, kidneys, adrenal gland, lymph nodes, spinal cord, bone marrow, sternum, femur and tibia with associated skeletal muscles, brown fat, pinna, skin, uterus, oviduct, and ovary, and mammary gland.

Report Summary and Recommendation:

Three of the mice in these line have inflammation of the blood vessels (vasculitis) targeting the aorta and/or the mesenteric and the pancreatic arteries. Two of these mice have proliferative glomerulopathy with tubular protein casts (interpreted as proteinuria). We speculate that the glomerular changes are secondary to inflammatory changes within the blood vessels. Similar glomerular lesions are caused by deposition of immune complexes in the glomeruli secondary to immune mediated vasculitis in humans and animals including mice (example lupus mouse). Selective hypoalbuminemia (with normal level of globulin) is highly suggestive of glomerular disease as is the case in this line. Fructosamine level could decrease due to increased plasma protein turnover. Hence, hypoproteinemia or hypoalbuminemia may result in decreased fructosamine levels.

Vasculitis (polyarteritis) has been documented in aged C57B6 mice (Andrews et al., 1994; Zucher et al., 1982). In aged C57BL/6J mice (maintained until their maximum age of 31 months), arteritis (polyarteritis) was one of the most common non neoplastic findings with 36% of females and 16% of the males affected (Zurcher et al. 1982). We have this condition at extremely low incidence (less than 0.5%) in C57B6/N mice as an early onset (16 weeks of age). However, the presence of this condition in 3/4 mice in this line as an early onset suggests a gene effect.

Line summary:

Blood vessels: arteritis/polyarteritis (3/4)

Kidney: Membranoproliferative glomerulopathy (3/4)

Testis: Seminiferous tubule atrophy (1/2)

References:

Andrews, A.G., et al. 1994. Immune complex vasculitis with secondary ulcerative dermatitis in aged C57BL/6N mice. *Vet Pathol.* 31(3):293-300. Zurcher, C., van Zweiten, M., et al. (1982). Aging research. In *The mouse in biomedical research: experimental biology and oncology* (H. L. Foster, J. D. Small, and J. G. Fox eds.), IV, pp. 11-35. Academic Press, New York.