



CMHD Pathology Report



CMHD Pathology Core

Toronto Centre for
Phenogenomics
25 Orde St. 3rd fl.
Toronto, Ont. M5T 3H7
Tel.(416) 586-8375
Fax (416) 586-5993

contact: Dr. Susan
Newbigging
email:
newbigging@lunenfeld.ca

Principle Investigator: Dr. Jacqui White

Institute: Wellcome Trust Sanger Institute
Address: Attn: Linda Read Wellcome Trust
Genome Campus Hinxton Cambridge CB10
1SA, UK

ReportID: Report Date: January 28, 2014
Pathologist: Dr. H. Adissu

Mouse Genetics Project

Wellcome Trust Sanger
Institute
Wellcome Trust Genome
Campus
Hinxton, Cambridge
CB10 1SA
UK

email:
MGPenquiries@sanger.ac.uk
[Mouse Portal](#)
[Europhenome](#)

CMHD LabID: N13-911

Relevant History:

Phenotypes:

Weight Curves MP:0001262 decreased body weight
Body Composition (DEXA) MP:0001258 decreased body length
MP:0003961 decreased lean body mass
X-ray Imaging MP:0002932 abnormal joint morphology
MPATH:684 arthropathy
MP:0004509 abnormal pelvic girdle bone morphology
Auditory Brainstem Response MP:0004738 abnormal brainstem auditory evoked potential
Homozygous viability at P14 MP:0010831 partial lethality

AnimalID: M01274660 (Male)

Organ/Tissue Analyzed:

Histopathology examination included the following organs and tissues: brain, trigeminal ganglion, eyes, salivary glands, trachea, lungs, heart, thymus, thyroid gland, parathyroid gland, exocrine and endocrine pancreas, oesophagus, stomach, small intestine, large intestine, liver, gall bladder, spleen, kidneys, adrenal gland, lymph nodes, spinal cord, bone marrow, sternum, femur and tibia with associated skeletal muscles, brown fat, pinna, skin, testis, epididymis, seminal vesicle, and prostate.

AnimalID: M01252756 (Male)

Histopathology Findings:

lung (MA:0000415)

Histopath Description:

Focal prominent peribronchiolar chronic inflammatory aggregate

Morphological Diagnosis:

Duration: chronic; **Distribution:** multifocal; **Severity:** mild; **MPATH Process Term:** inflammation MPATH:212

Definitive Diagnosis:

Peribronchiolar inflammatory aggregate

Organ/Tissue Analyzed:

Histopathology examination included the following organs and tissues: brain, trigeminal ganglion, eyes, salivary glands, trachea, lungs, heart, thymus, thyroid gland, parathyroid gland, exocrine and endocrine pancreas, oesophagus, stomach, small intestine, large intestine, liver, gall bladder, spleen, kidneys, adrenal gland, lymph nodes, spinal cord, bone marrow, sternum, femur and tibia with associated skeletal muscles, brown fat, pinna, skin, testis, epididymis, seminal vesicle, and prostate.

AnimalID: M01252757 (Female)

Histopathology Findings:

adrenal gland (MA:0000116)

Histopath Description:

There is a small, well-circumscribed mass in the cortex. It is encapsulated by a thin layer of pale eosinophilic material and fusiform cells (connective tissue with fibroblasts) and is made of nests of polygonal cells interspersed by a very thin fibrovascular membrane. The architecture is reminiscent of the zona glomerulosa and zona fasciculata of the mature adrenal gland.

Morphological Diagnosis:

Distribution: focal; **MPATH Process Term:** developmental and structural abnormality
MPATH:55

Definitive Diagnosis:

accessory adrenal cortical tissue

Organ/Tissue Analyzed:

Histopathology examination included the following organs and tissues: brain, trigeminal ganglion, eyes, salivary glands, trachea, lungs, heart, thymus, thyroid gland, parathyroid gland, exocrine and endocrine pancreas, oesophagus, stomach, small intestine, large intestine, liver, gall bladder, spleen, kidneys, adrenal gland, lymph nodes, spinal cord, bone marrow, sternum, femur and tibia with associated skeletal muscles, brown fat, pinna, skin, uterus, oviduct, and ovary, and mammary gland.

AnimalID: M01247637 (Female)**Histopathology Findings:****knee (MA:000046)****Histopath Description:**

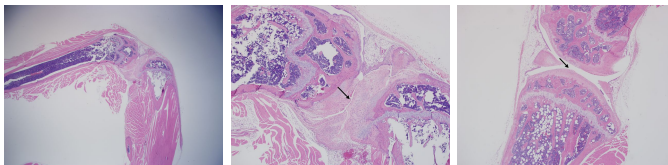
There is degeneration, erosion and fusion (ankylosis) of the articular cartilages of the knee. There is a prominent fissure at the base of the tibial articular cartilage. There is mild synovial hyperplasia.

Morphological Diagnosis:

Duration: chronic; **Distribution:** diffuse; **Severity:** extreme; **MPATH Process Term:** degenerative change MPATH:14

Definitive Diagnosis:

Osteoarthritis with ankylosis



Knee joint, degenerative joint disease with ankylosis, 4x, HE

Knee joint, degenerative joint disease with ankylosis, 4x, HE

Knee joint, wildtype, normal, 4x, HE

Organ/Tissue Analyzed:

Histopathology examination included the following organs and tissues: brain, trigeminal ganglion, eyes, salivary glands, trachea, lungs, heart, thymus, thyroid gland, parathyroid gland, exocrine and endocrine pancreas, oesophagus, stomach, small intestine, large intestine, liver, gall bladder, spleen, kidneys, adrenal gland, lymph nodes, spinal cord, bone marrow, sternum, femur and tibia with associated skeletal muscles, brown fat, pinna, skin, uterus, oviduct, and ovary, and mammary gland.

Report Summary and Recommendation:

Severe degenerative joint disease) of the knee joint was observed in one female mouse. The lesion explains the abnormal joint morphology and arthropathy by x-ray imaging. We did not see morphological explanations (correlates) to the rest of the clinical phenotypes. We did not find lesions to explain partial lethality in homozygotes. Analysis of homozygous embryos/ fetuses may explain cause mortality.

Line summary:

Knee Joint: Degenerative joint disease (arthropathy) with ankylosis (1/4).