



CMHD Pathology Report



CMHD Pathology Core

Toronto Centre for
Phenogenomics
25 Orde St. 3rd fl.
Toronto, Ont. M5T 3H7
Tel.(416) 586-8375
Fax (416) 586-5993

contact: Dr. Susan
Newbigging
email:
newbigging@lunenfeld.ca

Principle Investigator: Dr. Jacqui White

Institute: Wellcome Trust Sanger Institute
Address: Attn: Linda Read Wellcome Trust
Genome Campus Hinxton Cambridge CB10
1SA, UK

ReportID: Report Date: March 06, 2014
Pathologist: Dr. H. Adissu

Mouse Genetics Project

Wellcome Trust Sanger
Institute
Wellcome Trust Genome
Campus
Hinxton, Cambridge
CB10 1SA
UK

email:
MGPenquiries@sanger.ac.uk
[Mouse Portal](#)
[Europhenome](#)

CMHD LabID: N13-1041

Relevant History:

Phenotype:

None (no hit)

AnimalID: M01071888 (Male)

Histopathology Findings:

sternum (MA:0001331)

Histopath Description:

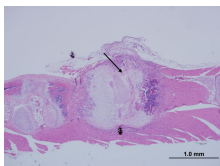
There is a sternal dislocation between the 4th and 5th sternal bodies. This is encased by a large nodular cartilaginous proliferation that extends to the outer aspect of the body wall and into the thoracic cavity (reactive reparative chondroid hyperplasia)

Morphological Diagnosis:

Duration: chronic; **Distribution:** focally extensive; **MPATH Process Term:** degenerative change MPATH:14

Definitive Diagnosis:

Sternal dislocation and reactive and reparative chondroid hyperplasia ('calus')



Sternum, segmental
dislocation and
reactive and callus,
4x, HE

skin (MA:0000151)

Histopath Description:

There is a focal aggregate of neutrophils admixed with nuclear debris within the epidermis.

Morphological Diagnosis:

Distribution: multifocal; **Severity:** mild; **MPATH Diagnosis:** inflammation MPATH:212; **MPATH Process Term:** inflammation MPATH:212

Definitive Diagnosis:

Epidermitis, focal

Histopathology Comments:

This is considered an incidental lesion likely caused by focal trauma

Organ/Tissue Analyzed:

Histopathology examination included the following organs and tissues: brain, trigeminal ganglion, eyes, salivary glands, trachea, lungs, heart, thymus, thyroid gland, parathyroid gland, exocrine and endocrine pancreas, oesophagus, stomach, small intestine, large intestine, liver, gall bladder, spleen, kidneys,

adrenal gland, lymph nodes, spinal cord, bone marrow, sternum, femur and tibia with associated skeletal muscles, brown fat, pinna, skin, testis, epididymis, seminal vesicle, and prostate.

AnimalID: M01058790 (Male)**Histopathology Findings:****sternum (MA:0001331)****Histopath Description:**

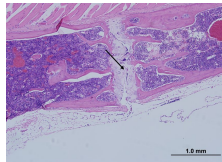
There is a full fissure within the 4th intersternbral joint. There are degenerative changes within the adjacent cartilage along the crack.

Morphological Diagnosis:

Distribution: focally extensive;

Definitive Diagnosis:

Sternal fissure



Sternum, fissure,
4x, HE

brain (MA:0000168)**Histopath Description:**

There is marked dilation of the lateral ventricles

Morphological Diagnosis:

Distribution: diffuse; **Severity:** severe; **MPATH Diagnosis:** hydrocephalus MPATH:639;
MPATH Process Term: degenerative change MPATH:14

Definitive Diagnosis:

Dilation of the brain ventricles

Histopathology Comments:

Mild to moderate dilation of the ventricles is a background condition in mice of C57BL/6N background

Organ/Tissue Analyzed:

Histopathology examination included the following organs and tissues: brain, trigeminal ganglion, eyes, salivary glands, trachea, lungs, heart, thymus, thyroid gland, parathyroid gland, exocrine and endocrine pancreas, oesophagus, stomach, small intestine, large intestine, liver, gall bladder, spleen, kidneys, adrenal gland, lymph nodes, spinal cord, bone marrow, sternum, femur and tibia with associated skeletal muscles, brown fat, pinna, skin, testis, epididymis, seminal vesicle, and prostate.

AnimalID: M01035130 (Female)**Organ/Tissue Analyzed:**

Histopathology examination included the following organs and tissues: brain, trigeminal ganglion, eyes, salivary glands, trachea, lungs, heart, thymus, thyroid gland, parathyroid gland, exocrine and endocrine pancreas, oesophagus, stomach, small intestine, large intestine, liver, gall bladder, spleen, kidneys, adrenal gland, lymph nodes, spinal cord, bone marrow, sternum, femur and tibia with associated skeletal muscles, brown fat, pinna, skin, uterus, oviduct, and ovary, and mammary gland.

AnimalID: M01026496 (Female)**Histopathology Findings:****sternum (MA:0001331)****Histopath Description:**

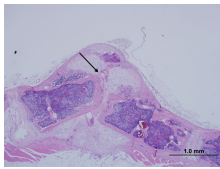
There is a sternal dislocation between the 4th and 5th sternal bodies. This is encased by a large nodular cartilaginous proliferation that extends to the outer aspect of the body wall and into the thoracic cavity (reactive reparative chondroid hyperplasia)

Morphological Diagnosis:

Duration: chronic; **Distribution:** focally extensive; **MPATH Process Term:** degenerative change MPATH:14

Definitive Diagnosis:

Sternal dislocation and reactive and reparative chondroid hyperplasia ('calus')



Sternum, segmental dislocation and reactive and callus, 4x, HE

heart (MA:0000072)

Histopath Description:

There is focal epicardial fibrosis of the right atrium

Morphological Diagnosis:

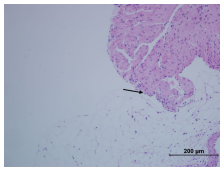
Duration: chronic; **Distribution:** focally extensive; **MPATH Process Term:** fibrosis MPATH:181

Definitive Diagnosis:

Right atrial epicardial fibrosis, focal

Histopathology Comments:

The lesion is likely caused by abrasion from fractured and displaced sternum



Heart, right atrium, focal subepicardial fibrosis, 20x, HE

lymph node (MA:0000139)

Histopath Description:

The mesenteric lymph node is markedly enlarged (greater than four fold). The medulla is particularly expanded by chords and sheets of plasmotoid cells. There are prominent germinal centers within the medulla

Morphological Diagnosis:

Distribution: Diffuse; **Severity:** moderate; **MPATH Diagnosis:** hyperplasia MPATH:134; **MPATH Process Term:** hyperplasia MPATH:134

Definitive Diagnosis:

Lymphoid hyperplasia

Histopathology Comments:

The changes in the mesenteric lymph node are suggestive of draining of a regional inflammatory process. However, such a process was not observed in the tissues examined. Early maginal center lymphoma is suspected.

thyroid gland (MA:0000129)

Histopath Description:

The thyroid interstitium contains well differentiated lymphoid tissue that is reminiscent of thymic tissue

Morphological Diagnosis:

Distribution: focally extensive; **MPATH Process Term:** developmental and structural abnormality MPATH:55

Definitive Diagnosis:

Ectopic thymus

Histopathology Comments:

Thymic rests present in 1% of adult human thyroid glands

Organ/Tissue Analyzed:

Histopathology examination included the following organs and tissues: brain, trigeminal ganglion, eyes, salivary glands, trachea, lungs, heart, thymus, thyroid gland, parathyroid gland, exocrine and endocrine pancreas, oesophagus, stomach, small intestine, large intestine, liver, gall bladder, spleen, kidneys, adrenal gland, lymph nodes, spinal cord, bone marrow, sternum, femur and tibia with associated skeletal muscles, brown fat, pinna, skin, uterus, oviduct, and ovary, and mammary gland.

Report Summary and Recommendation:

Three mice have sternal lesion (one full thickness fissure and two with segmental dislocation). One of these mice had auricular fibrosis, likely caused by abrasion by large callus from the sternal lesion. The presence of sternal lesion in three of the four mice may suggest an underlying predisposition. Other lesions in this line are incidental or attributable to strain background.

Line summary:

Sternum: Segmental sternal dislocation (3/4)

Heart, auricle: Focal epicardial fibrosis (1/4).