



CMHD Pathology Report



CMHD Pathology Core

Toronto Centre for
Phenogenomics
25 Orde St. 3rd fl.
Toronto, Ont. M5T 3H7
Tel.(416) 586-8375
Fax (416) 586-5993

contact: Dr. Susan
Newbigging
email:
newbigging@lunenfeld.ca

Principle Investigator: Dr. Jacqui White

Institute: Wellcome Trust Sanger Institute
Address: Attn: Linda Read Wellcome Trust
Genome Campus Hinxton Cambridge CB10
1SA, UK

ReportID: Report Date: February 26,
2014
Pathologist: Dr. H. Adissu

Mouse Genetics Project

Wellcome Trust Sanger
Institute
Wellcome Trust Genome
Campus
Hinxton, Cambridge
CB10 1SA
UK

email:
MGPenquiries@sanger.ac.uk
[Mouse Portal](#)
[Europhenome](#)

CMHD LabID: N13-1053

Relevant History:

Phenotype:

No phenotype

AnimalID: M01337065 (Male)

Histopathology Findings:

thyroid gland (MA:0000129)

Histopath Description:

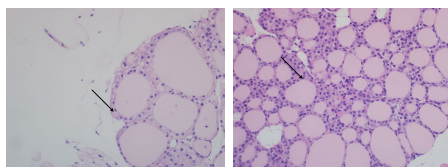
Follicular epithelial cells and parafollicular cells are markedly enlarged (1.5 -2x) normal and have a glassy eosinophilic cytoplasm

Morphological Diagnosis:

Distribution: diffuse; **Severity:** severe; **MPATH Process Term:** degenerative change
MPATH:14

Definitive Diagnosis:

Thyroid gland, follicular and parafollicular cells, hypertrophy and hyaline degeneration



Thyroid gland,
hyaline
degeneration of
follicular and
parafollicular cells,
40x, HE

Thyroid gland, WT,
normal, 40x, HE

eye (MA:0000261)

Histopath Description:

Involving one eye, there are clusters of external nuclear structures within the internal plexiform layer.

Morphological Diagnosis:

Distribution: multifocal; **Severity:** mild; **MPATH Process Term:** developmental dysplasia
MPATH:64

Definitive Diagnosis:

Retinal dysplasia

Organ/Tissue Analyzed:

Histopathology examination included the following organs and tissues: brain, trigeminal ganglion, eyes, salivary glands, trachea, lungs, heart, thymus, thyroid gland, parathyroid gland, exocrine and endocrine pancreas, oesophagus, stomach, small intestine, large intestine, liver, gall bladder, spleen, kidneys,

adrenal gland, lymph nodes, spinal cord, bone marrow, sternum, femur and tibia with associated skeletal muscles, brown fat, pinna, skin, testis, epididymis, seminal vesicle, and prostate.

AnimalID: M01298757 (Male)

Histopathology Findings:

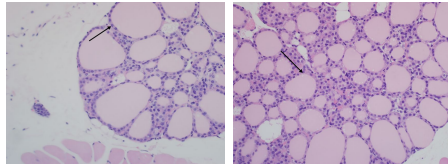
thyroid gland (MA:0000129)

Histopath Description:

Normal

Definitive Diagnosis:

Normal



Thyroid gland,
normal, 40x, HE

Thyroid gland, WT,
normal, 40x, HE

brain (MA:0000168)

Histopath Description:

There are 50 um and 200 um diameter dermoid cysts within the cranial caudoputamen. The larger cyst is keratin-filled and is lined by a well-differentiated simple squamous epithelium.

Morphological Diagnosis:

Distribution: multifocal; **Severity:** mild; **MPATH Diagnosis:** dermoid cyst MPATH:311; **MPATH Process Term:** developmental and structural abnormality MPATH:55

Definitive Diagnosis:

Dermoid cyst (dermoid sinus)

Histopathology Comments:

Dermoid cyst is caused by defective epidermal closure along embryonic fissures isolating an island of ectoderm in the dermis or subcutis. The cyst was small with minimal compression of the surrounding brain tissue; its significance is uncertain.

Organ/Tissue Analyzed:

Histopathology examination included the following organs and tissues: brain, trigeminal ganglion, eyes, salivary glands, trachea, lungs, heart, thymus, thyroid gland, parathyroid gland, exocrine and endocrine pancreas, oesophagus, stomach, small intestine, large intestine, liver, gall bladder, spleen, kidneys, adrenal gland, lymph nodes, spinal cord, bone marrow, sternum, femur and tibia with associated skeletal muscles, brown fat, pinna, skin, testis, epididymis, seminal vesicle, and prostate.

AnimalID: M01322515 (Female)

Histopathology Findings:

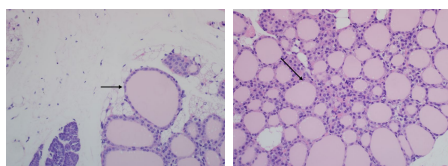
thyroid gland (MA:0000129)

Histopath Description:

Normal

Definitive Diagnosis:

Normal



Thyroid gland,
normal, 40x, HE

Thyroid gland, WT,
normal, 40x, HE

eye (MA:0000261)

Histopath Description:

A 100 stalk of fibrous connective tissue containing a small artery in the center extends from the area of the optic disc towards the posterior vitreous. A small fragment of fibrous tissue is freely present within the vitreous anterior to this stalk (assumed to be extension of the stalk).

Morphological Diagnosis:

MPATH Diagnosis: developmental and structural abnormality MPATH:55; **MPATH Process**

Term: developmental and structural abnormality MPATH:55

Definitive Diagnosis:

Persistent hyaloid artery

Histopathology Comments:

hyaloid artery remnant is a rare condition in which there remain some parts of the hyaloid artery. The posterior hyaloid vascular system of mice usually undergoes involution in the first month of life (Richard et al., 2000).

Organ/Tissue Analyzed:

Histopathology examination included the following organs and tissues: brain, trigeminal ganglion, eyes, salivary glands, trachea, lungs, heart, thymus, thyroid gland, parathyroid gland, exocrine and endocrine pancreas, oesophagus, stomach, small intestine, large intestine, liver, gall bladder, spleen, kidneys, adrenal gland, lymph nodes, spinal cord, bone marrow, sternum, femur and tibia with associated skeletal muscles, brown fat, pinna, skin, uterus, oviduct, and ovary, and mammary gland.

AnimalID: M01254517 (Female)

Histopathology Findings:

thyroid gland (MA:0000129)

Histopath Description:

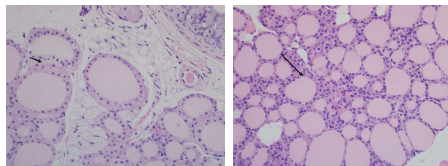
Follicular epithelial cells are markedly enlarged (1.5 -2x) normal and have a glassy eosinophilic cytoplasm

Morphological Diagnosis:

Distribution: diffuse; **Severity:** severe; **MPATH Process Term:** degenerative change MPATH:14

Definitive Diagnosis:

Thyroid gland, follicular epithelium, cellular hypertrophy and hyalinization



Thyroid gland, hyaline degeneration of follicular and parafollicular cells, 40x, HE

Thyroid gland, WT, normal, 40x, HE

lymph node (MA:0000139)

Histopath Description:

The mesenteric lymph node is markedly enlarged (greater than four fold). The medulla is particularly expanded by chords and sheets of plasmotoid cells. There are prominent germinal centers within the medulla

Morphological Diagnosis:

Distribution: Diffuse; **Severity:** moderate; **MPATH Diagnosis:** hyperplasia MPATH:134; **MPATH Process Term:** hyperplasia MPATH:134

Definitive Diagnosis:

Lymphoid hyperplasia

Histopathology Comments:

The changes in the mesenteric lymph node are suggestive of draining of a regional inflammatory process. However, such a process was not observed in the tissues examined. Early marginal center lymphoma is suspected.

Organ/Tissue Analyzed:

Histopathology examination included the following organs and tissues: brain, trigeminal ganglion, eyes, salivary glands, trachea, lungs, heart, thymus, thyroid gland, parathyroid gland, exocrine and endocrine pancreas, oesophagus, stomach, small intestine, large intestine, liver, gall bladder, spleen, kidneys, adrenal gland, lymph nodes, spinal cord, bone marrow, sternum, femur and tibia with associated skeletal muscles, brown fat, pinna, skin, uterus, oviduct, and ovary, and mammary gland.

Report Summary and Recommendation:

Hyaline degeneration of the thyroid follicular and parafollicular cells was observed in two mice. This is a unique lesion although its significance in absence of any reported endocrine abnormality is uncertain. Similar lesion was associated with spontaneous loss of calcitonin and somatostatin in thyroid C cells of a guinea pig (Kameda, 1984).

Other lesions in this line are incidental or attributable to strain background.

Thyroid gland, follicular and parafollicular cells, hyaline degeneration (2/4)

References:

Kameda Y. The spontaneous loss of calcitonin and somatostatin in thyroid C cells of a guinea pig. Arch Histol Jpn. 1984 Oct;47(4):421-7.