



CMHD Pathology Report



CMHD Pathology Core

Toronto Centre for
Phenogenomics
25 Orde St. 3rd fl.
Toronto, Ont. M5T 3H7
Tel.(416) 586-8375
Fax (416) 586-5993

contact: Dr. Susan
Newbigging
email:
newbigging@lunenfeld.ca

Principle Investigator: Dr. Jacqui White

Institute: Wellcome Trust Sanger Institute
Address: Attn: Linda Read Wellcome Trust
Genome Campus Hinxton Cambridge CB10
1SA, UK

ReportID: Report Date: January 09, 2014
Pathologist: Dr. H. Adissu

Mouse Genetics Project

Wellcome Trust Sanger
Institute
Wellcome Trust Genome
Campus
Hinxton, Cambridge
CB10 1SA
UK

email:
MGPenquiries@sanger.ac.uk
[Mouse Portal](#)
[Europhenome](#)

CMHD LabID: N13-711

Relevant History:

Phenotype:

Eye Morphology

AnimalID: M01053678 (Male)

Histopathology Findings:

retina (MA:0000276)

Histopath Description:

There are clusters of external nuclear structures within the layer of rods and cons.

Morphological Diagnosis:

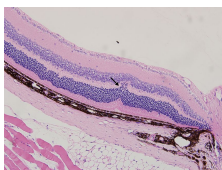
Distribution: Focal; **Severity:** mild; **MPATH Diagnosis:** developmental and structural abnormality MPATH:55; **MPATH Process Term:** developmental and structural abnormality MPATH:55

Definitive Diagnosis:

Retinal dysplasia

Histopathology Comments:

Retinal dysplasia is reported as a background lesion in C57BL/6N lines (Mattapallil et al., 2012).



Retina, dysplasia,
20x, HE

lymph node (MA:0000139)

Histopath Description:

The mesenteric lymph node is markedly enlarged (greater than four fold). The medulla is particularly expanded by chords and sheets of plasmotoid cells. There are prominent germinal centers within the medulla

Morphological Diagnosis:

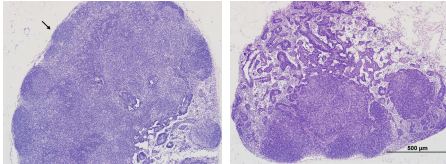
Distribution: Diffuse; **Severity:** moderate; **MPATH Diagnosis:** hyperplasia MPATH:134;
MPATH Process Term: hyperplasia MPATH:134

Definitive Diagnosis:

Lymphoid hyperplasia

Histopathology Comments:

The changes in the mesenteric lymph node are suggestive of draining of a regional inflammatory process. However, such a process was not observed in the tissues examined. Early marginal center lymphoma is suspected.



Lymph node,
hyperplasia, 10x,
HE

Lymph node, WT,
normal, 10x, HE

Organ/Tissue Analyzed:

Histopathology examination included the following organs and tissues: brain, trigeminal ganglion, eyes, salivary glands, trachea, lungs, heart, thymus, thyroid gland, parathyroid gland, exocrine and endocrine pancreas, oesophagus, stomach, small intestine, large intestine, liver, gall bladder, spleen, kidneys, adrenal gland, lymph nodes, spinal cord, bone marrow, sternum, femur and tibia with associated skeletal muscles, brown fat, pinna, skin, testis, epididymis, seminal vesicle, and prostate.

AnimalID: M01053679 (Male)

Histopathology Findings:

retina (MA:0000276)

Histopath Description:

There is focally extensive retinal fold at the posterior aspect.

Morphological Diagnosis:

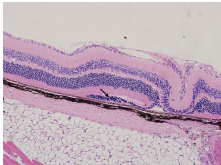
Distribution: focally extensive; **Severity:** mild; **MPATH Diagnosis:** developmental and structural abnormality MPATH:55; **MPATH Process Term:** developmental and structural abnormality MPATH:55

Definitive Diagnosis:

Retinal fold/dysplasia

Histopathology Comments:

Retinal dysplasia is reported as a background lesion in C57BL/6N lines (Mattapallil et al., 2012).



Retina, dysplasia,
20x, HE

lymph node (MA:0000139)

Histopath Description:

The mesenteric lymph node is markedly enlarged (greater than four fold). The medulla is particularly expanded by chords and sheets of plasmotoid cells. There are prominent germinal centers within the medulla

Morphological Diagnosis:

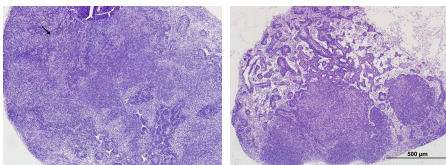
Distribution: Diffuse; **Severity:** moderate; **MPATH Diagnosis:** hyperplasia MPATH:134; **MPATH Process Term:** hyperplasia MPATH:134

Definitive Diagnosis:

Lymphoid hyperplasia

Histopathology Comments:

The changes in the mesenteric lymph node are suggestive of draining of a regional inflammatory process. However, such a process was not observed in the tissues examined. Early maginal center lymphoma is suspected.



Lymph node,
hyperplasia, 10x,
HE

Lymph node, WT,
normal, 10x, HE

Organ/Tissue Analyzed:

Histopathology examination included the following organs and tissues: brain, trigeminal ganglion, eyes, salivary glands, trachea, lungs, heart, thymus, thyroid gland, parathyroid gland, exocrine and endocrine

pancreas, oesophagus, stomach, small intestine, large intestine, liver, gall bladder, spleen, kidneys, adrenal gland, lymph nodes, spinal cord, bone marrow, sternum, femur and tibia with associated skeletal muscles, brown fat, pinna, skin, testis, epididymis, seminal vesicle, and prostate.

AnimalID: M01053683 (Female)

Histopathology Findings:

eye (MA:0000261)

Histopath Description:

A 100 stalk of fibrous connective tissue containing a small artery in the center extends from the area of the optic disc towards the posterior vitreous. A small fragment of fibrous tissue is freely present within the vitreous anterior to this stalk (assumed to be extension of the stalk).

Morphological Diagnosis:

MPATH Diagnosis: developmental and structural abnormality MPATH:55; **MPATH Process**

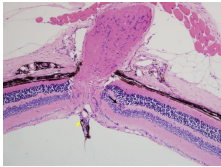
Term: developmental and structural abnormality MPATH:55

Definitive Diagnosis:

Persistent hyaloid artery

Histopathology Comments:

hyaloid artery remnant is a rare condition in which there remain some parts of the hyaloid artery. The posterior hyaloid vascular system of mice usually undergoes involution in the first month of life (Richard et al., 2000).



Retina, dysplasia (black arrow) and hyaloid artery remnant (yellow arrow), 20x, HE

Lymph node (MA:0000139)

Histopath Description:

The architecture of the mesenteric lymph node is altered by the presence of large numbers of monomorphic lymphocytes filling and distending all the sinuses and elevating the capsule. The neoplastic cells have generally a scant amount of eosinophilic cytoplasm, medium sized round central nucleus with granular chromatin and single variably distinct amphophilic nucleoli. Mitotic figures are less than 1/HPF.

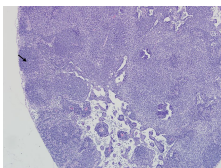
Morphological Diagnosis:

Distribution: Diffuse; **MPATH Diagnosis:** lymphoid neoplasms MPATH:513; **MPATH Process**

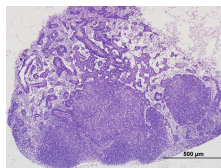
Term: neoplasia MPATH:218

Definitive Diagnosis:

Lymphoma



Lymph node, hyperplasia, 10x, HE



Lymph node, WT, normal, 10x, HE

Organ/Tissue Analyzed:

Histopathology examination included the following organs and tissues: brain, trigeminal ganglion, eyes, salivary glands, trachea, lungs, heart, thymus, thyroid gland, parathyroid gland, exocrine and endocrine pancreas, oesophagus, stomach, small intestine, large intestine, liver, gall bladder, spleen, kidneys, adrenal gland, lymph nodes, spinal cord, bone marrow, sternum, femur and tibia with associated skeletal muscles, brown fat, pinna, skin, uterus, oviduct, and ovary, and mammary gland.

AnimalID: M01053684 (Female)

Histopathology Findings:

retina (MA:0000276)

Histopath Description:

There are clusters of external nuclear structures within the layer of rods and cons.

Morphological Diagnosis:

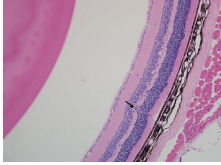
Distribution: Focal; **Severity:** mild; **MPATH Diagnosis:** developmental and structural abnormality MPATH:55; **MPATH Process Term:** developmental and structural abnormality MPATH:55

Definitive Diagnosis:

Retinal dysplasia

Histopathology Comments:

Retinal dysplasia is reported as a background lesion in C57BL/6N lines (Mattapallil et al., 2012).



Retina, dysplasia,
20x, HE

lymph node (MA:0000139)

Histopath Description:

The mesenteric lymph node is markedly enlarged (greater than four fold). The medulla is particularly expanded by chords and sheets of plasmotoid cells. There are prominent germinal centers within the medulla

Morphological Diagnosis:

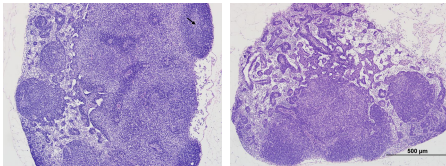
Distribution: Diffuse; **Severity:** moderate; **MPATH Diagnosis:** hyperplasia MPATH:134; **MPATH Process Term:** hyperplasia MPATH:134

Definitive Diagnosis:

Lymphoid hyperplasia

Histopathology Comments:

The changes in the mesenteric lymph node are suggestive of draining of a regional inflammatory process. However, such a process was not observed in the tissues examined. Early maginal center lymphoma is suspected.



Lymph node,
hyperplasia, 10x,
HE

Lymph node, WT,
normal, 10x, HE

kidney (MA:0000368)

Histopath Description:

There is focal perivascular mononuclear inflammatory cell aggregates at the corticomedullary junction.

Morphological Diagnosis:

Duration: chronic; **Distribution:** focal; **Severity:** mild; **MPATH Process Term:** inflammation MPATH:212

Definitive Diagnosis:

Focal chronic perivascular inflammatory cell aggregates

Histopathology Comments:

Incidental

Organ/Tissue Analyzed:

Histopathology examination included the following organs and tissues: brain, trigeminal ganglion, eyes, salivary glands, trachea, lungs, heart, thymus, thyroid gland, parathyroid gland, exocrine and endocrine pancreas, oesophagus, stomach, small intestine, large intestine, liver, gall bladder, spleen, kidneys, adrenal gland, lymph nodes, spinal cord, bone marrow, sternum, femur and tibia with associated skeletal muscles, brown fat, pinna, skin, uterus, oviduct, and ovary, and mammary gland.

Report Summary and Recommendation:

Mild and focal dysplastic retinal lesions are present in all mice. The lesion may explain the abnormal retinal pigmentation/morphology documented during clinical phenotyping. However, this finding should be cautiously interpreted in light of the high prevalence of similar lesions in this strain (C57BL/6N). Lymphoid

hyperplasia was observed in all mice in this line. Lymph node hyperplasia could also be seen in wildtype mice albeit at low prevalence (5-15% in various B6 WT strains we have analyzed). Hence this finding should be interpreted with caution.

Line summary:

Eye - retinal dysplasia (4/4)

Mesenteric lymph node: Lymphoid hyperplasia (2/4); Lymphoma (2/4).