



CMHD Pathology Report



CMHD Pathology Core

Toronto Centre for
Phenogenomics
25 Orde St. 3rd fl.
Toronto, Ont. M5T 3H7
Tel.(416) 586-8375
Fax (416) 586-5993

contact: Dr. Susan
Newbigging
email:
newbigging@lunenfeld.ca

ReportID: Report Date: March 19, 2014
Pathologist: Dr. H. Adissu

Mouse Genetics Project

Wellcome Trust Sanger
Institute
Wellcome Trust Genome
Campus
Hinxton, Cambridge
CB10 1SA
UK

CMHD LabID: N13-1252

Relevant History:

Phenotype:

impaired glucose tolerance
decreased circulating glucose level

AnimalID: M00360154 (Male)

Histopathology Findings:

liver (MA:0000358)

Histopath Description:

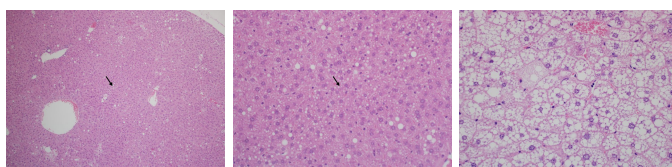
Overall the amount of lipid deposition in the liver is minimal compared to that seen in mice with high fat diet (see WT control). Low numbers of large vacuoles are present throughout the liver. An atypical milliary fine round vacuoles expand hepatocytes in midzonal and centrilobular areas (suspected to be glycogen).

Morphological Diagnosis:

MPATH Process Term: degenerative change MPATH:14

Definitive Diagnosis:

Minimal hepatocellular lipidosis; hepatocellular microvesicular vacuolation (suspected to be glycogen).



Liver, minimal
hepatocellular
lipidosis, 10x, HE

Liver, hepatocellular
microvesicular
vacuolation
(suspected to be
glycogen), 40x, HE

Liver, WT, severe
hepatic lipidosis
(high fat diet
control), 10x, HE.

spleen (MA:0000141)

Histopath Description:

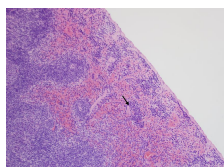
Erythropoiesis-erythroid

Morphological Diagnosis:

Distribution: multifocal to coalescing; **Severity:** moderate; **MPATH Diagnosis:** extramedullary hemopoiesis MPATH:595; **MPATH Process Term:** hyperplasia MPATH:134

Definitive Diagnosis:

Moderate erythropoiesis



Spleen, moderate erythropoiesis, 20x, HE.

sternum (MA:0001331)

Histopath Description:

There is a sternal dislocation between the 4th and 5th sternal bodies. This is encased by a large nodular cartilaginous proliferation that extends to the outer aspect of the body wall and into the thoracic cavity (reactive reparative chondroid hyperplasia)

Morphological Diagnosis:

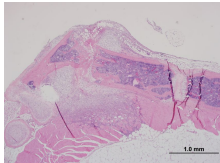
Duration: chronic; **Distribution:** focally extensive; **MPATH Process Term:** degenerative change MPATH:14

Definitive Diagnosis:

Sternal dislocation and reactive and reparative chondroid hyperplasia ('calus')

Histopathology Comments:

The cause of this lesion is not certain.



Sternum, dislocation with reactive and reparative chondroid hyperplasia ('calus')

heart (MA:0000072)

Histopath Description:

Epicardial fibrosis

Morphological Diagnosis:

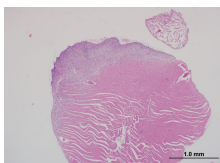
Duration: chronic; **Distribution:** focally extensive; **Severity:** severe; **MPATH Process Term:** fibrosis MPATH:181

Definitive Diagnosis:

Heart, right ventricular epicardial and subepicardial fibrosis

Histopathology Comments:

The lesion is likely caused by abrasion by the sternal dislocation



Heart, right ventricular epicardial and subepicardial fibrosis

cervical lymph node (MA:0000736)

Histopath Description:

lymphoma

Morphological Diagnosis:

MPATH Diagnosis: lymphoid hyperplasia MPATH:147; **MPATH Process Term:** neoplasia MPATH:218

Definitive Diagnosis:

Lymphoma

Organ/Tissue Analyzed:

Histopathology examination included the following organs and tissues: brain, trigeminal ganglion, eyes, salivary glands, trachea, lungs, heart, thymus, thyroid gland, parathyroid gland, exocrine and endocrine pancreas, oesophagus, stomach, small intestine, large intestine, liver, gall bladder, spleen, kidneys, adrenal gland, lymph nodes, spinal cord, bone marrow, sternum, femur and tibia with associated skeletal muscles, brown fat, pinna, skin, testis, epididymis, seminal vesicle, and prostate.

AnimalID: M00390903 (Male)**Histopathology Findings:****liver (MA:0000358)****Histopath Description:**

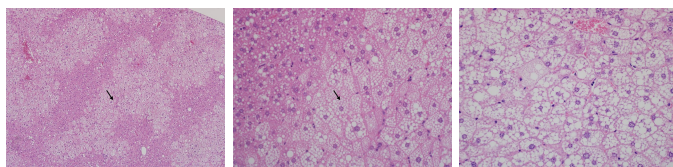
Overall the amount of lipid deposition in the liver is minimal compared to that seen in mice with high fat diet (see WT control). Low numbers of large vacuoles are present throughout the liver. An atypical milliary fine round vacuoles expand hepatocytes in midzonal and centrilobular areas (suspected to be glycogen).

Morphological Diagnosis:

MPATH Process Term: degenerative change MPATH:14

Definitive Diagnosis:

Minimal hepatocellular lipidosis; hepatocellular microvesicular vacuolation (suspected to be glycogen).



Liver, minimal hepatocellular lipidosis, 10x, HE

Liver, hepatocellular microvesicular vacuolation (suspected to be glycogen), 40x, HE

Liver, WT, severe hepatic lipidosis (high fat diet control), 10x, HE.

spleen (MA:0000141)**Histopath Description:**

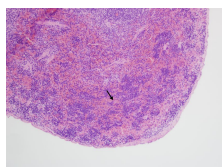
Erythropoiesis-erythroid

Morphological Diagnosis:

Distribution: multifocal to coalescing; **Severity:** moderate; **MPATH Diagnosis:** extramedullary hemopoiesis MPATH:595; **MPATH Process Term:** hyperplasia MPATH:134

Definitive Diagnosis:

Moderate erythropoiesis



Spleen, moderate erythropoiesis, 20x, HE.

Organ/Tissue Analyzed:

Histopathology examination included the following organs and tissues: brain, trigeminal ganglion, eyes, salivary glands, trachea, lungs, heart, thymus, thyroid gland, parathyroid gland, exocrine and endocrine pancreas, oesophagus, stomach, small intestine, large intestine, liver, gall bladder, spleen, kidneys, adrenal gland, lymph nodes, spinal cord, bone marrow, sternum, femur and tibia with associated skeletal muscles, brown fat, pinna, skin, testis, epididymis, seminal vesicle, and prostate.

AnimalID: M00374950 (Female)**Histopathology Findings:****liver (MA:0000358)****Histopath Description:**

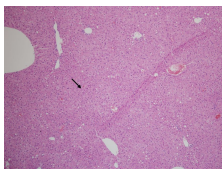
Overall the amount of lipid deposition in the liver is minimal compared to that seen in mice with high fat diet (see WT control). Low numbers of large vacuoles are present throughout the liver. An atypical milliary fine round vacuoles expand hepatocytes in midzonal and centrilobular areas (suspected to be glycogen).

Morphological Diagnosis:

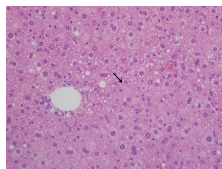
MPATH Process Term: degenerative change MPATH:14

Definitive Diagnosis:

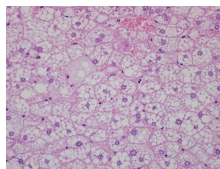
Minimal hepatocellular lipidosis; hepatocellular microvesicular vacuolation (suspected to be glycogen).



Liver, minimal hepatocellular lipidosis, 10x, HE



Liver, hepatocellular microvesicular vacuolation (suspected to be glycogen), 40x, HE



Liver, WT, severe hepatic lipidosis (high fat diet control), 40x, HE.

spleen (MA:0000141)

Histopath Description:

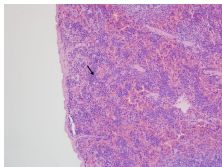
Erythropoiesis-erythroid

Morphological Diagnosis:

Distribution: multifocal to coalescing; **Severity:** moderate; **MPATH Diagnosis:** extramedullary hemoipoiesis MPATH:595; **MPATH Process Term:** hyperplasia MPATH:134

Definitive Diagnosis:

Moderate erythropoiesis



Spleen, moderate erythropoiesis, 20x, HE.

brain (MA:0000168)

Histopath Description:

There is moderate dilation of the cerebral aqueduct

Morphological Diagnosis:

Distribution: diffuse; **Severity:** severe; **MPATH Process Term:** degenerative change MPATH:14

Definitive Diagnosis:

Dilation of the brain ventricles

Histopathology Comments:

Mild to moderate dilation of the ventricles is a background condition in mice of C57BL/6N background

Organ/Tissue Analyzed:

Histopathology examination included the following organs and tissues: brain, trigeminal ganglion, eyes, salivary glands, trachea, lungs, heart, thymus, thyroid gland, parathyroid gland, exocrine and endocrine pancreas, oesophagus, stomach, small intestine, large intestine, liver, gall bladder, spleen, kidneys, adrenal gland, lymph nodes, spinal cord, bone marrow, sternum, femur and tibia with associated skeletal muscles, brown fat, pinna, skin, uterus, oviduct, and ovary, and mammary gland.

AnimalID: M00374952 (Female)

Histopathology Findings:

liver (MA:0000358)

Histopath Description:

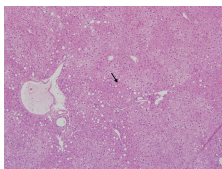
Overall the amount of lipid deposition in the liver is minimal compared to that seen in mice with high fat diet (see WT control). Low numbers of large vacuoles are present throughout the liver. An atypical milliary fine round vacuoles expand hepatocytes in midzonal and centrilobular areas (suspected to be glycogen).

Morphological Diagnosis:

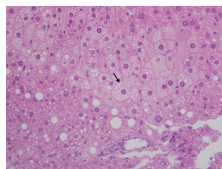
MPATH Process Term: degenerative change MPATH:14

Definitive Diagnosis:

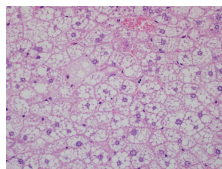
Minimal hepatocellular lipidosis; hepatocellular microvesicular vacuolation (suspected to be glycogen).



Liver, minimal hepatocellular lipidosis, 10x, HE



Liver, hepatocellular microvesicular vacuolation (suspected to be glycogen), 10x, HE



Liver, WT, severe hepatic lipidosis (high fat diet control), 10x, HE. 40x

spleen (MA:0000141)

Histopath Description:

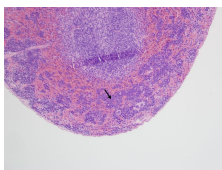
Erythropoiesis-erythroid

Morphological Diagnosis:

Distribution: multifocal to coalescing; **Severity:** moderate; **MPATH Diagnosis:** extramedullary hemopoiesis MPATH:595; **MPATH Process Term:** hyperplasia MPATH:134

Definitive Diagnosis:

Moderate erythropoiesis



Spleen, moderate erythropoiesis, 20x, HE.

brain (MA:0000168)

Histopath Description:

There is moderate dilation of the cerebral aqueduct

Morphological Diagnosis:

Distribution: diffuse; **Severity:** severe; **MPATH Process Term:** degenerative change MPATH:14

Definitive Diagnosis:

Dilation of the brain ventricles

Histopathology Comments:

Mild to moderate dilation of the ventricles is a background condition in mice of C57BL/6N background

Organ/Tissue Analyzed:

Histopathology examination included the following organs and tissues: brain, trigeminal ganglion, eyes, salivary glands, trachea, lungs, heart, thymus, thyroid gland, parathyroid gland, exocrine and endocrine pancreas, oesophagus, stomach, small intestine, large intestine, liver, gall bladder, spleen, kidneys, adrenal gland, lymph nodes, spinal cord, bone marrow, sternum, femur and tibia with associated skeletal muscles, brown fat, pinna, skin, uterus, oviduct, and ovary, and mammary gland.

Report Summary and Recommendation:

Hepatic lipidosis in this mice is minimal despite high fat diet. There is an atypical hepatocellular vacuolation in all mice. The vacuoles are suggestive of glycogen. Special staining is required to confirm the identity of the material. All mice also had a mild to moderate splenic erythropoiesis in all mice. This could be a general non-specific response to the general health condition of the mice.

Line summary:

Liver: Minimal hepatic lipidosis (4/4); atypical midzonal and centrilobular hepatic vacuolation (4/4).

Spleen: Mild to moderate extramedullary hematopoiesis (4/4)