



CMHD Pathology Report

CMHD Pathology Core

Toronto Centre for Phenogenomics
25 Orde St. 3rd fl.
Toronto, Ont. M5T 3H7
Tel. (416) 586-8375
Fax (416) 586-5993

contact: Dr. Susan Newbigging
email: newbigging@lunenfeld.ca

ReportID: MSH13006
Pathologist: H. Adissu

Report Date: January 17, 2013

CMHD LabID: N12-1502

History:

abnormal hair cycle anagen phase in female mice
preweaning lethality
increased monocyte cell number

AnimalID: M00285953

Tissue Preservation and Staining:

Skin samples are not well preserved.

Histopathology Findings:

mesenteric lymph node (MA:0002829)

Histopath Description:

The lymph node is enlarged. The medullary and subcapsular sinuses are distended and expanded by pleomorphic histiocytic cells. Lymphoid follicles are enlarged and contain germinal centers

Morphological Diagnosis:

Distribution: multifocal to coalescing; **Severity:** moderate; **MPATH Diagnosis:** histiocytosis MPATH:146

Definitive Diagnosis:

Sinus histiocytosis; lymphoid hyperplasia

Histopathology Comments:

The lesion may explain the monocytosis observed

liver (MA:0000358)

Histopath Description:

severe lipidosis,

Morphological Diagnosis:

Distribution: diffuse; **Severity:** severe;

Definitive Diagnosis:

Hepatic lipidosis

retina (MA:0000276)

Histopath Description:

mild multifocal retinal dysplasia

Morphological Diagnosis:

Distribution: multifocal; **Severity:** mild; **MPATH Diagnosis:** developmental and structural abnormality MPATH:55

Definitive Diagnosis:

retinal dysplasia, mild

Histopathology Comments:

Retinal dysplasia is reported as a background lesion in C57BL/6N lines (Mattapallil et al., 2012)

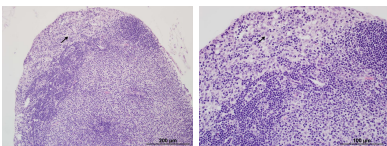
brain (MA:0000168)

Histopath Description:

hydrocephalus

Morphological Diagnosis:

Distribution: bilateral; **Severity:** mild; **MPATH Diagnosis:** hydrocephalus MPATH:639



Lymph node, sinus histiocytosis, 20x Lymph node, sinus histiocytosis, 40x

There were no significant findings in the following tissues: tongue, Harderian gland, zymbal gland, salivary glands, nasal sinuses, teeth, trachea, lungs, heart, thymus, thyroid gland, parathyroid gland, spleen, gall bladder, exocrine and endocrine pancreas, esophagus, stomach, intestines, urinary organs and tract, adrenal gland, reproductive organs, spinal cord, bones, bone marrow, skeletal muscles, brown fat, and skin.

AnimalID: M00285954**Tissue Preservation and Staining:**

Skin samples are not well preserved.

Histopathology Findings:**liver (MA:0000358)****Histopath Description:**

severe lipidosis,

Morphological Diagnosis:

Distribution: diffuse; **Severity:** severe; **MPATH Diagnosis:** lipid deposition MPATH:42

Definitive Diagnosis:

Hepatic lipodosis

salivary gland (MA:0000346)**Histopath Description:**

There is focal perivascular mononuclear inflammatory cells.

Morphological Diagnosis:

Distribution: focal; **Severity:** mild; **MPATH Diagnosis:** inflammation MPATH:212

Definitive Diagnosis:

Perivascular inflammatory aggregate

pancreatic lymph node (MA:0002881)**Histopath Description:**

The medullary and subcapsular sinuses contains numerous histiocytic cells.

Morphological Diagnosis:

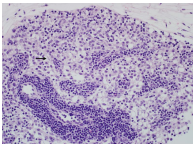
Distribution: multifocal to coalescing; **Severity:** moderate; **MPATH Diagnosis:** histiocytosis MPATH:146

Definitive Diagnosis:

Sinus histiocytosis

Histopathology Comments:

The lesion may explain the monocytosis observed



Lymph node, sinus
histiocytosis, 40x

Skin samples are not well preserved. There were no significant findings in the following tissues: brain, eyes, tongue, Harderian gland, zymbal gland, nasal sinuses, teeth, trachea, lungs, heart, thymus, thyroid gland, parathyroid gland, spleen, gall bladder, exocrine and endocrine pancreas, esophagus, stomach, intestines, urinary organs and tract, adrenal gland, reproductive organs spinal cord, bones, bone marrow, skeletal muscles, brown fat, and skin.

AnimalID: M00313124**Tissue Preservation and Staining:**

Skin samples are not well preserved.

Histopathology Findings:**mesenteric lymph node (MA:0002829)****Histopath Description:**

The lymph node is markedly enlarged. The medullary and subcapsular sinuses contain large numbers of histiocytic cells. Lymphoid follicles are enlarged and contain germinal centers. The medullary sinuses contain large numbers of well differentiated mature lymphocytes

Morphological Diagnosis:

Distribution: multifocal to coalescing; **Severity:** moderate; **MPATH Diagnosis:** hyperplasia MPATH:134

Definitive Diagnosis:

Lymphoid hyperplasia with sinus histiocytosis; lymphoid hyperplasia

Histopathology Comments:

The lesion may explain the monocytosis observed

spleen (MA:0000141)**Histopath Description:**

There is marked extramedullary erythroid hematopoiesis

Morphological Diagnosis:

Severity: moderate; **MPATH Diagnosis:** extramedullary hemopoiesis MPATH:595

Definitive Diagnosis:

Erythroid extramedullary hemopoiesis

liver (MA:0000358)**Histopath Description:**

severe lipidosis,

Morphological Diagnosis:

Distribution: diffuse; **Severity:** severe; **MPATH Diagnosis:** lipid deposition MPATH:42

Definitive Diagnosis:

Hepatic lipodosis

ovary (MA:0000384)**Histopath Description:**

Within one of the ovaries, there an expansile proliferation of luteal-like cells that displaces and compresses rare

normal ovarian structures (few growing follicles and non mature). The tumor is composed of sheets of plump, round to polygonal cells. The cells have moderate to abundant vacuolated cytoplasm and distinct borders (typical lutein cells). Nuclei are central with finely stippled chromatin with 1-2 prominent nucleoli. Mitotic figures are not seen. Neoplastic cells are monomorphic with minimal cell and nuclear size variation. The contraletral ovary is not available in section

Morphological Diagnosis:

Distribution: unilateral; **MPATH Diagnosis:** luteal cell tumor MPATH:329

Definitive Diagnosis:

Ovarian stromal cell tumour (Diff Dx: sertoli, luteoma)

Histopathology Comments:

The tumor appears to have some features of both tumors. Immunohistochemistry may be required for definitive diagnosis.

salivary gland (MA:0000346)

Histopath Description:

There is focal perivascular mononuclear inflammatory cells.

Morphological Diagnosis:

Distribution: focal; **Severity:** mild; **MPATH Diagnosis:** inflammation MPATH:212

Definitive Diagnosis:

Perivascular inflammatory aggregate

skin (MA:0000151)

Histopath Description:

There are low numbers of mononuclear and rare polymorphonuclear inflammatory cells within the dermis. The epidermis is mildly thickened. The hair follicles are at catagen stage. The hair follicle epithelium is hyperplastic.

Morphological Diagnosis:

Distribution: multifocal; **Severity:** mild; **MPATH Diagnosis:** inflammation MPATH:212

Definitive Diagnosis:

Dermatitis with epidermal and follicular epithelial hyperplasia

Histopathology Comments:

The lesion may explain the hair phenotype observed in this line

eye (MA:0000261)

Histopath Description:

There are multifocal clusters of cells within the internal and outer nuclear layer

Morphological Diagnosis:

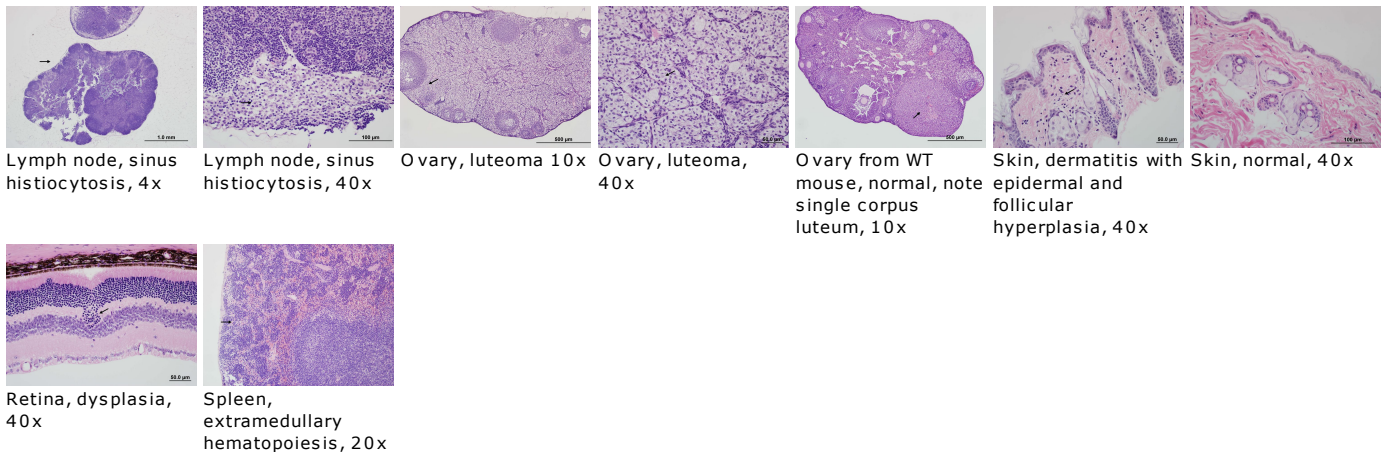
Distribution: multifocal; **Severity:** mild; **MPATH Diagnosis:** developmental and structural abnormality MPATH:55

Definitive Diagnosis:

Retinal dysplasia

Histopathology Comments:

varying severity of retinal dysplasia and degeneration are seen in C57BL/6N mice (Mattapallil et al., 2012),



There were no significant findings in the following tissues: Calvarium, brain, eyes, ears, tongue, Harderian gland, zymbal gland, nasal sinuses, teeth, trachea, lungs, heart, thymus, thyroid gland, parathyroid gland, gall bladder, exocrine and endocrine pancreas, esophagus, stomach, intestines, urinary organs and tract, adrenal gland, spinal cord, bones, bone marrow, skeletal muscles, brown fat.

AnimalID: M00313123

Tissue Preservation and Staining:

Skin samples are not well preserved.

Histopathology Findings:

mesenteric lymph node (MA:0002829)

Histopath Description:

The lymph node is markedly enlarged. The medullary and subcapsular sinuses contain large numbers of histiocytic cells. Lymphoid follicles are enlarged and contain germinal centers. The medullary sinuses contain large numbers of well differentiated mature lymphocytes

Morphological Diagnosis:

Distribution: multifocal to coalescing; **Severity:** moderate; **MPATH Diagnosis:** hyperplasia MPATH:134

Definitive Diagnosis:

Lymphoid hyperplasia with sinus histiocytosis; lymphoid hyperplasia

Histopathology Comments:

The lesion may explain the monocytosis observed

liver (MA:0000358)**Histopath Description:**

severe lipidosis,

Morphological Diagnosis:

Distribution: diffuse; **Severity:** severe; **MPATH Diagnosis:** lipid deposition MPATH:42

Definitive Diagnosis:

Hepatic lipidosis

ovary (MA:0000384)**Histopath Description:**

Within the ovary are multiple large corpora lutea that compress and replace more than two-thirds of the ovarian parenchyma. Follicles are rare and most appear primary degenerate follicles towards the medulla

Morphological Diagnosis:

Distribution: multifocal to coalescing; **Severity:** moderate; **MPATH Diagnosis:** hyperplasia MPATH:134

Definitive Diagnosis:

Luteal hyperplasia and hypertrophy

Histopathology Comments:

The luteal hyperplasia and hypertrophy appears to compromise follicular development and maturation

skin (MA:0000151)**Histopath Description:**

There are low numbers of mononuclear and rare polymorphonuclear inflammatory cells within the dermis. The epidermis is mildly thickened. The hair follicles are at anagen stage.

Morphological Diagnosis:

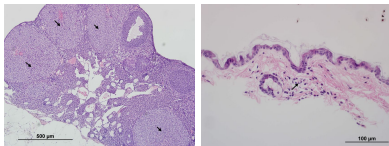
Distribution: multifocal; **Severity:** mild; **MPATH Diagnosis:** inflammation MPATH:212

Definitive Diagnosis:

Dermatitis with epidermal hyperplasia

Histopathology Comments:

The lesion may explain the hair phenotype observed in this line



Ovary, luteal hyperplasia and hypertrophy, 20x

Skin, dermatitis, 40x

There were no significant findings in the following tissues: Calvarium, brain, eyes, ears, tongue, Harderian gland, zymbal gland, salivary glands, nasal sinuses, teeth, trachea, lungs, heart, thymus, thyroid gland, parathyroid gland, spleen, gall bladder, exocrine and endocrine pancreas, esophagus, stomach, intestines, urinary organs and tract, adrenal gland, spinal cord, bones, bone marrow, skeletal muscles, brown fat.

Summary and Recommendation:

- Mild dermatitis (2/2 F) and hair follicular hyperplasia (1/2 F) may explain the abnormal hair cycle anagen phase
- No lesion was found to explain preweaning lethality
- Lymph node histiocytosis may explain increased monocyte cell numbers - Ovarian stromal tumor (luteoma/Sertoli cell tumor) (1/2 F) and luteal hyperplasia and hypertrophy (1/2 F) was observed; these changes have been associated with progressive loss of ovarian function in mutant mice (Mujoomdar et al., 2010). Further endogenous ovarian hormones (in this case likely progesterone) may be associated with secondary dermal conditions. Pruritic dermatitis resulting from hypersensitivity to endogenous sex hormones is recognized in women (autoimmune progesterone dermatitis) (Lee et al., 2011) and rarely in dogs (Scott et al., 1999). The vast majority of canine cases are in intact females, frequently with a history of irregular estrus or recurrent pseudopregnancy. We speculate that increased production of progesterone from luteoma and/or luteal hyperplasia/ hypertrophy may play a role in mild dermatitis observed in the two female mice. The skin lesions may also explain the abnormal hair cycle observed in female mice during phenotyping. The microscopic lesion in dogs is a hyperplastic superficial perivascular dermatitis in which neutrophils, mononuclear cells, or eosinophils may predominate (Ginn et al, 2007).

References:

Mattapallil MJ, Wawrousek EF, Chan CC, Zhao H, Roychoudhury J, Ferguson TA, Caspi RR. (2012). The Rd8 mutation of the Crb1 gene is present in vendor lines of C57BL/6N mice and embryonic stem cells, and confounds ocular induced mutant phenotypes. Invest Ophthalmol Vis Sci. 53:2921-2927. Mujoomdar ML et al (2010). Pcsk6 mutant mice exhibit progressive loss of ovarian function, altered gene expression, and formation of ovarian pathology. Reproduction. 2011, 141(3):343-55. Ginn P.E., Mansell J.E.K.L. & Rakich P.M. 2007. Skin and appendages, p.553-781. In: Maxie M.G. (Ed.), Jubb, Kennedy and Palmer's Pathology of Domestic Animals. Vol.1. 5th ed. W.B. Saunders, London.

Lee MK (2011). A Case of Autoimmune Progesterone Dermatitis Misdiagnosed as Allergic Contact Dermatitis. Allergy Asthma Immunol Res. 3(2): 141-144.

Scott, D. W., and Miller, W. H. Probable hormonal hypersensitivity in two male dogs. Canine Pract 17: 14-17, 20, 1999.