



CMHD Pathology Report



CMHD Pathology Core

Toronto Centre for
Phenogenomics
25 Orde St. 3rd fl.
Toronto, Ont. M5T 3H7
Tel.(416) 586-8375
Fax (416) 586-5993

contact: Dr. Susan
Newbigging
email:
newbigging@lunenfeld.ca

ReportID: Report Date: July 11, 2013
Pathologist: Dr. H. Adissu

Mouse Genetics Project

Wellcome Trust Sanger
Institute
Wellcome Trust Genome
Campus
Hinxton, Cambridge
CB10 1SA
UK

CMHD LabID: N13-471

Relevant History:

Phenotype:

increased CD4-positive T cell number
increased NK cell number
preweaning lethality
embryonic lethality
increased bone mineral content
increased bone strength

AnimalID: M00195663 (Male)

Histopathology Findings:

lymph node (MA:0000139)

Histopath Description:

The mesenteric lymph node is enlarged (greater than three-fold). There are multiple follicles with large germinal centers. The sinuses contain large numbers of mature lymphocytes. There are numerous large macrophages containing apoptotic bodies (tingible body macrophages).

Morphological Diagnosis:

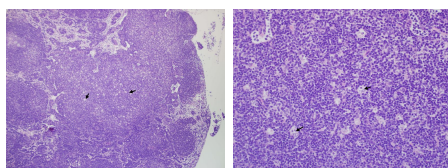
Duration: Sub-acute; **Distribution:** Diffuse; **Severity:** moderate; **MPATH Diagnosis:** hyperplasia MPATH:134

Definitive Diagnosis:

Lymphoid hyperplasia with sinus plasmacytosis

Histopathology Comments:

The changes in the mesenteric lymph node are suggestive of draining of a regional inflammatory process. However, such a process was not observed in the tissues examined.



Lymph node,
hyperplasia, 10x,
HE

Lymph node,
hyperplasia, arrows
indicate
macrophages
containing apoptotic
bodies, 40x, HE

lymph node (MA:0000139)

Histopath Description:

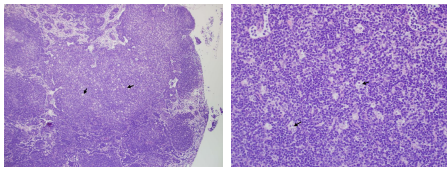
The mesenteric lymph node is enlarged more than two-fold. Its architecture is altered by large numbers of monomorphic lymphocytes that fill and distend all the sinuses and elevate the capsule. The neoplastic cells have generally a scant amount of eosinophilic cytoplasm, medium sized round central nucleus with granular chromatin, and single variably distinct amphophilic nucleoli. Mitotic figures are (less than 1/HPF). There are numerous large macrophages containing apoptotic bodies (tingible body macrophages).

Definitive Diagnosis:

Lymphoma

Histopathology Comments:

The lesion is suggestive of an early lymphoma of the mesenteric lymph node.

Lymph node,
hyperplasia, 10x,
HELymph node,
hyperplasia, arrows
indicate
macrophages
containing apoptotic
bodies, 40x, HE**liver (MA:0000358)****Histopath Description:**

moderate lipidosis

Morphological Diagnosis:**Distribution:** multifocal to coalescing; **Severity:** moderate; **MPATH Diagnosis:** steatosis
MPATH:622**Definitive Diagnosis:**

Hepatic lipidosis

stomach (MA:0000353)**Histopath Description:**

moderate neutrophilic gastritis

Morphological Diagnosis:**Distribution:** multifocal to coalescing; **Severity:** moderate;**Definitive Diagnosis:**

Gastritis, neutrophilic

Organ/Tissue Analyzed:

Histopathology examination included the following organs and tissues: brain, trigeminal ganglion, eyes, salivary glands, trachea, lungs, heart, thymus, thyroid gland, parathyroid gland, exocrine and endocrine pancreas, oesophagus, stomach, small intestine, large intestine, liver, gall bladder, spleen, kidneys, adrenal gland, lymph nodes, spinal cord, bone marrow, sternum, femur and tibia with associated skeletal muscles, brown fat, pinna, skin, testis, epididymis, seminal vesicle, and prostate.

AnimalID: M00195681 (Male)**Histopathology Findings:****lymph node (MA:0000139)****Histopath Description:**

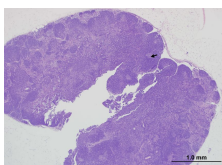
The mesenteric lymph node is enlarged (greater than 5 fold). There are multiple follicles with large germinal centers. The sinuses contain large numbers of mature lymphocytes.

Morphological Diagnosis:**Distribution:** Diffuse; **Severity:** extreme; **MPATH Diagnosis:** hyperplasia MPATH:134**Definitive Diagnosis:**

Lymphoid hyperplasia.

Histopathology Comments:

The changes in the mesenteric lymph node are suggestive of draining of a regional inflammatory process. However, such a process was not observed in the tissues examined.

Lymph node,
hyperplasia, 4x, HE

liver (MA:0000358)**Histopath Description:**

moderate lipidosis

Morphological Diagnosis:

Distribution: multifocal to coalescing; **Severity:** moderate; **MPATH Diagnosis:** steatosis
MPATH:622

Definitive Diagnosis:

Hepatic lipidosis

brain (MA:0000168)**Histopath Description:**

There is mild dilation of the lateral ventricles

Morphological Diagnosis:

Distribution: bilateral; **Severity:** mild;

Definitive Diagnosis:

Dilation of the brain ventricles

Histopathology Comments:

Mild dilation of the lateral ventricles is a background condition in mice of C57BL/6N background (Brayton et al., 2004).

brain (MA:0000168)**Histopath Description:**

There are clusters of granular neurons in the molecular layer

Morphological Diagnosis:

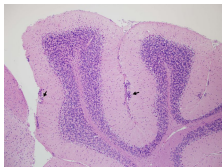
Distribution: multifocal;

Definitive Diagnosis:

Cerebellar granular neuron heterotopia

Histopathology Comments:

Heterotopia is a condition in which nerve cells (neurons) do not migrate properly during the early development of the fetal brain.



Cerebellum,
granular neurons,
heterotopia, 10x,
HE

Organ/Tissue Analyzed:

Histopathology examination included the following organs and tissues: brain, trigeminal ganglion, eyes, salivary glands, trachea, heart, thymus, thyroid gland, parathyroid gland, exocrine and endocrine pancreas, oesophagus, stomach, small intestine, large intestine, liver, gall bladder, spleen, kidneys, adrenal gland, lymph nodes, spinal cord, bone marrow, sternum, femur and tibia with associated skeletal muscles, brown fat, pinna, skin, testis, epididymis, seminal vesicle, and prostate.

AnimalID: M00195683 (Female)**Histopathology Findings:****lymph node (MA:0000139)****Histopath Description:**

The mesenteric lymph node is enlarged (greater than four-fold). There are multiple follicles with large germinal centers. The sinuses contain large numbers of mature lymphocytes.

Morphological Diagnosis:

Distribution: Diffuse; **Severity:** severe; **MPATH Diagnosis:** hyperplasia MPATH:134

Definitive Diagnosis:

Lymphoid hyperplasia.

Histopathology Comments:

The changes in the mesenteric lymph node are suggestive of draining of a regional inflammatory process. However, such a process was not observed in the tissues examined.

liver (MA:0000358)**Histopath Description:**

moderate lipidosis

Morphological Diagnosis:

Distribution: multifocal to coalescing; **Severity:** moderate; **MPATH Diagnosis:** steatosis
MPATH:622

Definitive Diagnosis:

Hepatic lipidosis

spleen (MA:0000141)**Histopath Description:**

moderate erythroid hyperplasia

Morphological Diagnosis:

Distribution: multifocal; **Severity:** moderate; **MPATH Diagnosis:** extramedullary hemopoiesis
MPATH:595

Definitive Diagnosis:

Splenic erythroid hyperplasia

stomach (MA:0000353)**Histopath Description:**

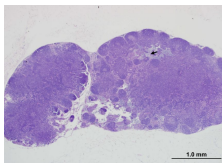
mild neutrophilic gastritis; there is also mild epithelial proteinosis

Morphological Diagnosis:

Distribution: multifocal; **Severity:** mild;

Definitive Diagnosis:

Mild neutrophilic gastritis with epithelial proteinosis



Lymph node,
hyperplasia, 4x, HE

Organ/Tissue Analyzed:

Histopathology examination included the following organs and tissues: brain, trigeminal ganglion, eyes, salivary glands, trachea, lungs, heart, thymus, thyroid gland, parathyroid gland, exocrine and endocrine pancreas, oesophagus, stomach, small intestine, large intestine, liver, gall bladder, spleen, kidneys, adrenal gland, lymph nodes, spinal cord, bone marrow, sternum, femur and tibia with associated skeletal muscles, brown fat, pinna, skin, uterus, oviduct, and ovary, and mammary gland.

AnimalID: M00195721 (Female)**Histopathology Findings:****lymph node (MA:0000139)****Histopath Description:**

The mesenteric lymph node is markedly enlarged (greater than five-fold). There are multiple follicles with large germinal centers. The sinuses contain large numbers of mature lymphocytes.

Morphological Diagnosis:

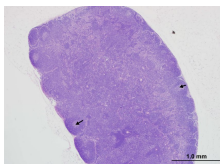
Distribution: Diffuse; **Severity:** extreme; **MPATH Diagnosis:** hyperplasia MPATH:134

Definitive Diagnosis:

Lymphoid hyperplasia.

Histopathology Comments:

The changes in the mesenteric lymph node are suggestive of draining of a regional inflammatory process. However, such a process was not observed in the tissues examined.



Lymph node,

hyperplasia, 4x, HE

liver (MA:0000358)**Histopath Description:**

diffuse lipidosis

Morphological Diagnosis:

Distribution: diffuse; **Severity:** severe; **MPATH Diagnosis:** steatosis MPATH:622

Definitive Diagnosis:

Hepatic lipidosis

thymus (MA:0000142)**Histopath Description:**

There is a 50 um diameter epithelial cyst.

Morphological Diagnosis:

Distribution: focal; **MPATH Diagnosis:** cyst MPATH:62

Definitive Diagnosis:

Epithelial cyst

Histopathology Comments:

This is a developmental abnormality commonly seen in mice.

eye (MA:0000261)**Histopath Description:**

Non pigmented

Definitive Diagnosis:

Non pigmented retina and uvea

brain (MA:0000168)**Histopath Description:**

There is mild dilation of the lateral ventricles

Morphological Diagnosis:

Distribution: bilateral; **Severity:** mild;

Definitive Diagnosis:

Dilation of the brain ventricles

Histopathology Comments:

Mild dilation of the lateral ventricles is a background condition in mice of C57BL/6N background (Brayton et al., 2004).

Organ/Tissue Analyzed:

Histopathology examination included the following organs and tissues: brain, trigeminal ganglion, eyes, salivary glands, trachea, lungs, heart, thymus, thyroid gland, parathyroid gland, exocrine and endocrine pancreas, oesophagus, stomach, small intestine, large intestine, liver, gall bladder, spleen, kidneys, adrenal gland, lymph nodes, spinal cord, bone marrow, sternum, femur and tibia with associated skeletal muscles, brown fat, pinna, skin, uterus, oviduct, and ovary, and mammary gland.

Report Summary and Recommendation:

The main finding in this line is marked to severe hyperplasia of the mesenteric lymph nodes in all mice. The lesion may explain the increased number in selected lymphocyte population. We did not find morphological correlate to the bone phenotypes. There are no findings predictive of embryonic mortality in this line; histopathology analysis of embryos is recommended.

Line summary: Lymph node - hyperplasia (marked to severe; 4/4)