



CMHD Pathology Report



CMHD Pathology Core

Toronto Centre for
Phenogenomics
25 Orde St. 3rd fl.
Toronto, Ont. M5T 3H7
Tel.(416) 586-8375
Fax (416) 586-5993

contact: Dr. Susan
Newbigging
email:
newbigging@lunenfeld.ca

ReportID: Report Date: January 24, 2013
Pathologist: H. Adissu

Mouse Genetics Project

Wellcome Trust Sanger
Institute
Wellcome Trust Genome
Campus
Hinxton, Cambridge
CB10 1SA
UK

CMHD LabID: N12-1504

Relevant History:

Phenotypes:

Vertebral fusion; fusion of vertebral arches

AnimalID: M00428038 (Male)

Tissue Preservation and Staining:

Tissues in block one were reembedded

Histopathology Findings:

brain (MA:0000168)

Morphological Diagnosis:

Distribution: bilateral; **Severity:** moderate; **MPATH Diagnosis:** hydrocephalus MPATH:639

Definitive Diagnosis:

moderate hydrocephalus of the lateral ventricles

liver (MA:0000358)

Morphological Diagnosis:

Distribution: diffuse; **Severity:** severe; **MPATH Diagnosis:** steatosis MPATH:622

Definitive Diagnosis:

Hepatic lipidosis, severe

pancreas (MA:0000120)

Histopath Description:

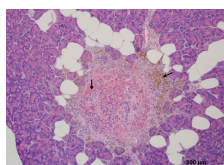
Focal hemorrhage with hemosiderin

Morphological Diagnosis:

Distribution: focal; **MPATH Diagnosis:** hemorrhagic necrosis MPATH:11

Definitive Diagnosis:

Focal hemorrhagic necrosis



Pancreas, Focal
hemorrhagic
necrosis, 20x

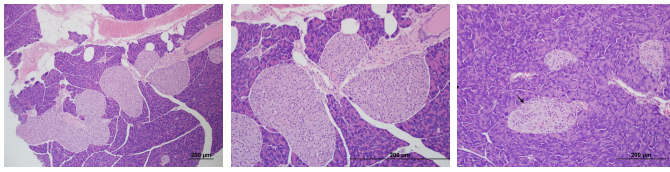
pancreas (MA:0000120)

Histopath Description:

Pancreatic islets are markedly enlarged.

Morphological Diagnosis:**Distribution:** multifocal; **Severity:** moderate;**Definitive Diagnosis:**

Islet cell hypertrophy

Pancreas islet,
hypertrophy, 10xPancreas islet,
hypertrophy, 20xPancreas islet, WT,
normal, 20x

Tectum-Abdomen
skin-Abdomen
blood vessel-
Abdomen

Organ/Tissue Analyzed:

Histopathology examination included the following organs and tissues: brain, trigeminal ganglion, eyes, salivary glands, trachea, lungs, heart, thymus, thyroid gland, parathyroid gland, exocrine and endocrine pancreas, oesophagus, stomach, small intestine, large intestine, liver, gall bladder, spleen, kidneys, adrenal gland, lymph nodes, spinal cord, bone marrow, sternum, femur and tibia with associated skeletal muscles, brown fat, pinna, skin, testis, epididymis, seminal vesicle, and prostate.

AnimalID: M00428039 (Male)**Tissue Preservation and Staining:**

Tissues in block one were reembedded

Histopathology Findings:**liver (MA:0000358)****Morphological Diagnosis:****Distribution:** diffuse; **Severity:** severe; **MPATH Diagnosis:** steatosis MPATH:622**Definitive Diagnosis:**

Hepatic lipidosis, severe

brain (MA:0000168)**Morphological Diagnosis:****Distribution:** bilateral; **Severity:** moderate; **MPATH Diagnosis:** hydrocephalus MPATH:639**Definitive Diagnosis:**

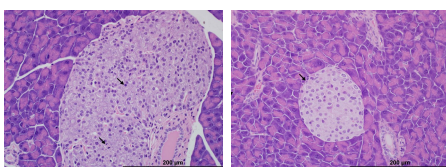
moderate hydrocephalus of the lateral ventricles

pancreatic islet (MA:0000127)**Histopath Description:**

There is mild enlargement of the pancreatic islets. Occasional mitotic figures are noted.

Morphological Diagnosis:**Distribution:** multifocal; **Severity:** mild;**Definitive Diagnosis:**

Pancreatic islet hypertrophy

Pancreas islet,
hypertrophy, 40xPancreas islet, WT,
normal, 40x

Organ/Tissue Analyzed:

Histopathology examination included the following organs and tissues: brain, trigeminal ganglion, eyes, salivary glands, trachea, lungs, heart, thymus, thyroid gland, parathyroid gland, exocrine and endocrine pancreas, oesophagus, stomach, small intestine, large intestine, liver, gall bladder, spleen, kidneys, adrenal gland, lymph nodes, spinal cord, bone marrow, sternum, femur and tibia with associated skeletal muscles, brown fat, pinna, skin, testis, epididymis, seminal vesicle, and prostate.

AnimalID: M00431632 (Female)**Tissue Preservation and Staining:**

Tissues in block one were reembedded

Histopathology Findings:**brain (MA:0000168)****Morphological Diagnosis:**

Distribution: bilateral; **Severity:** mild; **MPATH Diagnosis:** hydrocephalus MPATH:639

Definitive Diagnosis:

mild hydrocephalus of the lateral ventricles

liver (MA:0000358)**Morphological Diagnosis:**

Distribution: multifocal to coalescing; **Severity:** moderate; **MPATH Diagnosis:** steatosis MPATH:622

Definitive Diagnosis:

Hepatic lipidosis, moderate

stomach (MA:0000353)**Morphological Diagnosis:**

Distribution: multifocal; **Severity:** mild;

Definitive Diagnosis:

Gastritis, lymphoplasmacytic and neutrophilic with mucus cell hyperplasia

Organ/Tissue Analyzed:

Histopathology examination included the following organs and tissues: brain, trigeminal ganglion, eyes, salivary glands, trachea, lungs, heart, thymus, thyroid gland, parathyroid gland, exocrine and endocrine pancreas, esophagus, stomach, small intestine, large intestine, liver, gall bladder, spleen, kidneys, adrenal gland, lymph nodes, spinal cord, sternum, femur and tibia with associated skeletal muscles, brown fat, pinna, skin, uterus, oviduct, ovary, and mammary gland.

AnimalID: M00431631 (Female)**Tissue Preservation and Staining:**

Tissues in block one were reembedded

Histopathology Findings:**brain (MA:0000168)****Morphological Diagnosis:**

Distribution: bilateral; **Severity:** moderate; **MPATH Diagnosis:** hydrocephalus MPATH:639

Definitive Diagnosis:

moderate hydrocephalus of the lateral ventricles

liver (MA:0000358)**Morphological Diagnosis:**

Distribution: multifocal to coalescing; **Severity:** moderate; **MPATH Diagnosis:** steatosis MPATH:622

Definitive Diagnosis:

Hepatic lipidosis, moderate

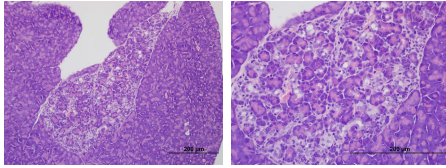
pancreas (MA:0000120)**Morphological Diagnosis:**

Duration: chronic-active; **Distribution:** focally extensive; **Severity:** mild;

Definitive Diagnosis:

Lobular atrophic pancreatitis**Histopathology Comments:**

This lesion is rarely seen in mice



Pancreas, lobular atrophic pancreatitis, 20x

Pancreas, lobular atrophic pancreatitis, 40x

Organ/Tissue Analyzed:

Histopathology examination included the following organs and tissues: brain, trigeminal ganglion, eyes, salivary glands, trachea, lungs, heart, thymus, thyroid gland, parathyroid gland, exocrine and endocrine pancreas, esophagus, stomach, small intestine, large intestine, liver, gall bladder, spleen, kidneys, adrenal gland, lymph nodes, spinal cord, sternum, femur and tibia with associated skeletal muscles, brown fat, pinna, skin, uterus, oviduct, ovary, and mammary gland.

Report Summary and Recommendation:

Incidental and background lesions are noted in this line. Hydrocephalus was noted in all mice in this line and in 3/4 mice the severity is more marked than usually seen in the controls and other lines we have examined thus far from this study. One mouse (M00428038) had a focal lobular neurohemorrhagic lesion while another (M00431631) had a lobular atrophic and inflammatory lesion. We are not certain of the significance of these local lesions. Two mice from these line (M00428038 and M00428038) had islet cell hypertrophy; in one of these mice the hypertrophy is associated with mitotic activity.