



# CMHD Pathology Report



## CMHD Pathology Core

Toronto Centre for  
Phenogenomics  
25 Orde St. 3rd fl.  
Toronto, Ont. M5T 3H7  
Tel.(416) 586-8375  
Fax (416) 586-5993

contact: Dr. Susan  
Newbigging  
email:  
[newbigging@lunenfeld.ca](mailto:newbigging@lunenfeld.ca)

ReportID: Report Date: May 07, 2013  
Pathologist: Dr. H. Adissu

## Mouse Genetics Project

Wellcome Trust Sanger  
Institute  
Wellcome Trust Genome  
Campus  
Hinxton, Cambridge  
CB10 1SA  
UK

CMHD LabID: N13-234

## Relevant History:

Phenotype:

decreased bone mineral density  
decreased body length  
decreased percent body fat  
decreased lean body mass  
decreased total body fat amount  
decreased body weight  
decreased bone mineral content  
kyphosis  
abnormal spine curvature  
decreased body weight  
decreased circulating cholesterol level  
increased energy expenditure  
increased oxygen consumption  
increased carbon dioxide production  
decreased circulating glucose level  
decreased CD8-positive, alpha-beta memory T cell number  
partial lethality  
embryonic growth retardation  
fetal edema  
preweaning lethality

---

## AnimalID: M00507120 (Male)

### Histopathology Findings:

#### thymus (MA:0000142)

##### Histopath Description:

There is a 100 um diameter epithelial cyst.

##### Morphological Diagnosis:

**Distribution:** focal; **MPATH Diagnosis:** cyst MPATH:62

##### Definitive Diagnosis:

Epithelial cyst

##### Histopathology Comments:

This is a developmental abnormality commonly seen in mice.

#### liver (MA:0000358)

##### Histopath Description:

minimal lipidosis

##### Morphological Diagnosis:

**Distribution:** multifocal; **Severity:** mild;

##### Definitive Diagnosis:

minimal lipidos

**sternal manubrium (MA:0001332)****Histopath Description:**

There is mild inflammation, fibroplasia, and marked multifocal regeneration within the sternal muscles.

**Morphological Diagnosis:**

**Duration:** chronic; **Distribution:** multifocal to coalescing;

**Definitive Diagnosis:**

Sternal myositis with myoregeneration and fibroplasia

**Histopathology Comments:**

The lesion suggests traumatic injury to the sternal muscle or a reactive response to pathological fracture following sternal osteochondritis.

**knee (MA:0000046)****Histopath Description:**

The overall subgross anatomical organization of the femur, tibia, and the knee joint are within normal limits. Histologically, there is focal fissure and fraying (fibrillation) the tibial articular cartilage.

**Morphological Diagnosis:**

**Duration:** chronic; **Distribution:** focally extensive; **Severity:** mild; **MPATH Diagnosis:** degenerative change MPATH:14

**Definitive Diagnosis:**

Mild fibrillation of the superficial zone of femoral articular cartilage - consistent with low grade degenerative joint disease (DJD)

**Histopathology Comments:**

The histological changes within the superficial articular cartilage are indicative of early and very mild DJD. The lesions are likely age-associated. DJD occurs in all inbred strains of mice as part of the aging process.

**kidney (MA:0000368)****Histopath Description:**

Rare tubules contain protein casts

**Morphological Diagnosis:**

**Distribution:** multifocal; **Severity:** mild;

**Definitive Diagnosis:**

Tubular protein casts

**Histopathology Comments:**

This change is consistent with low grade glomerulopathy (although affected glomeruli are not seen in the field examined). Glomerulopathy and subsequent tubular protein loss is seen as mice age.

**brain (MA:0000168)****Histopath Description:**

There is mild dilation of the lateral ventricles

**Morphological Diagnosis:**

**Distribution:** bilateral; **Severity:** mild;

**Definitive Diagnosis:**

Dilation of the brain ventricles

**Histopathology Comments:**

Mild dilation of the lateral ventricles is a background condition in mice of C57BL/6N background (Brayton et al., 2004).

---

**AnimalID: M00502734 (Male)****Histopathology Findings:****liver (MA:0000358)****Histopath Description:**

moderate lipidosis

**Morphological Diagnosis:**

**Distribution:** diffuse; **Severity:** severe; **MPATH Diagnosis:** steatosis MPATH:622

**Definitive Diagnosis:**

## Hepatic lipidosis

**lymph node (MA:0000139)****Histopath Description:**

The lymph node contains moderately prominent lymphoid nodules with prominent germinal centers. Occasional apoptotic bodies are present within germinal center freely or within the cytoplasm of macrophages. There are numerous mature lymphocytes and plasma cells within medullary sinuses.

**Morphological Diagnosis:**

**Distribution:** multifocal; **Severity:** mild; **MPATH Diagnosis:** hyperplasia MPATH:134

**Definitive Diagnosis:**

Lymphoid hyperplasia with sinus plasmacytosis

**sternal manubrium (MA:0001332)****Histopath Description:**

There is a partial sternal fracture. The chondroid tissue along the fracture is markedly degenerate. There is a nodular cartilagenous proliferation at the perichondrial margins (reactive reparative chondroid hyperplasia)

**Morphological Diagnosis:**

**Duration:** chronic; **Distribution:** focally extensive;

**Definitive Diagnosis:**

Sternal osteochondritis with fracture and reactive and reparative chondroid hyperplasia ('calus')

**kidney (MA:0000368)****Histopath Description:**

Rare tubules contain protein casts

**Morphological Diagnosis:**

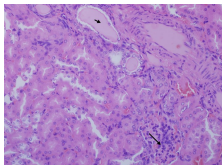
**Distribution:** multifocal; **Severity:** mild;

**Definitive Diagnosis:**

Tubular protein casts

**Histopathology Comments:**

This change is consistent with low grade glomerulopathy (although affected glomeruli are not seen in the field examined). Glomerulopathy and subsequent tubular protein loss is seen as mice age.



Kidney,  
glomerulopathy with  
tubular hyperplasia  
and protein cast

**retina (MA:0000276)****Histopath Description:**

Involving both eyes, there are clusters of external nuclear structures within the internal plexiform layer.

**Morphological Diagnosis:**

**Distribution:** Focal; **Severity:** mild;

**Definitive Diagnosis:**

Retinal dysplasia

---

**AnimalID: M00507124 (Female)****Histopathology Findings:****liver (MA:0000358)****Histopath Description:**

moderate lipidosis

**Morphological Diagnosis:**

**Distribution:** diffuse; **Severity:** severe; **MPATH Diagnosis:** steatosis MPATH:622

**Definitive Diagnosis:**

Hepatic lipidosis

**kidney (MA:0000368)**

**Histopath Description:**

There are occasional hyperplastic tubules that contain protein casts; these tubules are in close proximity to a hypercellular glomerulus (proliferative glomerulopathy).

**Morphological Diagnosis:**

**Distribution:** multifocal; **Severity:** mild;

**Definitive Diagnosis:**

Proliferative glomerulopathy with tubular hyperplasia and protein casts

**Histopathology Comments:**

This change is consistent with glomerulopathy and protein leakage. The lesion affects rare glomeruli hence its clinical significance is doubtful. Glomerulopathy and subsequent tubular protein loss is seen as mice age.

**lymph node (MA:0000139)**

**Histopath Description:**

The lymph node contains moderately prominent lymphoid nodules with prominent germinal centers. Occasional apoptotic bodies are present within germinal center freely or within the cytoplasm of macrophages. There are numerous mature lymphocytes and plasma cells within medullary sinuses.

**Morphological Diagnosis:**

**Distribution:** multifocal; **Severity:** mild; **MPATH Diagnosis:** hyperplasia MPATH:134

**Definitive Diagnosis:**

Lymphoid hyperplasia with sinus plasmacytosis

**brain (MA:0000168)**

**Histopath Description:**

There is mild dilation of the lateral ventricles

**Morphological Diagnosis:**

**Distribution:** bilateral; **Severity:** mild;

**Definitive Diagnosis:**

Dilation of the brain ventricles

**Histopathology Comments:**

Mild dilation of the lateral ventricles is a background condition in mice of C57BL/6N background (Brayton et al., 2004).

---

**AnimalID: M00601596 (Female)**

**Histopathology Findings:**

**liver (MA:0000358)**

**Histopath Description:**

minimal lipidosis

**Morphological Diagnosis:**

**Distribution:** multifocal; **Severity:** mild;

**Definitive Diagnosis:**

minimal lipidos

**retina (MA:0000276)**

**Histopath Description:**

Involving one eye, there are clusters of external nuclear structures within the internal plexiform layer.

**Morphological Diagnosis:**

**Distribution:** Focal; **Severity:** mild;

**Definitive Diagnosis:**

Retinal dysplasia

**brain (MA:0000168)****Histopath Description:**

There is mild dilation of the lateral ventricles

**Morphological Diagnosis:**

**Distribution:** bilateral; **Severity:** mild;

**Definitive Diagnosis:**

Dilation of the brain ventricles

**Histopathology Comments:**

Mild dilation of the lateral ventricles is a background condition in mice of C57BL/6N background (Brayton et al., 2004).

**Report Summary and Recommendation:**

Minimal hepatic lipidosis is observed in two mice consistent with decreased percent body fat, decreased circulating cholesterol level, and decreased body weight. Mild tubular protein loss with/or without minimal glomerulopathy is observed in three mice (M00507120, M00502734, and M00507124). We did not find morphological correlates to decreased numbers of CD8-positive, alpha-beta memory T cell number. Routine histopathology is not sensitive enough to detect variations in the population of classes and/or subclasses of lymphocytes within hemolymphatic tissues. We also did not find histological correlates to the metabolic and skeletal phenotypes in this line.