



CMHD Pathology Report



CMHD Pathology Core

Toronto Centre for
Phenogenomics
25 Orde St. 3rd fl.
Toronto, Ont. M5T 3H7
Tel.(416) 586-8375
Fax (416) 586-5993

contact: Dr. Susan
Newbigging
email:
newbigging@lunenfeld.ca

ReportID: Report Date: July 24, 2013
Pathologist: Dr. H. Adissu

Mouse Genetics Project

Wellcome Trust Sanger
Institute
Wellcome Trust Genome
Campus
Hinxton, Cambridge
CB10 1SA
UK

CMHD LabID: N13-488

Relevant History:

Phenotype:

increased susceptibility to bacterial infection
increased susceptibility to bacterial infection induced morbidity/mortality
abnormal body weight
abnormal cornea morphology
decreased survivor rate
increased pulmonary respiratory rate

AnimalID: M00909622 (Male)

Histopathology Findings:

thymus (MA:0000142)

Histopath Description:

There is a 50 um diameter epithelial cyst.

Morphological Diagnosis:

Distribution: focal; **MPATH Diagnosis:** cyst MPATH:62

Definitive Diagnosis:

Epithelial cyst

Histopathology Comments:

This is a developmental abnormality commonly seen in mice.

lymph node (MA:0000139)

Histopath Description:

The mesenteric lymph node is markedly enlarged (greater than five-fold). The medulla is expanded by chords and sheets of plasmotoid cells.

Morphological Diagnosis:

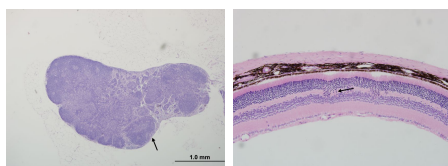
Distribution: Diffuse; **Severity:** severe; **MPATH Diagnosis:** hyperplasia MPATH:134

Definitive Diagnosis:

Lymphoid hyperplasia with medullary plasmacytosis.

Histopathology Comments:

The changes in the mesenteric lymph node are suggestive of draining of a regional inflammatory process. However, such a process was not observed in the tissues examined.



Lymph node,
hyperplasia, 4x

Eye, retina, retinal
dysplasia, 20x

liver (MA:0000358)

Histopath Description:

diffuse lipidosis

Morphological Diagnosis:**Distribution:** diffuse; **Severity:** extreme; **MPATH Diagnosis:** steatosis MPATH:622**Definitive Diagnosis:**

Moderate hepatic steatosis

testis (MA:0000411)**Histopath Description:**

There is a multifocal vacuolar degeneration and atrophy of the seminiferous tubule.

Morphological Diagnosis:**Distribution:** multifocal; **Severity:** mild;**Definitive Diagnosis:**

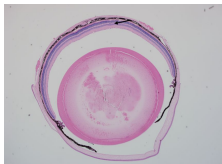
Testicular degeneration and atrophy

eye (MA:0000261)**Histopath Description:**

Involving one eye, there are clusters of external nuclear structures within the internal plexiform layer.

Morphological Diagnosis:**Distribution:** multifocal; **Severity:** mild;**Definitive Diagnosis:**

Retinal dysplasia



Eye, retina, retinal
dysplasia, 4x

Organ/Tissue Analyzed:

Histopathology examination included the following organs and tissues: brain, trigeminal ganglion, eyes, salivary glands, trachea, lungs, heart, thymus, thyroid gland, parathyroid gland, exocrine and endocrine pancreas, oesophagus, stomach, small intestine, large intestine, liver, gall bladder, spleen, kidneys, adrenal gland, lymph nodes, spinal cord, bone marrow, sternum, femur and tibia with associated skeletal muscles, brown fat, pinna, skin, testis, epididymis, seminal vesicle, and prostate.

AnimalID: M00906056 (Male)**Histopathology Findings:****thymus (MA:0000142)****Histopath Description:**

There is a 50 um diameter epithelial cyst.

Morphological Diagnosis:**Distribution:** focal; **MPATH Diagnosis:** cyst MPATH:62**Definitive Diagnosis:**

Epithelial cyst

Histopathology Comments:

This is a developmental abnormality commonly seen in mice.

lymph node (MA:0000139)**Histopath Description:**

The mesenteric lymph node is markedly enlarged (greater than seven-fold). The medulla is expanded by chords and sheets of plasmacytoid cells.

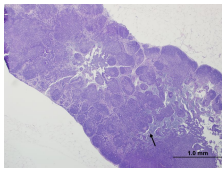
Morphological Diagnosis:**Distribution:** Diffuse; **Severity:** severe; **MPATH Diagnosis:** hyperplasia MPATH:134**Definitive Diagnosis:**

Lymphoid hyperplasia with medullary plasmacytosis.

Histopathology Comments:

The changes in the mesenteric lymph node are suggestive of draining of a regional inflammatory

process. However, such a process was not observed in the tissues examined.



Lymph node,
hyperplasia, 4x

liver (MA:0000358)

Histopath Description:

diffuse lipidosis

Morphological Diagnosis:

Distribution: diffuse; **Severity:** extreme; **MPATH Diagnosis:** steatosis MPATH:622

Definitive Diagnosis:

Moderate hepatic steatosis

stomach (MA:0000353)

Histopath Description:

The keratin layer is markedly thickened 3x normal

Morphological Diagnosis:

Distribution: focally extensive; **Severity:** severe; **MPATH Diagnosis:** hyperkeratosis MPATH:154

Definitive Diagnosis:

Hyperkeratosis

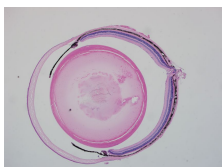
eye (MA:0000261)

Morphological Diagnosis:

Severity: no lesions;

Definitive Diagnosis:

Normal



Eye, normal, 4x

Organ/Tissue Analyzed:

Histopathology examination included the following organs and tissues: brain, trigeminal ganglion, eyes, salivary glands, trachea, lungs, heart, thymus, thyroid gland, parathyroid gland, exocrine and endocrine pancreas, oesophagus, stomach, small intestine, large intestine, liver, gall bladder, spleen, kidneys, adrenal gland, lymph nodes, spinal cord, bone marrow, sternum, femur and tibia with associated skeletal muscles, brown fat, pinna, skin, testis, epididymis, seminal vesicle, and prostate.

AnimalID: M00867562 (Female)

Histopathology Findings:

lymph node (MA:0000139)

Histopath Description:

The mesenteric lymph node is markedly enlarged (greater than three-fold). The medulla is expanded by chords and sheets of plasmacytoid cells.

Morphological Diagnosis:

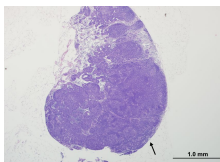
Distribution: Diffuse; **Severity:** moderate; **MPATH Diagnosis:** hyperplasia MPATH:134

Definitive Diagnosis:

Lymphoid hyperplasia with medullary plasmacytosis.

Histopathology Comments:

The changes in the mesenteric lymph node are suggestive of draining of a regional inflammatory process. However, such a process was not observed in the tissues examined.



Lymph node,
hyperplasia, 4x

liver (MA:0000358)

Histopath Description:

diffuse lipidosis

Morphological Diagnosis:

Distribution: diffuse; **Severity:** extreme; **MPATH Diagnosis:** steatosis MPATH:622

Definitive Diagnosis:

Moderate hepatic steatosis

eye (MA:0000261)

Histopath Description:

A 100-um long stretch of fibrous connective tissue extends from the area of the optic disc towards the posterior capsule of the lens.

Morphological Diagnosis:

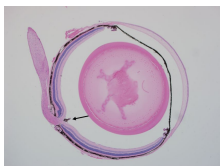
MPATH Diagnosis: developmental and structural abnormality MPATH:55

Definitive Diagnosis:

Persistent hyaloid artery

Histopathology Comments:

hyaloid artery remnant is a rare condition in which there remain some parts of the hyaloid artery. The posterior hyaloid vascular system of mice usually undergoes involution in the first month of life (Richard et al., 2000).



Eye, retina,
Persistent hyaloid
artery, 4x

salivary gland (MA:0000346)

Histopath Description:

There are multifocal perivascular mononuclear inflammatory cell aggregates.

Morphological Diagnosis:

Distribution: multifocal; **Severity:** mild;

Definitive Diagnosis:

Interstitial inflammatory aggregates

kidney (MA:0000368)

Histopath Description:

There are multifocal small perivascular aggregates of mononuclear inflammatory cells at the corticomedullary junction.

Morphological Diagnosis:

Duration: Chronic-active; **Distribution:** Focal; **Severity:** mild; **MPATH Diagnosis:** inflammation MPATH:212

Definitive Diagnosis:

Focal perivascular inflammatory aggregate.

Histopathology Comments:

This is a common incidental and insignificant lesion in mice

lung (MA:0000415)

Histopath Description:

There are rare small perivascular aggregates of mononuclear inflammatory cells in the lung.

Morphological Diagnosis:

Duration: Chronic; **Distribution:** Multifocal; **Severity:** mild; **MPATH Diagnosis:** inflammation

MPATH:212

Definitive Diagnosis:

Perivascular inflammatory aggregates

Histopathology Comments:

This lesion is suggestive of antigenic stimulation of hematogenous origin. It is a common and insignificant incidental finding.

brain (MA:0000168)**Histopath Description:**

There is moderate dilation of the lateral ventricles

Morphological Diagnosis:

Severity: moderate; **MPATH Diagnosis:** hydrocephalus MPATH:639

Organ/Tissue Analyzed:

Histopathology examination included the following organs and tissues: brain, trigeminal ganglion, eyes, salivary glands, trachea, lungs, heart, thymus, thyroid gland, parathyroid gland, exocrine and endocrine pancreas, oesophagus, stomach, small intestine, large intestine, liver, gall bladder, spleen, kidneys, adrenal gland, lymph nodes, spinal cord, bone marrow, sternum, femur and tibia with associated skeletal muscles, brown fat, pinna, skin, uterus, oviduct, and ovary, and mammary gland.

AnimalID: M00867561 (Female)**Histopathology Findings:****lymph node (MA:0000139)****Histopath Description:**

The mesenteric lymph node is markedly enlarged (greater than five-fold). The medulla is expanded by chords and sheets of plasmotoid cells.

Morphological Diagnosis:

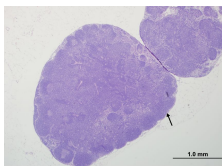
Distribution: Diffuse; **Severity:** severe; **MPATH Diagnosis:** hyperplasia MPATH:134

Definitive Diagnosis:

Lymphoid hyperplasia with medullary plasmacytosis.

Histopathology Comments:

The changes in the mesenteric lymph node are suggestive of draining of a regional inflammatory process. However, such a process was not observed in the tissues examined.



Lymph node,
hyperplasia, 4x, HE

liver (MA:0000358)**Histopath Description:**

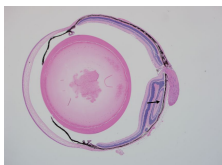
diffuse lipidosis

Morphological Diagnosis:

Distribution: diffuse; **Severity:** extreme; **MPATH Diagnosis:** steatosis MPATH:622

Definitive Diagnosis:

Moderate hepatic steatosis



Eye, retina, retinal
dysplasia, 4x

retina (MA:0000276)**Histopath Description:**

There is focally extensive marked retinal fold and disorganization

Morphological Diagnosis:

Distribution: focally extensive; **Severity:** moderate;

Definitive Diagnosis:

Retinal dysplasia

salivary gland (MA:0000346)

Histopath Description:

There are multifocal perivascular mononuclear inflammatory cell aggregates.

Morphological Diagnosis:

Distribution: multifocal; **Severity:** mild;

Definitive Diagnosis:

Interstitial inflammatory aggregates

brain (MA:0000168)

Histopath Description:

There is a 200 um diameter dermoid cyst within the hippocampal commissure. The cyst is keratin-filled and is lined by a well-differentiated simple squamous epithelium. The surrounding brain tissue is mildly compressed.

Morphological Diagnosis:

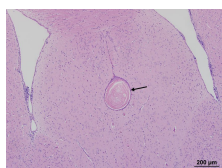
Distribution: Focal; **Severity:** mild; **MPATH Diagnosis:** dermoid cyst MPATH:311

Definitive Diagnosis:

Dermoid cyst (dermoid sinus)

Histopathology Comments:

Dermoid cyst is caused by defective epidermal closure along embryonic fissures isolating an island of ectoderm in the dermis or subcutis. The cyst was small with minimal compression of the surrounding brain tissue; its significance is uncertain.



Brain, medial septal nucleus, dermoid cyst, 10x, HE

Organ/Tissue Analyzed:

Histopathology examination included the following organs and tissues: brain, trigeminal ganglion, eyes, salivary glands, trachea, lungs, heart, thymus, thyroid gland, parathyroid gland, exocrine and endocrine pancreas, oesophagus, stomach, small intestine, large intestine, liver, gall bladder, spleen, kidneys, adrenal gland, lymph nodes, spinal cord, bone marrow, sternum, femur and tibia with associated skeletal muscles, brown fat, pinna, skin, uterus, oviduct, and ovary, and mammary gland.

Report Summary and Recommendation:

Marked lymph node hyperplasia was observed in all mice. The lesion may have significance in light of the increased susceptibility to bacterial infection.

There are no corneal abnormalities to corroborate abnormal cornea morphology. There is marked and mild retinal dysplasia in M00867561 and M00909622, respectively. No morphological correlates are apparent to explain abnormal body weight and increased pulmonary respiratory rate.

Summary: Retinal dysplasia (2/4, one marked); Lymph node hyperplasia (4/4).