



CMHD Pathology Report

**CMHD Pathology Core**

Toronto Centre for
Phenogenomics
25 Orde St. 3rd fl.
Toronto, Ont. M5T 3H7
Tel.(416) 586-8375
Fax (416) 586-5993

contact: Dr. Susan
Newbigging
email:
newbigging@lunenfeld.ca

ReportID: Report Date: March 12, 2013
Pathologist: H. Adissu

Mouse Genetics Project

Wellcome Trust Sanger
Institute
Wellcome Trust Genome
Campus
Hinxton, Cambridge
CB10 1SA
UK

CMHD LabID: N12-1520

Relevant History:

Phenotype:

preweaning lethality
embryonic lethality

AnimalID: M00433150

Tissue Preservation and Staining:

Skin tissue is fragmented with marked separation of dermal and subcutaneous tissues

Histopathology Findings:**liver (MA:0000358)****Histopath Description:**

Moderate lipidosis

Morphological Diagnosis:

Distribution: multifocal; **Severity:** moderate; **MPATH Diagnosis:** steatosis MPATH:622

Definitive Diagnosis:

Moderate hepatic steatosis

brain (MA:0000168)**Histopath Description:**

Mild hydrocephalus.

Morphological Diagnosis:

MPATH Diagnosis: hydrocephalus MPATH:639

Definitive Diagnosis:

Mild hydrocephalus of the lateral ventricles

AnimalID: M00433151

Tissue Preservation and Staining:

Skin tissue is fragmented with marked separation of dermal and subcutaneous tissues

Histopathology Findings:**gall bladder (MA:0000356)****Histopath Description:**

Gall bladder epithelial cells contain abundant proteinaceous material.

Morphological Diagnosis:

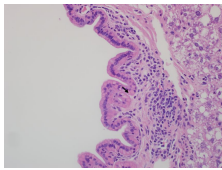
Distribution: diffuse; **Severity:** severe;

Definitive Diagnosis:

Epithelial proteinosis

Histopathology Comments:

This lesion is occasionally seen in B6 strains



Gall bladder,
epithelial
proteinosis, 40x

liver (MA:0000358)

Histopath Description:

Diffuse lipidosis

Morphological Diagnosis:

Distribution: diffuse; **Severity:** severe; **MPATH Diagnosis:** steatosis MPATH:622

Definitive Diagnosis:

Diffuse hepatic steatosis

knee joint (MA:0000471)

Histopath Description:

Mild fibrillation of the articular cartilage.

Morphological Diagnosis:

Distribution: focally extensive; **Severity:** mild; **MPATH Diagnosis:** degenerative change MPATH:14

Definitive Diagnosis:

Mild degenerative joint disease (osteoarthritis)

AnimalID: M00433152

Tissue Preservation and Staining:

Skin tissue is fragmented with marked separation of dermal and subcutaneous tissues

Histopathology Findings:

lymph node (MA:0000139)

Histopath Description:

The mesenteric lymph node is enlarged (greater than three-fold). There are multiple follicles with large germinal centers. The sinuses contain large numbers of mature lymphocytes.

Morphological Diagnosis:

Duration: Sub-acute; **Distribution:** Diffuse; **Severity:** moderate; **MPATH Diagnosis:** hyperplasia MPATH:134

Definitive Diagnosis:

Lymphoid hyperplasia.

Histopathology Comments:

The changes in the mesenteric lymph node are suggestive of draining of a regional inflammatory process. However, such a process was not observed in the tissues examined.

liver (MA:0000358)

Histopath Description:

Diffuse lipidosis

Morphological Diagnosis:

Distribution: diffuse; **Severity:** severe; **MPATH Diagnosis:** steatosis MPATH:622

Definitive Diagnosis:

Diffuse hepatic steatosis

spleen (MA:0000141)

Histopath Description:

moderate erythroid extramedullary hematopoiesis

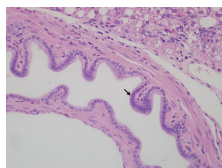
Morphological Diagnosis:

Distribution: multifocal to coalescing; **Severity:** moderate; **MPATH Diagnosis:** extramedullary

hemopoiesis MPATH:595

Definitive Diagnosis:

moderate erythroid extramedullary hematopoiesis



Gall bladder,
normal, 40x

AnimalID: M00433153

Tissue Preservation and Staining:

Skin tissue is fragmented with marked separation of dermal and subcutaneous tissues

Histopathology Findings:

liver (MA:0000358)

Histopath Description:

Diffuse lipidosis

Morphological Diagnosis:

Distribution: diffuse; **Severity:** severe; **MPATH Diagnosis:** steatosis MPATH:622

Definitive Diagnosis:

Diffuse hepatic steatosis

stomach (MA:0000353)

Histopath Description:

moderate neutrophilic gastritis

Morphological Diagnosis:

Distribution: multifocal to coalescing; **Severity:** moderate;

Definitive Diagnosis:

Gastritis, neutrophilic

brain (MA:0000168)

Histopath Description:

Mild hydrocephalus.

Morphological Diagnosis:

MPATH Diagnosis: hydrocephalus MPATH:639

Definitive Diagnosis:

Mild hydrocephalus of the lateral ventricles

Report Summary and Recommendation:

Incidental lesions attributable to diet or strain background are observed in this line. There are no lesions to explain preweaning/embryonic lethality in this line. Pathology analysis of embryos and pups from this line may explain embryonic and preweaning lethality.