



# CMHD Pathology Report



## CMHD Pathology Core

Toronto Centre for  
Phenogenomics  
25 Orde St. 3rd fl.  
Toronto, Ont. M5T 3H7  
Tel.(416) 586-8375  
Fax (416) 586-5993

contact: Dr. Susan  
Newbigging  
email:  
[newbigging@lunenfeld.ca](mailto:newbigging@lunenfeld.ca)

ReportID: Report Date: November 23,  
2011  
Pathologist: H. Adissu

## Mouse Genetics Project

Wellcome Trust Sanger  
Institute  
Wellcome Trust Genome  
Campus  
Hinxton, Cambridge  
CB10 1SA  
UK

CMHD LabID: N11-194

## Relevant History:

(Haematology (CBC)) Decreased MCH and MCHC

## AnimalID: M00326860 EPS15 Homo

### Tissue Preservation and Staining:

There is artifactual separation of the dermis and hypodermis. Tissues not present in submission: Calvarium, ears, tongue, Harderian gland, zymbal gland, nasal sinuses, teeth, gall bladder.

### Histopathology Findings:

#### lymph node (MA:0000139)

##### Histopath Description:

The mesenteric lymph node is enlarged (greater than two-fold). There are multiple follicles with large germinal centers. The sinuses contain large numbers of mature lymphocytes. The subcapsular sinuses contain large numbers of lymphocytes that multifocally elevate the capsule.

##### Morphological Diagnosis:

**Duration:** Sub-acute; **Distribution:** Diffuse; **Severity:** moderate; **MPATH Diagnosis:** hyperplasia MPATH:134

##### Definitive Diagnosis:

Lymphoid hyperplasia.

##### Histopathology Comments:

The changes in the mesenteric lymph node are suggestive of draining of a regional inflammatory process. However, such a process was not observed in the tissues examined.

#### liver (MA:0000358)

##### Histopath Description:

The overall hepatic lobular architecture is normal. Diffusely, hepatocytes contain intracytoplasmic clear vacuoles (lipid). The lipid vacuoles within the midzonal and periacinar regions are small (2-3 um in diameter) and surround a central nucleus (interpreted as microvesicular lipid). The lipid vacuoles within the portal areas are large (8-12 um in diameter) and displace the nucleus to the margin (macrovesicular lipid). There is a small (100x200 um) focal necrosis surrounded by numerous neutrophils.

##### Morphological Diagnosis:

**Distribution:** Diffuse; **Severity:** moderate; **MPATH Diagnosis:** lipid deposition MPATH:42

##### Definitive Diagnosis:

Hepatic lipidosis with focal hepatic coagulative necrosis

##### Histopathology Comments:

Hepatocellular vacuolar change of variable degree suggestive of lipidosis is present in all mice from WTSI, consistent with high lipid diet.

#### stomach (MA:0000353)

##### Histopath Description:

There are rare neutrophils and eosinophils within the lamina propria of the glandular region at the limiting ridge.

**Morphological Diagnosis:**

**Duration:** Sub-acute; **Distribution:** Multifocal; **Severity:** mild; **MPATH Diagnosis:** inflammation MPATH:212

**Definitive Diagnosis:**

Gastritis, suppurative

**Histopathology Comments:**

This lesion is most commonly associated with Helicobacter infection. Further investigation is suggested using histochemistry (Silver stain) or colony fecal PCR.

**skin (MA:0000151)****Histopath Description:**

There is a focal serocellular crust overlying a focal hyperplastic epidermis.

**Morphological Diagnosis:**

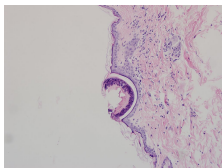
**Duration:** Chronic; **Distribution:** Focal; **Severity:** mild; **MPATH Diagnosis:** inflammation MPATH:212

**Definitive Diagnosis:**

Focal serocellular exudate and epidermal hyperplasia (epidermitis)

**Histopathology Comments:**

The lesion is typical of a healing skin wound.



Skin, epidermitis,  
20x

**brain (MA:0000168)****Histopath Description:**

There is a mild enlargement of the lateral ventricle.

**Morphological Diagnosis:**

**Severity:** mild; **MPATH Diagnosis:** hydrocephalus MPATH:639

**Definitive Diagnosis:**

hydrocephalus, third ventricle

**Histopathology Comments:**

Variable degree of hydrocephalus is observed in a proportion of wild type C57 Black 6 mice.

**Organ/Tissue Analyzed:**

NSF will be appended

**AnimalID: M00326865 EPS15 Homo****Tissue Preservation and Staining:**

There is artifactual separation of the dermis and hypodermis. The thyroid gland is not present in section. Tissues not present in submission: Calvarium, ears, tongue, Harderian gland, zymbal gland, nasal sinuses, teeth, gall bladder.

**Histopathology Findings:****liver (MA:0000358)****Histopath Description:**

The overall hepatic lobular architecture is normal. Nearly 10 of hepatocytes notably within the midzonal region contain large (8-12 um in diameter) intracytoplasmic clear vacuoles (macrovesicular lipid).

**Morphological Diagnosis:**

**Distribution:** Multifocal; **Severity:** mild; **MPATH Diagnosis:** lipid deposition MPATH:42

**Definitive Diagnosis:**

Hepatic lipidosis; multifocal inflammatory foci

**Histopathology Comments:**

Hepatocellular vacuolar change of variable degree suggestive of lipidosis is present in all mice from WTSI, consistent with high lipid diet. The lipidosis in this mouse is less severe.

**stomach (MA:0000353)**

**Histopath Description:**

There are rare neutrophils and eosinophils within the lamina propria of the glandular region at the limiting ridge.

**Morphological Diagnosis:**

**Duration:** Sub-acute; **Distribution:** Multifocal; **Severity:** mild; **MPATH Diagnosis:** inflammation MPATH:212

**Definitive Diagnosis:**

Gastritis, suppurative

**Histopathology Comments:**

This lesion is most commonly associated with Helicobacter infection. Further investigation is suggested using histochemistry (Silver stain) or colony fecal PCR.

**Organ/Tissue Analyzed:**

NSF will be appended

**AnimalID: M00326867 EPS15 Homo****Tissue Preservation and Staining:**

There is artifactual separation of the dermis and hypodermis. The thyroid gland is not present in section. Tissues not present in submission: Calvarium, ears, tongue, Harderian gland, zymbal gland, nasal sinuses, teeth, gall bladder.

**Histopathology Findings:****liver (MA:0000358)****Histopath Description:**

The overall hepatic lobular architecture is normal. Nearly 10 of hepatocytes notably within the midzonal region contain large (8-12 um in diameter) intracytoplasmic clear vacuoles (macrovesicular lipid).

**Morphological Diagnosis:**

**Distribution:** Multifocal; **Severity:** mild; **MPATH Diagnosis:** lipid deposition MPATH:42

**Definitive Diagnosis:**

Hepatic lipidosis; multifocal inflammatory foci

**Histopathology Comments:**

Hepatocellular vacuolar change of variable degree suggestive of lipidosis is present in all mice from WTSI, consistent with high lipid diet. The lipidosis in this mouse is less severe.

**stomach (MA:0000353)****Histopath Description:**

There is hyalinized protein accumulation within occasional gastric gland epithelial cells at the limiting ridge.

**Morphological Diagnosis:**

**Distribution:** Multifocal; **Severity:** mild; **MPATH Diagnosis:** hyalinosis MPATH:40

**Definitive Diagnosis:**

Gastric epithelial hyalinosis

**Histopathology Comments:**

This is a common incidental lesion in some mice strains, including B6.

**ear skin (MA:0001233)****Histopath Description:**

There is focal mild perivascular dermatitis with hyperplasia of the overlying epidermis

**Morphological Diagnosis:**

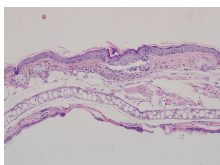
**Distribution:** Focal; **Severity:** mild; **MPATH Diagnosis:** dermatitis MPATH:196

**Definitive Diagnosis:**

Focal perivascular dermatitis with mild epidermal hyperplasia (acanthosis)

**Histopathology Comments:**

Lesion is likely a consequence of focal trauma.



Ear skin, focal

dermatitis with  
epidermal  
hyperplasia, 20x

#### Organ/Tissue Analyzed:

NSF will be appended

#### AnimalID: M00326870 EPS15 Homo

#### Tissue Preservation and Staining:

There is artifactual separation of the dermis and hypodermis. The thyroid gland is not present in section. Tissues not present in submission: Calvarium, ears, tongue, Harderian gland, zymbal gland, nasal sinuses, teeth, gall bladder.

#### Histopathology Findings:

##### mesenteric lymph node: The lymph node is enlarged (MA:0002829)

#### Histopath Description:

The mesenteric lymph node is enlarged nearly 2x normal. Multiple large and coalescing germinal centers with predominantly large lymphoblastic cells are present. The lymphocytes have scant cytoplasm, large round to oval nucleus with fine chromatin and prominent 1 or 2 nucleoli. Mitosis and apoptosis is frequently seen.

#### Morphological Diagnosis:

**Distribution:** Multifocal to coalescing; **Severity:** moderate; **MPATH Diagnosis:** hyperplasia  
MPATH:134

#### Definitive Diagnosis:

Lymphoid hyperplasia of the germinal centers.

#### Histopathology Comments:

The marked enlargement of the germinal centers with proliferative large lymphocytes is concerning for an early lymphoblastic type of malignant lymphoma. Features such as "starry sky", normally found in lymphoblastic lymphomas are not seen.

##### salivary gland (MA:0000346)

#### Histopath Description:

There are multifocal interstitial aggregate of histiocytes and lymphocytes.

#### Morphological Diagnosis:

**Duration:** Chronic; **Distribution:** Multifocal; **Severity:** mild; **MPATH Diagnosis:** inflammation  
MPATH:212

#### Definitive Diagnosis:

Interstitial histiocytic and lymphocytic sialadenitis

#### Histopathology Comments:

This is a common and insignificant incidental finding in mice.

#### Organ/Tissue Analyzed:

NSF will be appended

#### Report Summary and Recommendation:

Two mice in this line have focal inflammatory and hyperplastic skin lesions. These lesions, if extensive and chronic, may contribute to anemia of inflammatory disease. However such anemia is typically characterized by normochromacia rather than hypochromacia (note low mean corpuscular hemoglobin (MCH) and mean corpuscular hemoglobin concentration (MCHC) reported in this line). Bone marrow histology did not reveal morphological correlate for the low MCHC. Other lesions are considered incidental and/or attributable to background strain.

Skin: chronic inflammation MPATH:214