



CMHD Pathology Report



CMHD Pathology Core

Toronto Centre for
Phenogenomics
25 Orde St. 3rd fl.
Toronto, Ont. M5T 3H7
Tel.(416) 586-8375
Fax (416) 586-5993

contact: Dr. Susan
Newbigging
email:
newbigging@lunenfeld.ca

ReportID: Report Date: June 05, 2013
Pathologist: Dr. H. Adissu

Mouse Genetics Project

Wellcome Trust Sanger
Institute
Wellcome Trust Genome
Campus
Hinxton, Cambridge
CB10 1SA
UK

CMHD LabID: N13-250

Relevant History:

Phenotype:

polyuria
abnormal snout morphology
short snout
snout asymmetry
decreased body weight
decreased lean body mass
decreased body weight
decreased red blood cell distribution width
increased mean corpuscular hemoglobin concentration
increased energy expenditure
increased oxygen consumption
increased carbon dioxide production
decreased vertical activity
abnormal posture
decreased thoracic vertebrae number
vertebral transformation
decreased rib number
decreased mature B cell number
partial lethality
abnormal fertility/fecundity
chromosomal instability

AnimalID: M00532111 (Male)

Histopathology Findings:

testis (MA:0000411)

Histopath Description:

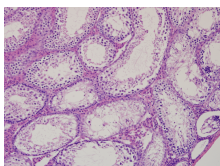
There is a diffuse vacuolar degeneration and atrophy of the seminiferous tubules affecting all of the testis. Seminiferous tubules lack maturing spermatids and spermatocytes. The epididymis contains no fewer spermatocytes.

Morphological Diagnosis:

Distribution: multifocal; **Severity:** moderate;

Definitive Diagnosis:

Testicular degeneration and atrophy with epididymal aspermia



Testis ,
degeneration and
atrophy, 20x, HE

liver (MA:0000358)

Histopath Description:

mild lipidosis

Morphological Diagnosis:**Distribution:** multifocal; **Severity:** severe;**Definitive Diagnosis:**

Hepatic lipidosis

thymus (MA:0000142)**Histopath Description:**

There is a 100 um diameter epithelial cyst.

Morphological Diagnosis:**Distribution:** focal; **MPATH Diagnosis:** cyst MPATH:62**Definitive Diagnosis:**

Epithelial cyst

Histopathology Comments:


This is a developmental abnormality commonly seen in mice.

bone marrow (MA:0000134)**Histopath Description:**

Mild erythroid hypoplasia

Morphological Diagnosis:**Severity:** mild;**Definitive Diagnosis:**

Erythroid hypoplasia

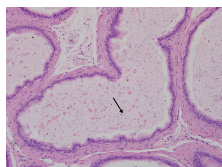
Bone marrow,
erythroid
hypoplasia, 40x, HE

AnimalID: M00537297 (Male)**Histopathology Findings:****testis (MA:0000411)****Histopath Description:**

There is a diffuse vacuolar degeneration and atrophy of the seminiferous tubules affecting all of the testis. Seminiferous tubules lack maturing spermatids and spermatocytes. The epididymis contains no fewer spermatocytes.

Morphological Diagnosis:**Distribution:** multifocal; **Severity:** moderate;**Definitive Diagnosis:**

Testicular degeneration and atrophy with epididymal aspermia

Epididymis,
aspermia, 20x, HE**liver (MA:0000358)****Histopath Description:**

Diffuse lipidosis

Morphological Diagnosis:**Distribution:** diffuse; **Severity:** severe; **MPATH Diagnosis:** steatosis MPATH:622**Definitive Diagnosis:**

Hepatic lipidosis

pancreatic lymph node (MA:0002881)**Histopath Description:**


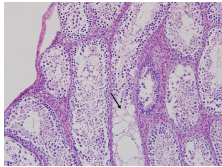
early germinal center lymphoma

Morphological Diagnosis:**MPATH Diagnosis:** lymphoid neoplasms MPATH:513**Definitive Diagnosis:**

Marginal center lymphoma, early

bone marrow (MA:0000134)**Morphological Diagnosis:****Severity:** no lesions;**Definitive Diagnosis:**

No significant finding

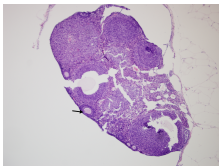
Bone marrow,
normal, 40x, HETestis ,
degeneration and
atrophy, 20x, HE

AnimalID: M00532116 (Female)**Histopathology Findings:****ovary (MA:0000384)****Histopath Description:**

Very few growing/maturing follicles

Definitive Diagnosis:

Ovarian hypoplasia (follicular hypoplasia)

Ovary, hypoplasia,
10x, HE**liver (MA:0000358)****Histopath Description:**

diffuse lipidosis

Morphological Diagnosis:**Distribution:** diffuse; **Severity:** severe; **MPATH Diagnosis:** steatosis MPATH:622**Definitive Diagnosis:**

Hepatic lipidosis

mesenteric lymph node (MA:0002829)**Histopath Description:**

Germinal center lymphoma

Morphological Diagnosis:**MPATH Diagnosis:** lymphoid neoplasms MPATH:513**Definitive Diagnosis:**

Marginal center lymphoma

bone marrow (MA:0000134)**Morphological Diagnosis:****Severity:** no lesions;**Definitive Diagnosis:**

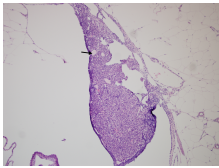
No significant finding

Bone marrow,
normal, 40x, HE**AnimalID: M00616640 (Female)****Histopathology Findings:****ovary (MA:0000384)****Histopath Description:**

Very few growing/maturing follicles

Definitive Diagnosis:

Ovarian hypoplasia (follicular hypoplasia)

Ovary, hypoplasia,
10x, HE**liver (MA:0000358)****Histopath Description:**

Diffuse lipidosis

Morphological Diagnosis:**Distribution:** diffuse; **Severity:** severe; **MPATH Diagnosis:** steatosis MPATH:622**Definitive Diagnosis:**

Hepatic lipidosis

kidney (MA:0000368)**Histopath Description:**

Perivascular mononuclear inflammatory cell infiltrates

Morphological Diagnosis:**Duration:** chronic; **Distribution:** multifocal; **Severity:** mild;**Definitive Diagnosis:**

Perivascular mononuclear inflammatory aggregates

bone marrow (MA:0000134)**Histopath Description:**

Mild erythroid hypoplasia

Morphological Diagnosis:**Severity:** mild;**Definitive Diagnosis:**

Erythroid hypoplasia



Bone marrow,
erythroid
hypoplasia, 40x, HE

Report Summary and Recommendation:

There is testicular atrophy/degeneration and ovarian hypoplasia in this line consistent with infertility phenotype. Mild erythroid hypoplasia was noted in the bone marrow in two mice. We did not observe lesions to explain the other phenotypes documented in this line.