



CMHD Pathology Report



CMHD Pathology Core

Toronto Centre for
Phenogenomics
25 Orde St. 3rd fl.
Toronto, Ont. M5T 3H7
Tel.(416) 586-8375
Fax (416) 586-5993

contact: Dr. Susan
Newbigging
email:
newbigging@lunenfeld.ca

ReportID: Report Date: November 23,
2011
Pathologist: H. Adissu

Mouse Genetics Project

Wellcome Trust Sanger
Institute
Wellcome Trust Genome
Campus
Hinxton, Cambridge
CB10 1SA
UK

CMHD LabID: N11-84

Relevant History:

faxitron and MCT - increased trabecular bone thickness and decreased trabecular bone number

AnimalID: M00244669 Abhd5 -/-

Tissue Preservation and Staining:

Tissues not present in submission: Calvarium, ears, tongue, Harderian gland, zymbal gland, nasal sinuses, teeth, gall bladder.

Histopathology Findings:

adrenal gland: Zona reticularis (MA:0000116)

Morphological Diagnosis:

Duration: Chronic; **Distribution:** Bilateral; **Severity:** moderate; **MPATH Diagnosis:** inflammation MPATH:212

Definitive Diagnosis:

Vacuolar degeneration of the involuting X zone with mononuclear inflammatory infiltrates.

Histopathology Comments:

This lesion is commonly seen in mature adult female mice. The inflammatory infiltrate is likely part of a clean up process, rather than a primary adrenalitis.

liver (MA:0000358)

Histopath Description:

The overall hepatic lobular architecture is normal. Less than 5% of hepatocytes within the midzonal region contain large (8-12 um in diameter) intracytoplasmic clear vacuoles (macrovesicular lipid). Rare small clusters of lymphocytes are present.

Morphological Diagnosis:

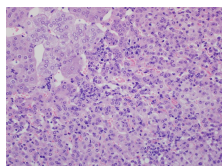
Distribution: Multifocal; **Severity:** mild; **MPATH Diagnosis:** lipid deposition MPATH:42

Definitive Diagnosis:

Hepatic lipidosi

Histopathology Comments:

Hepatocellular vacuolar change of variable degree suggestive of lipidosi is present in all mice from WTSI, consistent with high lipid diet. The changes in this mouse are less severe.



Adrenal gland,
Vacuolar
degeneration of the
involuting X zone
with mononuclear

inflammatory
infiltrates. 40x, HE.

Organ/Tissue Analyzed:

There were no significant findings in the following tissues: Brain, eyes, salivary glands, trachea, lungs, heart, thymus, thyroid gland, parathyroid gland, spleen, exocrine and endocrine pancreas, esophagus, stomach, intestines, urinary organs and tract, adrenal gland, reproductive organs, lymph nodes, spinal cord, bones, bone marrow, skeletal muscles, brown fat, and skin.

AnimalID: M00244703 Abhd5 -/-

Tissue Preservation and Staining:

Tissues not present in submission: Calvarium, ears, tongue, Harderian gland, zymbal gland, nasal sinuses, teeth, gall bladder.

Histopathology Findings:

kidney (MA:0000368)

Histopath Description:

There is a focal aggregate of lymphocytes and histiocytes within the submucosa of the renal pelvis.

Morphological Diagnosis:

Duration: Chronic; **Distribution:** Focal; **Severity:** mild; **MPATH Diagnosis:** inflammation MPATH:212

Definitive Diagnosis:

Chronic focal pyelonephritis.

Histopathology Comments:

This is a common incidental lesion of minimal significance.

liver (MA:0000358)

Histopath Description:

The overall hepatic lobular architecture is normal. Diffusely, hepatocytes contain intracytoplasmic clear vacuoles (lipid). The lipid vacuoles within the midzonal and periportal regions are small (2-3 um in diameter) and surround a central nucleus (interpreted as microvesicular lipid). The lipid vacuoles within the portal areas are large (8-12 um in diameter) and displace the nucleus to the margin (macrovesicular lipid).

Morphological Diagnosis:

Distribution: Diffuse; **Severity:** moderate; **MPATH Diagnosis:** lipid deposition MPATH:42

Definitive Diagnosis:

Hepatic lipodosis

Histopathology Comments:

Hepatocellular vacuolar change of variable degree suggestive of lipodosis is present in all mice from WTSI, consistent with high lipid diet.

stomach (MA:0000353)

Histopath Description:

There are low numbers of neutrophils within the deep lamina propria.

Morphological Diagnosis:

Duration: Sub-acute; **Distribution:** Multifocal; **Severity:** mild; **MPATH Diagnosis:** inflammation MPATH:212

Definitive Diagnosis:

Gastritis, suppurative

Histopathology Comments:

The lesion is likely caused by Helicobacter infection

Organ/Tissue Analyzed:

There were no significant findings in the following tissues: Brain, eyes, salivary glands, trachea, lungs, heart, thymus, thyroid gland, parathyroid gland, spleen, exocrine and endocrine pancreas, esophagus, intestines, adrenal gland, reproductive organs, lymph nodes, spinal cord, bones, bone marrow, skeletal muscles, brown fat, and skin.

AnimalID: M00244705 Abhd5 -/-

Tissue Preservation and Staining:

Tissues not present in submission: Calvarium, ears, tongue, Harderian gland, zymbal gland, nasal sinuses, teeth, gall bladder.

Histopathology Findings:

thymus (MA:0000142)**Histopath Description:**

Within this mass are present two cystic structures (100 and 500 um in diameter). The larger cyst is partially lined by low cuboidal to squamous epithelium. The small cyst is lined by vacuolated high columnar epithelium. Both contain small granular flocculent lightly eosinophilic material within the lumina. Few foamy macrophages are present within the larger cyst.

Morphological Diagnosis:

Duration: Other; **Distribution:** Multifocal; **Severity:** mild; **MPATH Diagnosis:** developmental and structural abnormality MPATH:55

Definitive Diagnosis:

Thymic cysts (suspect ultimobranchial cysts)

Histopathology Comments:

Epithelial lined cysts are common incidental findings in laboratory mice.

liver (MA:0000358)**Histopath Description:**

The overall hepatic lobular architecture is normal. Diffusely, hepatocytes contain intracytoplasmic clear vacuoles (lipid). The lipid vacuoles within the midzonal and periportal regions are small (2-3 um in diameter) and surround a central nucleus (interpreted as microvesicular lipid). The lipid vacuoles within the portal areas are large (8-12 um in diameter) and displace the nucleus to the margin (macrovesicular lipid).

Morphological Diagnosis:

Distribution: Diffuse; **Severity:** moderate; **MPATH Diagnosis:** lipid deposition MPATH:42

Definitive Diagnosis:

Hepatic lipidosis

Histopathology Comments:

Hepatocellular vacuolar change of variable degree suggestive of lipidosis is present in all mice from WTSI, consistent with high lipid diet.

testis (MA:0000411)**Histopath Description:**

Diffusely, sertoli cells contain a single large, 20-25 um in diameter, intracytoplasmic clear vacuole that displaces the nucleus to the margin (macrovesicular lipid). Lipid vacuoles are also present within the epididymal lumen.

Morphological Diagnosis:

Distribution: Diffuse; **Severity:** moderate; **MPATH Diagnosis:** lipid deposition MPATH:42

Definitive Diagnosis:

Testicular vacuolar change (suspect lipid)

Histopathology Comments:

The vacuoles within the seminiferous tubule are consistent with lipid, which is unusual. Note that the other mouse in this line has the same change in the testes. Histochemical staining is required to confirm the identity of the vacuoles as lipid.

stomach (MA:0000353)**Histopath Description:**

There are low numbers of neutrophils within the deep lamina propria.

Morphological Diagnosis:

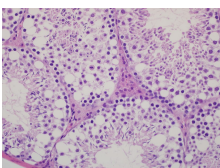
Duration: Sub-acute; **Distribution:** Multifocal; **Severity:** mild; **MPATH Diagnosis:** inflammation MPATH:212

Definitive Diagnosis:

Gastritis, suppurative

Histopathology Comments:

The lesion is likely caused by Helicobacter infection



Testis, lipidosis,
40x, HE.

Organ/Tissue Analyzed:

There were no significant findings in the following tissues: Brain, eyes, salivary glands, trachea, lungs, heart, thyroid gland, parathyroid gland, spleen, exocrine and endocrine pancreas, esophagus, intestines, urinary organs and tract, adrenal gland, lymph nodes, spinal cord, bones, bone marrow, skeletal muscles, brown fat, and skin.

AnimalID: M00244753 Abhd5 -/-**Tissue Preservation and Staining:**

Tissues not present in submission: Calvarium, ears, tongue, Harderian gland, zymbal gland, nasal sinuses, teeth, gall bladder. Thyroid not available in section.

Histopathology Findings:**liver (MA:0000358)****Histopath Description:**

The overall hepatic lobular architecture is normal. Diffusely, hepatocytes contain intracytoplasmic clear vacuoles (lipid). The lipid vacuoles within the midzonal and periportal regions are small (2-3 um in diameter) and surround a central nucleus (interpreted as microvesicular lipid). The lipid vacuoles within the portal areas are large (8-12 um in diameter) and displace the nucleus to the margin (macrovesicular lipid).

Morphological Diagnosis:

Distribution: Diffuse; **Severity:** moderate; **MPATH Diagnosis:** lipid deposition MPATH:42

Definitive Diagnosis:

Hepatic lipidosis

Histopathology Comments:

Hepatocellular vacuolar change of variable degree suggestive of lipidosis is present in all mice from WTSI, consistent with high lipid diet.

testis (MA:0000411)**Histopath Description:**

Diffusely, sertoli cells contain a single large, 20-25 um in diameter, intracytoplasmic clear vacuole that displaces the nucleus to the margin (macrovesicular lipid). Lipid vacuoles are also present within the epididymal lumen.

Morphological Diagnosis:

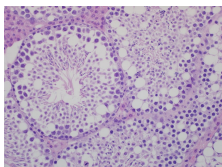
Distribution: Diffuse; **Severity:** moderate; **MPATH Diagnosis:** lipid deposition MPATH:42

Definitive Diagnosis:

Testicular vacuolar change (suspect lipid)

Histopathology Comments:

The vacuoles within the seminiferous tubules are most consistent with lipid. Testicular lipid accumulation is unusual. The change does not appear to compromise spermatogenesis. Note that the other mouse also have the same vacuolar change in the testes.



Testis, lipidosis,
40x, HE.

Organ/Tissue Analyzed:

There were no significant findings in the following tissues: Brain, eyes, salivary glands, trachea, lungs, heart, thymus, thyroid gland, parathyroid gland, spleen, exocrine and endocrine pancreas, esophagus, stomach, intestines, urinary organs and tract, adrenal gland, lymph nodes, spinal cord, bones, bone marrow, skeletal muscles, brown fat, and skin.

Summary:

Various incidental lesions were found. These lesions were also variably documented in the wild type control mice. A unique finding in this line is the presence of testicular lipidosis. This is an unusual finding, but its significance is not certain.

Report Summary and Recommendation:

A unique finding in this line is the presence of testicular vacuolation. This is an unusual finding. The lesion may be consistent with Chanarin-Dorfman syndrome (CDS) in humans, an autosomal recessive neutral lipid storage disease associated with mutation in Abhd gene (Aggarwal et al., 2012). It is very rare and characterized by ichthyosis, intracellular fat droplets in leucocytes (Jordan anomaly) and involvement of multiple tissues (skeletal muscle, central nervous system, bone marrow, eye and ear) mainly the liver

(Aggarwal et al., 2012).. Storage-like lesions are not observed in any other organ in this line. The diffuse helaptic lipidosis associated with high fat diet precludes/confounds such observation in this line. There are no skin lesions as described in humans.

Testis: Degenerative change : MPATH:14

References:

Aggarwal S, Maras JS, Alam S, Khanna R, Gupta SK, Ahuja A. Novel nonsense mutation of ABHD5 in Dorfman-Chanarin syndrome with unusual findings: A challenge for genotype-phenotype correlation. Eur J Med Genet. 2012 Feb 6. [Epub ahead of print]