



# CMHD Pathology Report

## CMHD Pathology Core

Toronto Centre for Phenogenomics  
25 Orde St. 3rd fl.  
Toronto, Ont. M5T 3H7  
Tel.(416) 586-8375  
Fax (416) 586-5993

contact: Dr. Susan Newbigging  
email: [newbigging@lunenfeld.ca](mailto:newbigging@lunenfeld.ca)

ReportID: MSH13005  
Pathologist: H. Adissu

Report Date: January 23, 2013

CMHD LabID: N12-1513

## History:

Phenotype: kyphosis, abnormal spine curvature, abnormal vertebral transverse process

AnimalID: M00318403

## Histopathology Findings:

### liver (MA:0000358)

#### Histopath Description:

Diffuse lipidosis

#### Morphological Diagnosis:

**Distribution:** diffuse; **MPATH Diagnosis:** steatosis MPATH:622

#### Definitive Diagnosis:

hepatic lipidosis

### bulbourethral gland (MA:0000401)

#### Histopath Description:

There is multifocal epithelial proteinosis

#### Morphological Diagnosis:

**Distribution:** multifocal;

#### Definitive Diagnosis:

Epithelial proteinosis

### pancreas (MA:0000120)

#### Histopath Description:

There is a small (50-100 um diameter) exocrine pancreatic necrosis with regenerative epithelial hyperplasia

#### Morphological Diagnosis:

**Distribution:** focal;

#### Definitive Diagnosis:

Pancreatic exocrine necrosis with regeneration

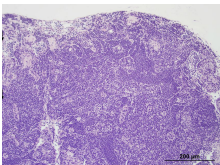
### mesenteric lymph node (MA:0002829)

#### Morphological Diagnosis:

**MPATH Diagnosis:** lymphoid neoplasms MPATH:513

#### Definitive Diagnosis:

Lymphoma, early



Lymph node,  
lymphoma, early,  
20x

Histopathology examination included the following organs and tissues: Calvarium, brain, eyes, ears, tongue, Harderian gland, zymbal gland, salivary glands, nasal sinuses, teeth, trachea, lungs, heart, thymus, thyroid gland, parathyroid gland, spleen, gall bladder, exocrine and endocrine pancreas, esophagus, stomach, intestines, urinary organs and tract, adrenal gland, lymph nodes, spinal cord, bone marrow, skeletal muscles, brown fat, and skin.

**AnimalID: M00318409****Histopathology Findings:****liver (MA:0000358)****Histopath Description:**

Minimal lipidosis

**Morphological Diagnosis:****Distribution:** multifocal; **MPATH Diagnosis:** steatosis MPATH:622**Definitive Diagnosis:**

Minimal or absent hepatic lipidosis

**testis (MA:0000411)****Histopath Description:**

Focally extensive atrophy and degeneration

**Morphological Diagnosis:****Distribution:** focally extensive;**Definitive Diagnosis:**

Testicular degeneration and atrophy

**salivary gland (MA:0000346)****Histopath Description:**

There are multifocal perivascular mononuclear inflammatory cell aggregates.

**Morphological Diagnosis:****Distribution:** multifocal;**Definitive Diagnosis:**

Interstitial inflammatory aggregates

**stomach (MA:0000353)****Morphological Diagnosis:****Distribution:** multifocal;**Definitive Diagnosis:**

neutrophilic gastritis

Histopathology examination included the following organs and tissues: Calvarium, brain, eyes, ears, tongue, Harderian gland, zymbal gland, salivary glands, nasal sinuses, teeth, trachea, lungs, heart, thymus, thyroid gland, parathyroid gland, spleen, gall bladder, exocrine and endocrine pancreas, esophagus, stomach, intestines, urinary organs and tract, adrenal gland, lymph nodes, spinal cord, bone marrow, skeletal muscles, brown fat, and skin.

**AnimalID: M00318428****Histopathology Findings:****liver (MA:0000358)****Histopath Description:**

moderate macrovesicularhepatic lipidosis

**Morphological Diagnosis:****Distribution:** multifocal; **MPATH Diagnosis:** steatosis MPATH:622**Definitive Diagnosis:**

Moderate hepatic lipidosis

**stomach (MA:0000353)****Histopath Description:**

lymphoplasmacytic and neutrophilic inflammation with mucus cell hyperplasia

**Morphological Diagnosis:****Distribution:** multifocal;**Definitive Diagnosis:**

Chronic active gastritis with mucus cell hyperplasia

**thymus (MA:0000142)****Histopath Description:**

There is a 100 um diameter epithelial cyst

**Morphological Diagnosis:****Distribution:** focal; **MPATH Diagnosis:** cyst MPATH:62**Definitive Diagnosis:**

Epithelial cyst

**brain (MA:0000168)****Histopath Description:**

mild hydrocephalus

**Morphological Diagnosis:**

**MPATH Diagnosis:** hydrocephalus MPATH:639

**Definitive Diagnosis:**

Mild hydrocephalus of the lateral ventricles

Histopathology examination included the following organs and tissues: Calvarium, brain, eyes, ears, tongue, Harderian gland, zymbal gland, salivary glands, nasal sinuses, teeth, trachea, lungs, heart, thymus, thyroid gland, parathyroid gland, spleen, gall bladder, exocrine and endocrine pancreas, esophagus, stomach, intestines, urinary organs and tract, adrenal gland, lymph nodes, spinal cord, bone marrow, skeletal muscles, brown fat, and skin.

---

**AnimalID: M00318430**

**Histopathology Findings:**

**liver (MA:0000358)**

**Histopath Description:**

moderate macrovesicularhepatic lipidosis

**Morphological Diagnosis:**

**Distribution:** multifocal; **MPATH Diagnosis:** steatosis MPATH:622

**Definitive Diagnosis:**

Moderate hepatic lipidosis

**mesenteric lymph node (MA:0002829)**

**Histopath Description:**

There are prominent lymphoid follicles with germinal centers. Medullary sinuses contain numerous mature lymphocytes

**Definitive Diagnosis:**

Lymphoid hyperplasia

**lung (MA:0000415)**

**Histopath Description:**

There is a focal peribronchitis with focally extensive squamous cell metaplasia

**Morphological Diagnosis:**

**Distribution:** focally extensive;

**Definitive Diagnosis:**

Bronchiolitis with squamous metaplasia

Histopathology examination included the following organs and tissues: Calvarium, brain, eyes, ears, tongue, Harderian gland, zymbal gland, salivary glands, nasal sinuses, teeth, trachea, lungs, heart, thymus, thyroid gland, parathyroid gland, spleen, gall bladder, exocrine and endocrine pancreas, esophagus, stomach, intestines, urinary organs and tract, adrenal gland, lymph nodes, spinal cord, bone marrow, skeletal muscles, brown fat, and skin.

**Summary and Recommendation:**

Lesions in this line are considered incidental. Two mice had mesenteric lymphoid hyperplasia/lymphoma. The skeletal phenotypes are difficult to ascertain on single skeletal sections.