



CMHD Pathology Report



CMHD Pathology Core

Toronto Centre for
Phenogenomics
25 Orde St. 3rd fl.
Toronto, Ont. M5T 3H7
Tel.(416) 586-8375
Fax (416) 586-5993

contact: Dr. Susan
Newbigging
email:
newbigging@lunenfeld.ca

ReportID: Report Date: November 23,
2011
Pathologist: H. Adissu

Mouse Genetics Project

Wellcome Trust Sanger
Institute
Wellcome Trust Genome
Campus
Hinxton, Cambridge
CB10 1SA
UK

CMHD LabID: N11-189

Relevant History:

(Modified SHIRPA; Dymorphology; Eye Morphology; Auditory Brainstem Response; Plasma Chemistry; Haematology (CBC); Peripheral Blood Lymphocytes; Eye Histopathology) Decreased peripheral lymphocytes, severe deafness, multiple eye abnormalities (closed at birth, corneal vascularization, abnormal eye pigmentation, histopathology), absent pinna reflex, decreased glucose, increased bilirubin, increased BMC and bone strength

AnimalID: M00180614 Spns2 hom

Tissue Preservation and Staining:

Tissues not present in submission: Calvarium, ears, tongue, Harderian gland, zymbal gland, nasal sinuses, teeth, gall bladder.

Histopathology Findings:

brown fat (MA:0000057)

Histopath Description:

Within the brown fat, there are multifocal aggregates of cells with a prominent open central nucleus and abundant microvesiculated cytoplasm (as described). Rare mitotic figures are present. Occasional multinucleated giant cells and rare lymphocytes are present.

Morphological Diagnosis:

Duration: Chronic; **Distribution:** Multifocal; **Severity:** mild; **MPATH Diagnosis:** inflammation MPATH:212

Definitive Diagnosis:

Lipogranuloma with brown fat hyperplasia

Histopathology Comments:

This lesion is likely a deep extension of dermatitis.

liver (MA:0000358)

Histopath Description:

The overall hepatic lobular architecture is normal. Nearly 50 of hepatocytes notably within the midzonal region contain large (8-12 um in diameter) intracytoplasmic clear vacuoles (macrovesicular lipid).

Morphological Diagnosis:

Distribution: Multifocal; **Severity:** mild; **MPATH Diagnosis:** lipid deposition MPATH:42

Definitive Diagnosis:

Hepatic lipidosis

Histopathology Comments:

Hepatocellular vacuolar change of variable degree suggestive of lipidosis is present in all mice from WTSI, consistent with high lipid diet.

salivary gland (MA:0000346)

Histopath Description:

There are rare perivascular mononuclear inflammatory cells.

Morphological Diagnosis:

AnimalID: M00373802 Spns2 hom**Tissue Preservation and Staining:**

Mesenteric lymph nodes and thyroid gland are not present in section. The thyroid gland is not present in section. Tissues not present in submission: Calvarium, ears, tongue, Harderian gland, zymbal gland, nasal sinuses, teeth, gall bladder.

Histopathology Findings:**lung (MA:0000415)****Histopath Description:**

There are multifocal perivascular mononuclear inflammatory cell aggeragtes within the lung

Morphological Diagnosis:

Duration: Chronic; **Distribution:** Multifocal; **Severity:** mild; **MPATH Diagnosis:** inflammation MPATH:212

Definitive Diagnosis:

Perivascular inflammatory aggregates

Histopathology Comments:

These lesions are suggestive of antigenic stimulation of hematogenous origin.

adrenal gland (MA:0000116)**Histopath Description:**

Adrenal cortical cells immediately surrounding the medulla are vacuolated and contain fine granular golden brown cytoplasmic pigment.

Morphological Diagnosis:

Distribution: Diffuse; **Severity:** no lesions; **MPATH Diagnosis:** degenerative change MPATH:14

Definitive Diagnosis:

Vacuolar degeneration of X-zone of the adenal gland with cytoplasmic ceroid accumulation (X-zone involution).

Histopathology Comments:

The X zone of the adrenal cortex disappears when males reach sexual maturity and females undergo their first pregnancy. The zone also disappears in virgin females, albeit graduall (Percy and Barthold, 2007).

kidney (MA:0000368)**Histopath Description:**

There are multifocal perivascular mononuclear inflammatory aggregate within the renal cortical interstitium.

Morphological Diagnosis:

Duration: Chronic; **Distribution:** Multifocal; **Severity:** mild; **MPATH Diagnosis:** inflammation MPATH:212

Definitive Diagnosis:

Perivascular inflammatory aggregates

Histopathology Comments:

The lesion signify non-specific antigenic stimulation.

liver (MA:0000358)**Histopath Description:**

The overall hepatic lobular architecture is normal. Approximately 50% of hepatocytes within the midzonal region contain large (8-12 um in diameter) intracytoplasmic clear vacuoles (macrovesicular lipid). Rare small clusters of lymphocytes and small numbers of neutrophils are present.

Morphological Diagnosis:

Distribution: Multifocal; **Severity:** mild; **MPATH Diagnosis:** lipid deposition MPATH:42

Definitive Diagnosis:

Hepatic lipidosis

Histopathology Comments:

Hepatocellular vacuolar change of variable degree suggestive of lipidosis is present in all mice from WTSI, consistent with high lipid diet. The changes in this mouse are less severe.

stomach (MA:0000353)**Histopath Description:**

There are moderate numbers of neutrophils within the deep lamina propria

Morphological Diagnosis:

Duration: Sub-acute; **Distribution:** Multifocal; **Severity:** mild; **MPATH Diagnosis:** inflammation MPATH:212

Definitive Diagnosis:

Gastritis, suppurative

Histopathology Comments:

This lesion is most commonly associated with Helicobacter infection. Further investigation is suggested using histochemistry (Silver stain) or colony fecal PCR.

eye: Eye 1 (MA:0000261)**Histopath Description:**

The plane of section is peripheral (Only the choroid and the retina are present). There is marked multifocal intercellular separation within the inner nuclear and vacuolation within the outer plexiform layer. The retina is detached and degenerate foamy cells are necrotic cells are present within the cavity. Multifocally, retinal epithelial cells are hypertrophic and foamy.

Morphological Diagnosis:

Severity: severe; **MPATH Diagnosis:** degenerative change MPATH:14

Definitive Diagnosis:

Vacuolation and intercellular separation of the inner nuclear and vacuolationj of outer plexiform layer, retinal detachment and retinal epithelium hypertrophy.

eye: Eye 2 (MA:0000261)**Histopath Description:**

The plane of section is oblique; both the peripheral part of the cornea and retina appear abnormally thickened. The ciliary body is in view and lines the peripheral aspect of the cornea (indicating the plane of section is peripheral). A scant amount of lens is present. The stroma of the within the peripheral cornea is thickened and contains some plump fibroblasts and occasional neutrophils.

Morphological Diagnosis:

Distribution: Multifocal; **Severity:** mild; **MPATH Diagnosis:** inflammation MPATH:212

Definitive Diagnosis:

Mild neutrophilic keratitis

Histopathology Comments:

The lesion is likely an extension from bulbar conjunctivitis.

brain (MA:0000168)**Histopath Description:**

There is a mild enlargement of the lateral ventricle.

Morphological Diagnosis:

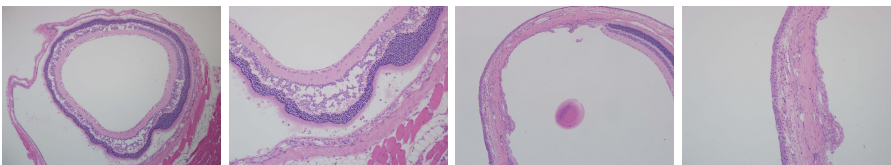
Distribution: Multifocal; **Severity:** mild; **MPATH Diagnosis:** hydrocephalus MPATH:639

Definitive Diagnosis:

hydrocephalus, lateral ventricle

Histopathology Comments:

Variable degree of hydrocephalus is observed in a proportion of wild type C57 Black 6 mice.



Eye, Intercellular separation of the inner nuclear and vacuolation of outer plexiform layer, retinal detachment and retinal epithelium hypertrophy. 10x

Eye, Intercellular separation of the inner nuclear and vacuolation of outer plexiform layer, retinal detachment and retinal epithelium hypertrophy. 20x

Eye, keratitis, 10x, HE

Eye, keratitis, 20x, HE

AnimalID: M00180561 Spns2 hom**Tissue Preservation and Staining:**

Thyroid gland not present in section. Tissues not present in submission: Calvarium, ears, tongue, Harderian gland, zymbal gland, nasal sinuses, teeth, gall bladder.

Histopathology Findings:

lung (MA:0000415)**Histopath Description:**

There are multifocal perivascular mononuclear inflammatory cell aggeragtes within the lung

Morphological Diagnosis:

Duration: Chronic; **Distribution:** Multifocal; **Severity:** mild; **MPATH Diagnosis:** inflammation MPATH:212

Definitive Diagnosis:

Perivascular inflammatory aggregates

Histopathology Comments:

These lesions are suggestive of antigenic stimulation of hematogenous origin.

adrenal gland (MA:0000116)**Histopath Description:**

Adrenal cortical cells immediately surrounding the medulla are vacuolated and contain fine granular golden brown cytoplasmic pigment.

Morphological Diagnosis:

Distribution: Diffuse; **Severity:** no lesions; **MPATH Diagnosis:** degenerative change MPATH:14

Definitive Diagnosis:

Vacuolar degeneration of X-zone of the adenal gland with cytoplasmic ceroid accumulation (X-zone involution).

Histopathology Comments:

The X zone of the adrenal cortex disappears when males reach sexual maturity and females undergo their first pregnancy. The zone also disappears in virgin females, albeit graduall (Percy and Barthold, 2007).

liver (MA:0000358)**Histopath Description:**

The overall hepatic lobular architecture is normal. Approximately 50% of hepatocytes within the midzonal region contain large (8-12 um in diameter) intracytoplasmic clear vacuoles (macrovesicular lipid). The cellularity of the liver is increased by numerous single to clusters of neutrophils and lymphocytes that are mainly found in portal areas. Mitotic figures are present. Some bizzare (tripolar) mitotic figures are also present.

Morphological Diagnosis:

Distribution: Multifocal; **Severity:** mild; **MPATH Diagnosis:** lipid deposition MPATH:42

Definitive Diagnosis:

Hepatic lipidosis; Chronic active hepatitis

Histopathology Comments:

Hepatocellular vacuolar change of variable degree suggestive of lipidosis is present in all mice from WTSI, consistent with high lipid diet. There is a notable chronic active neutrophilic hepatitis likely caused by bacteria.

lymph node (MA:0000139)**Morphological Diagnosis:**

Severity: moderate; **MPATH Diagnosis:** hyperplasia MPATH:134

Definitive Diagnosis:

Lymphoid hyperplasia.

brain (MA:0000168)**Histopath Description:**

There is a mild enlargement of the lateral ventricle.

Morphological Diagnosis:

Severity: mild; **MPATH Diagnosis:** hydrocephalus MPATH:639

Definitive Diagnosis:

hydrocephalus, lateral ventricle

Histopathology Comments:

Variable degree of hydrocephalus is observed in a proportion of wild type C57 Black 6 mice.

brain (MA:0000168)**Histopath Description:**

There is a 200 um diameter dermoid cyst within the corpus calosum. The cyst is keratin-filled and is lined by a well-differentiated simple squamous epithelium.

Morphological Diagnosis:**Distribution:** Focal; **Severity:** mild; **MPATH Diagnosis:** dermoid cyst MPATH:311**Definitive Diagnosis:**

Cerebral dermoid cyst (dermoid sinus)

Histopathology Comments:

Dermoid cyst is caused by defective epidermal closure along embryonic fissures isolating an island of ectoderm in the dermis or subcutis.

eye: Eye 2 (MA:0000261)**Histopath Description:**

The plane of section is peripheral (only the choroid and the retina are present). There is marked multifocal disorganization of the retinal outer and nuclear layers and occasional blending of the two layers with absence of the outer plexiform layer. Multifocally, the retinal appears to be folded and there are occasional ring like arrangement of nuclei of rods and cones surrounding a granular matrix (true rosette). The outer nuclear layer is segmentally absent or reduced to single to two cell thickness.

Morphological Diagnosis:**Distribution:** Multifocal; **Severity:** severe; **MPATH Diagnosis:** developmental and structural abnormality MPATH:55**Definitive Diagnosis:**

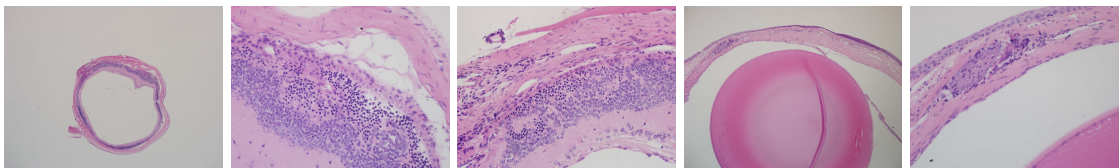
Retinal dysplasia

eye: Eye 1 (MA:0000261)**Histopath Description:**

: The plane of section is peripheral (The optic nerve is not in view). There is midstromal vascularisation extending from the limbus to the periphery of the cornea. There are scattered neutrophils and mononuclear inflammatory cells and a focal aggregate of multinucleated giant cells centered on a granular basophilic material (mineral).

Morphological Diagnosis:**Duration:** Chronic-active; **Distribution:** Multifocal; **Severity:** moderate; **MPATH Diagnosis:** inflammation MPATH:212**Definitive Diagnosis:**

Pyogranulomatous keratitis with mineralization



Eye, retinal dysplasia, 4x

Eye , retinal dysplasia, 40x

Eye , retinal dysplasia, 40x

Eye, keratitis, granuloma, 10x

Eye, keratitis, granuloma, 40x

Summary:

Ocular lesions were found in M00180561 and M00373802.

Report Summary and Recommendation:

Significant retinal dysplasia was observed in two mice (M00180561 and M00373802). These mice also had keratitis. The lesions may explain the ocular abnormality observed during in-life phenotype. There are no histopathology findings to explain other in-life phenotypes documented in this line. Other lesions are considered incidental and/or attributable to background strain. Auricular tissues are not present to assess the presence of any abnormality to explain abnormal auditory brainstem response noted during in-life phenotyping.

Eye: dysplasia MPATH:64