



CMHD Pathology Report



CMHD Pathology Core

Toronto Centre for
Phenogenomics
25 Orde St. 3rd fl.
Toronto, Ont. M5T 3H7
Tel.(416) 586-8375
Fax (416) 586-5993

contact: Dr. Susan
Newbigging
email:
newbigging@lunenfeld.ca

ReportID: Report Date: March 12, 2013
Pathologist: H. Adissu

Mouse Genetics Project

Wellcome Trust Sanger
Institute
Wellcome Trust Genome
Campus
Hinxton, Cambridge
CB10 1SA
UK

CMHD LabID: N12-1516

Relevant History:

Phenotype:

craniofacial abnormalities
oedema
polydactyly
preweaning lethality

AnimalID: M00247709 (Male)

Histopathology Findings:

mesenteric lymph node (MA:0002829)

Histopath Description:

lymphoma

Morphological Diagnosis:

MPATH Diagnosis: lymphoid neoplasms MPATH:513

Definitive Diagnosis:

Lymphoma

liver (MA:0000358)

Histopath Description:

Diffuse lipidosis

Morphological Diagnosis:

Distribution: diffuse; **Severity:** severe; **MPATH Diagnosis:** steatosis MPATH:622

Definitive Diagnosis:

Diffuse hepatic steatosis

testis (MA:0000411)

Histopath Description:

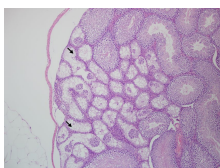
There is focally extensive testicular vacuolar degeneration and atrophy

Morphological Diagnosis:

Distribution: multifocal; **Severity:** mild;

Definitive Diagnosis:

Testicular degeneration and atrophy



Testis,
degeneration and
atrophy, 20x

sternal manubrium (MA:0001332)**Histopath Description:**

There is a partial sternal fracture. The chondroid tissue along the fracture is markedly degenerate. There is a nodular cartilagenous proliferation at the perichondrial margins (reactive reparative chondroid hyperplasia)

Morphological Diagnosis:

Duration: chronic; **Distribution:** focally extensive;

Definitive Diagnosis:

Sternal osteochondritis with fracture and reactive and reparative chondroid hyperplasia ('calus')

brain (MA:0000168)**Histopath Description:**

Mild hydrocephalus.

Morphological Diagnosis:

Severity: mild;

Definitive Diagnosis:

Mild hydrocephalus of the lateral ventricles

AnimalID: M00247708 (Male)**Histopathology Findings:****mesenteric lymph node (MA:0002829)****Histopath Description:**

lymphoma

Morphological Diagnosis:

MPATH Diagnosis: lymphoid neoplasms MPATH:513

Definitive Diagnosis:

Lymphoma

liver (MA:0000358)**Histopath Description:**

Diffuse lipidosis

Morphological Diagnosis:

Distribution: diffuse; **Severity:** severe; **MPATH Diagnosis:** steatosis MPATH:622

Definitive Diagnosis:

Diffuse hepatic steatosis

testis (MA:0000411)**Histopath Description:**

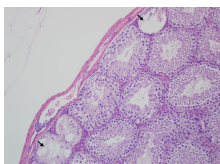
There is focally extensive testicular vacuolar degeneration and atrophy

Morphological Diagnosis:

Distribution: multifocal; **Severity:** mild;

Definitive Diagnosis:

Testicular degeneration and atrophy



Testis,
degeneration and
atrophy, 20x.

brain (MA:0000168)**Histopath Description:**

Mild hydrocephalus.

Morphological Diagnosis:

Severity: mild; **MPATH Diagnosis:** hydrocephalus MPATH:639

Definitive Diagnosis:

Mild hydrocephalus of the lateral ventricles

AnimalID: M00247712 (Female)

Histopathology Findings:

mesenteric lymph node (MA:0002829)

Histopath Description:

lymphoma

Morphological Diagnosis:

MPATH Diagnosis: lymphoid neoplasms MPATH:513

Definitive Diagnosis:

Lymphoma

spleen (MA:0000141)

Histopath Description:

moderate erythroid extramedullary hematopoiesis

Morphological Diagnosis:

Distribution: multifocal to coalescing; **Severity:** moderate; **MPATH Diagnosis:** extramedullary hemopoiesis MPATH:595

Definitive Diagnosis:

moderate erythroid extramedullary hematopoiesis

AnimalID: M00247713 (Female)

Histopathology Findings:

mesenteric lymph node (MA:0002829)

Histopath Description:

lymphoma

Morphological Diagnosis:

MPATH Diagnosis: lymphoid neoplasms MPATH:513

Definitive Diagnosis:

Lymphoma

spleen (MA:0000141)

Histopath Description:

moderate erythroid extramedullary hematopoiesis

Morphological Diagnosis:

Distribution: multifocal to coalescing; **Severity:** moderate; **MPATH Diagnosis:** extramedullary hemopoiesis MPATH:595

Definitive Diagnosis:

moderate erythroid extramedullary hematopoiesis

bone marrow (MA:0000134)

Histopath Description:

There is marked erythroid hyperplasia

Morphological Diagnosis:

Severity: moderate;

Definitive Diagnosis:

Erythroid hyperplasia

Report Summary and Recommendation:

No lesions were found to explain the clinical phenotypes. The morphological abnormalities in the cranium, incisors, snout, and vertebra that were observed during clinical phenotyping are difficult to ascertain by histopathology. Multifocal testicular degeneration and atrophy was observed in both males. Other lesions are considered incidental and attributable to diet or strain background.