



# CMHD Pathology Report

## CMHD Pathology Core

Toronto Centre for Phenogenomics  
25 Orde St. 3rd fl.  
Toronto, Ont. M5T 3H7  
Tel.(416) 586-8375  
Fax (416) 586-5993

contact: Dr. Susan Newbigging  
email: [newbigging@lunenfeld.ca](mailto:newbigging@lunenfeld.ca)

ReportID: MSH13004  
Pathologist: H. Adissu

Report Date: January 16, 2013

CMHD LabID: N12-1518

### History:

vertebral fusion  
decreased lumbar vertebrae number  
increased sacral vertebrae number  
increased thoracic vertebrae number  
vertebral transformation  
increased rib number  
partial lethality  
chromosomal instability

**AnimalID: M00412518 M00412518**

### Tissue Preservation and Staining:

thyroid not present in section

### Histopathology Findings:

#### testis (MA:0000411)

##### Histopath Description:

Seminiferous tubules are diffusely vacuolated and hypocellular. They are lined by spermatogonia and numerous sertoli cells with accentuated vacuolated cytoplasmic processes filling the lumina. Rare apoptotic bodies are present. Primary spermatocytes are very rare. Myoepithelial cells are unremarkable. Interstitial cells are accentuated.

##### Morphological Diagnosis:

**Distribution:** multifocal; **MPATH Diagnosis:** hypoplasia MPATH:133

##### Definitive Diagnosis:

Testicular atrophy and lack of spermatogenesis.

#### epididymal duct (MA:0001735)

##### Histopath Description:

Low numbers of sperm cells admixed with cell debris are present within the tail of epididymis.

##### Morphological Diagnosis:

**Distribution:** Diffuse; **MPATH Diagnosis:** hypoplasia MPATH:133

##### Definitive Diagnosis:

Epididymal aspermia

##### Histopathology Comments:

The absence of spermatocytes is consistent with the observed seminiferous atrophy.

#### knee joint (MA:0000471)

##### Histopath Description:

There is multifocal fibrillation of the articular cartilage. There are clusters of chondrocytes (chondrones) within the articular cartilage

##### Morphological Diagnosis:

**Distribution:** multifocal; **MPATH Diagnosis:** degenerative change MPATH:14

##### Definitive Diagnosis:

Osteoarthritis, mild

#### liver (MA:0000358)

##### Histopath Description:

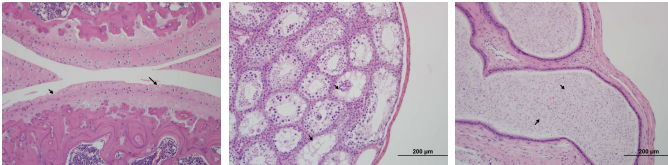
There is diffuse microvesicular lipidosis

##### Morphological Diagnosis:

**Distribution:** diffuse; **MPATH Diagnosis:** lipid deposition MPATH:42

##### Definitive Diagnosis:

Hepatic lipidosis



Knee joint, articular surface, fibrillation, 20x

Testis, degeneration and atrophy, 20x

Epididymal duct, hypospermia, 20x

There were no significant findings in the following tissues: Calvarium, brain, eyes, ears, tongue, Harderian gland, zymbal gland, salivary glands, nasal sinuses, teeth, trachea, lungs, heart, thymus, thyroid gland, parathyroid gland, spleen, gall bladder, exocrine and endocrine pancreas, esophagus, stomach, intestines, urinary organs and tract, adrenal gland, lymph nodes, spinal cord, bone marrow, skeletal muscles, brown fat, and skin.

## AnimalID: M00444368 M00412518

### Histopathology Findings:

#### testis (MA:0000411)

##### Histopath Description:

Similar but milder lesions as seen in M00412518 are present in the testis.

##### Morphological Diagnosis:

**Distribution:** diffuse; **Severity:** moderate; **MPATH Diagnosis:** hypoplasia MPATH:133

##### Definitive Diagnosis:

Testicular atrophy and lack of spermatogenesis.

#### liver (MA:0000358)

##### Histopath Description:

There is diffuse microvesicular lipidosis

##### Morphological Diagnosis:

**Distribution:** diffuse; **Severity:** moderate; **MPATH Diagnosis:** lipid deposition MPATH:42

##### Definitive Diagnosis:

Hepatic lipidosis

#### spinal cord (MA:0000216)

##### Histopath Description:

A single swollen axon is present (spheroid)

##### Morphological Diagnosis:

**Distribution:** focal; **Severity:** mild; **MPATH Diagnosis:** degenerative change MPATH:14

##### Definitive Diagnosis:

Axonal degeneration

#### brain (MA:0000168)

##### Histopath Description:

hydrocephalus

##### Morphological Diagnosis:

**Distribution:** bilateral; **Severity:** mild; **MPATH Diagnosis:** hydrocephalus MPATH:639

#### heart (MA:0000072)

##### Histopath Description:

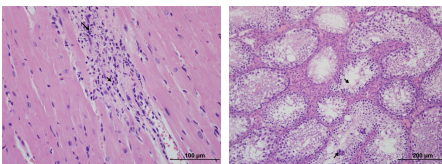
There is focal necrosis within the left myocardium

##### Morphological Diagnosis:

**Distribution:** focal; **MPATH Diagnosis:** necrosis MPATH:4

##### Definitive Diagnosis:

Focal myocardial necrosis



Heart, focal necrosis, 40x

Testis, degeneration and atrophy, 20x

There were no significant findings in the following tissues: calvarium, eyes, ears, tongue, Harderian gland, zymbal gland, salivary glands, nasal sinuses, teeth, trachea, lungs, thymus, thyroid gland, parathyroid gland, spleen, gall bladder, exocrine and endocrine pancreas, esophagus, stomach, intestines, urinary organs and tract, adrenal gland, reproductive organs, lymph nodes, bones, bone marrow, skeletal muscles, brown fat, and skin.

**AnimalID: M00444372 M00412518****Histopathology Findings:****liver (MA:0000358)****Histopath Description:**

diffuse lipidosis

**Morphological Diagnosis:****Distribution:** diffuse; **Severity:** moderate; **MPATH Diagnosis:** lipid deposition MPATH:42**Definitive Diagnosis:**

Hepatic lipidosis

**stomach (MA:0000353)****Histopath Description:**

moderate neutrophilic gastritis

**Morphological Diagnosis:****Distribution:** multifocal to coalescing; **Severity:** moderate; **MPATH Diagnosis:** inflammation MPATH:212**Definitive Diagnosis:**

Neutrophilic gastritis

**brain (MA:0000168)****Morphological Diagnosis:****MPATH Diagnosis:** hydrocephalus MPATH:639**Definitive Diagnosis:**

Mild hydrocephalus

There were no significant findings in the following tissues: eyes, ears, tongue, Harderian gland, zymbal gland, salivary glands, nasal sinuses, teeth, trachea, lungs, heart, thymus, thyroid gland, parathyroid gland, spleen, gall bladder, exocrine and endocrine pancreas, esophagus, intestines, urinary organs and tract, adrenal gland, reproductive organs, lymph nodes, spinal cord, bones, bone marrow, skeletal muscles, brown fat, and skin.

**AnimalID: M00383115 M00412518****Histopathology Findings:****liver (MA:0000358)****Morphological Diagnosis:****Distribution:** diffuse; **Severity:** moderate; **MPATH Diagnosis:** lipid deposition MPATH:42**Definitive Diagnosis:**

Hepatic lipidosis

**kidney (MA:0000368)****Histopath Description:**

There is 1x0.5 mm focal subcapsular aggregates of glomeruli

**Morphological Diagnosis:****Severity:** mild; **MPATH Diagnosis:** developmental and structural abnormality MPATH:55**Definitive Diagnosis:**

Subcapsular glomerular aggregates

**Histopathology Comments:**

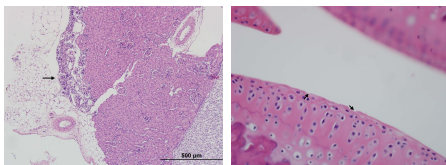
This is likely a developmental defect

**knee joint (MA:0000471)****Histopath Description:**

Mild fibrillation of the articular cartilage

**Morphological Diagnosis:****Distribution:** focally extensive; **Severity:** mild; **MPATH Diagnosis:** degenerative change MPATH:14**Definitive Diagnosis:**

Mild degenerative joint disease (osteoarthritis)



Kidney, subcapsular  
glomerular  
aggregates, 10x

Knee joint, articular  
surface, fibrillation,  
20x

There were no significant findings in the following tissues: brain, eyes, ears, tongue, Harderian gland, zymbal gland, salivary glands, nasal sinuses, teeth, trachea, lungs, heart, thymus, thyroid gland, parathyroid gland, spleen, gall bladder, exocrine and endocrine pancreas, esophagus, stomach, intestines, adrenal gland, reproductive organs, lymph nodes, spinal cord, bones, marrow, skeletal muscles, brown fat, and skin.

**Summary and Recommendation:**

Main findings in this line are mild joint degenerative lesions (2/4), testicular degeneration and atrophy (2/2 males). We did not find histologic correlate to the chromosomal instability observed by the phenotyping pipeline. Microscopic examination of single sections is not appropriate to confirm the vertebral and rib phenodeviants.