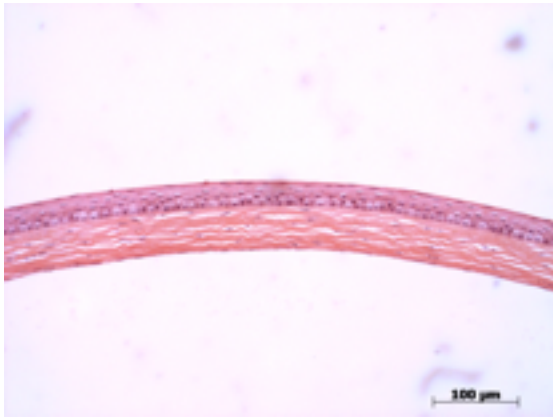

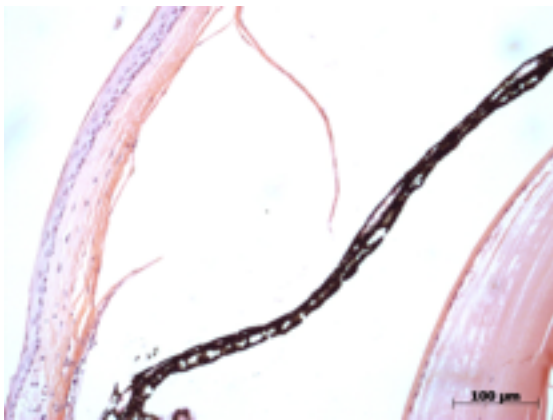
**Abnormal Findings:** None.

## EYE Phenotype




### Cornea:

**6/6.** Normal corneal epithelium, stroma, and endothelium.



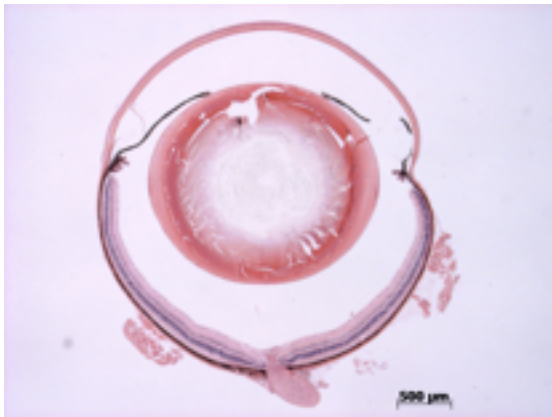
### Anterior chamber:

**6/6.** The anterior chamber was of normal depth without cells, and the angle appeared open.



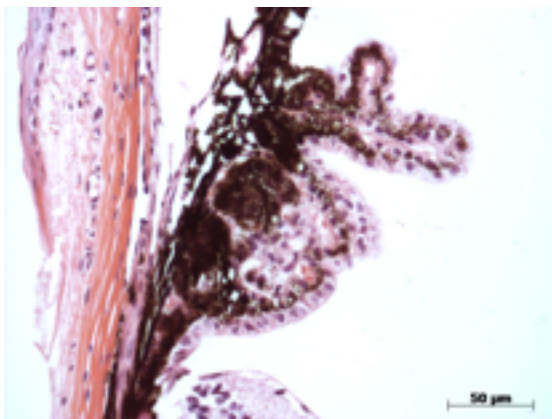
### Iris:

**6/6.** The iris showed normal pigmentation without rubeosis or pupillary membranes.



**Lens:**

**6/6.** No cataract was observed.



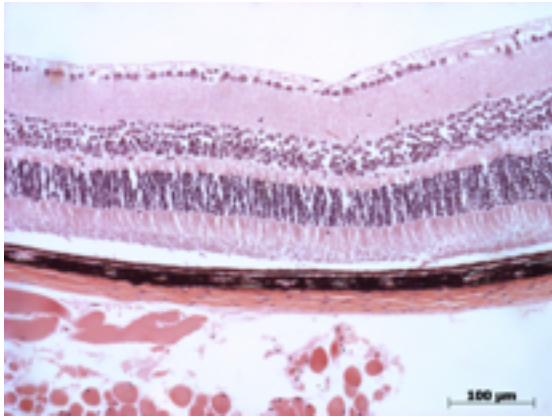
**Ciliary body:**

**6/6.** Normal stroma, pigmented and nonpigmented layers were present along with cilia.



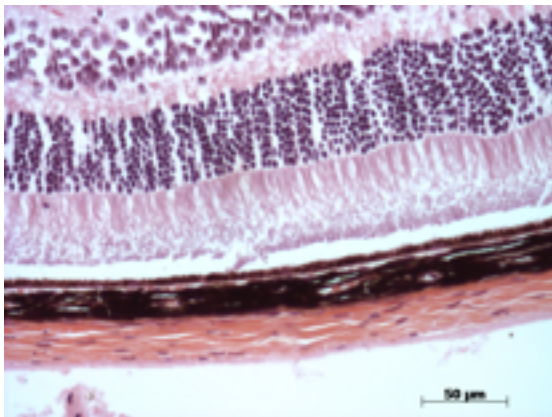
**Vitreous:**

**6/6.** No abnormal opacities or cells.



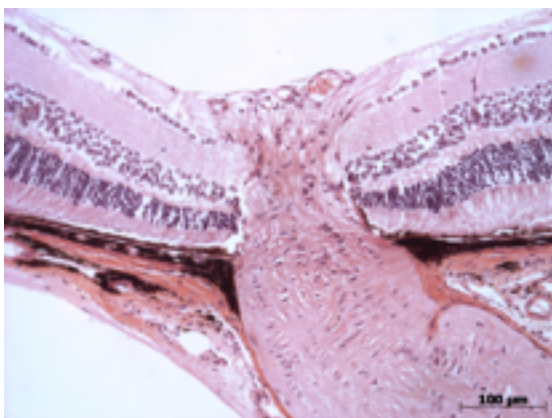
**Retina:**

**6/6.** The retinal ganglion, inner nuclear and photoreceptor layers are normal.



**Retinal pigment epithelium and Choroid:**

**6/6.** Normal pigmentation. Bruch's membrane is intact. No neovascular membranes were noted.



**Optic Nerve:**

**6/6.** The nerve is normal.

**Methods.** 6 eyes from 3 male mice were enucleated by blunt dissection and fixed. Pupil-optic nerve sections were processed with hematoxylin and eosin, and standard images were captured under light microscopy for review.