



# CMHD Pathology Report



## CMHD Pathology Core

Toronto Centre for  
Phenogenomics  
25 Orde St. 3rd fl.  
Toronto, Ont. M5T 3H7  
Tel.(416) 586-8375  
Fax (416) 586-5993

contact: Dr. Susan  
Newbigging  
email:  
[newbigging@lunenfeld.ca](mailto:newbigging@lunenfeld.ca)

ReportID: Report Date: July 12, 2013  
Pathologist: Dr. H. Adissu

## Mouse Genetics Project

Wellcome Trust Sanger  
Institute  
Wellcome Trust Genome  
Campus  
Hinxton, Cambridge  
CB10 1SA  
UK

CMHD LabID: N13-475

## Relevant History:

Phenotype:

partial lethality

---

## AnimalID: M00562180 (Male)

### Histopathology Findings:

#### testis (MA:0000411)

##### Histopath Description:

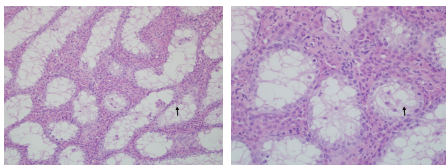
There is extensive atrophy and vacuolation of the seminiferous tubule affecting the entire testicular parenchyma. There is no evidence of spermatids and sperm cells. The interstitial tissue is prominent with marked hyperplasia of the leydig cells.

##### Morphological Diagnosis:

**Distribution:** diffuse; **Severity:** extreme;

##### Definitive Diagnosis:

Testicular vacuolation and hypoplasia; Leydig cell hyperplasia



Testis, vacuolation and atrophy, Leydig cell hyperplasia, 20x, HE

Testis, vacuolation and atrophy, Leydig cell hyperplasia, 40x, HE

#### epididymal duct (MA:0001735)

##### Histopath Description:

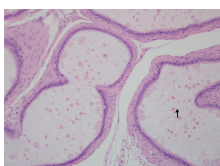
The epididymis is devoid of spermatocytes and contains cellular debris and proteinaceous fluid.

##### Morphological Diagnosis:

**Severity:** extreme;

##### Definitive Diagnosis:

Epididymal aspermia



Epididymis, aspermia, 40x, HE

#### thymus (MA:0000142)

**Histopath Description:**

There is a 50 um diameter epithelial cyst.

**Morphological Diagnosis:**

**Distribution:** focal; **MPATH Diagnosis:** cyst MPATH:62

**Definitive Diagnosis:**

Epithelial cyst

**Histopathology Comments:**

This is a developmental abnormality commonly seen in mice.

**liver (MA:0000358)****Histopath Description:**

diffuse lipidosis

**Morphological Diagnosis:**

**Distribution:** diffuse; **Severity:** severe; **MPATH Diagnosis:** steatosis MPATH:622

**Definitive Diagnosis:**

Hepatic lipidosis

**lymph node (MA:0000139)****Histopath Description:**

The mesenteric lymph node is markedly enlarged (greater than five-fold). The medulla is expanded by chords and sheets of plasmacytoid cells.

**Morphological Diagnosis:**

**Distribution:** Diffuse; **Severity:** moderate; **MPATH Diagnosis:** hyperplasia MPATH:134

**Definitive Diagnosis:**

Lymphoid hyperplasia with medullary plasmacytosis.

**Histopathology Comments:**

The changes in the mesenteric lymph node are suggestive of draining of a regional inflammatory process. However, such a process was not observed in the tissues examined.

**Organ/Tissue Analyzed:**

Histopathology examination included the following organs and tissues: brain, trigeminal ganglion, eyes, salivary glands, trachea, lungs, heart, thymus, thyroid gland, parathyroid gland, exocrine and endocrine pancreas, oesophagus, stomach, small intestine, large intestine, liver, gall bladder, spleen, kidneys, adrenal gland, lymph nodes, spinal cord, bone marrow, sternum, femur and tibia with associated skeletal muscles, brown fat, pinna, skin, testis, epididymis, seminal vesicle, and prostate.

**AnimalID: M00562178 (Male)****Histopathology Findings:****testis (MA:0000411)****Histopath Description:**

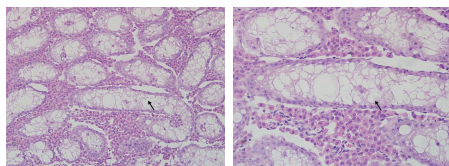
There is extensive atrophy and vacuolation of the seminiferous tubule affecting the entire testicular parenchyma. There is no evidence of spermatids and sperm cells. The interstitial tissue is prominent with marked hyperplasia of the Leydig cells.

**Morphological Diagnosis:**

**Distribution:** diffuse; **Severity:** extreme;

**Definitive Diagnosis:**

Testicular vacuolation and hypoplasia; Leydig cell hyperplasia



Testis, vacuolation and atrophy, Leydig cell hyperplasia, 20x, HE

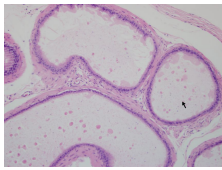
Testis, vacuolation and atrophy, Leydig cell hyperplasia, 40x, HE

**epididymal duct (MA:0001735)****Histopath Description:**

The epididymis is devoid of spermatocytes and contains cellular debris and proteinaceous fluid.

**Morphological Diagnosis:****Severity:** extreme;**Definitive Diagnosis:**

Epididymal aspermia

Epididymis,  
aspermia, 40x, HE**thymus (MA:0000142)****Histopath Description:**

There is a 50 um diameter epithelial cyst.

**Morphological Diagnosis:****Distribution:** focal; **MPATH Diagnosis:** cyst MPATH:62**Definitive Diagnosis:**

Epithelial cyst

**Histopathology Comments:**

This is a developmental abnormality commonly seen in mice.

**liver (MA:0000358)****Histopath Description:**

diffuse lipidosis

**Morphological Diagnosis:****Distribution:** diffuse; **Severity:** severe; **MPATH Diagnosis:** steatosis MPATH:622**Definitive Diagnosis:**

Hepatic lipidosis

**lymph node (MA:0000139)****Histopath Description:**

The mesenteric lymph node is markedly enlarged (greater than five-fold). The medulla is expanded by chords and sheets of plasmotoid cells.

**Morphological Diagnosis:****Distribution:** Diffuse; **Severity:** moderate; **MPATH Diagnosis:** hyperplasia MPATH:134**Definitive Diagnosis:**

Lymphoid hyperplasia with medullary plasmacytosis.

**Histopathology Comments:**

The changes in the mesenteric lymph node are suggestive of draining of a regional inflammatory process. However, such a process was not observed in the tissues examined.

**brain (MA:0000168)****Histopath Description:**

There is mild dilation of the lateral ventricles

**Morphological Diagnosis:****Distribution:** bilateral; **Severity:** mild;**Definitive Diagnosis:**

Dilation of the brain ventricles

**Histopathology Comments:**

Mild dilation of the lateral ventricles is a background condition in mice of C57BL/6N background (Brayton et al., 2004).

**retina (MA:0000276)****Histopath Description:**

Involving one eye, there are clusters of external nuclear structures within the internal plexiform layer.

**Morphological Diagnosis:****Distribution:** Focal; **Severity:** mild;**Definitive Diagnosis:**

## Retinal dysplasia

**Organ/Tissue Analyzed:**

Histopathology examination included the following organs and tissues: brain, trigeminal ganglion, eyes, salivary glands, trachea, lungs, heart, thymus, thyroid gland, parathyroid gland, exocrine and endocrine pancreas, oesophagus, stomach, small intestine, large intestine, liver, gall bladder, spleen, kidneys, adrenal gland, lymph nodes, spinal cord, bone marrow, sternum, femur and tibia with associated skeletal muscles, brown fat, pinna, skin, testis, epididymis, seminal vesicle, and prostate.

---

**AnimalID: M00584636 (Male)****Histopathology Findings:****thymus (MA:0000142)****Histopath Description:**

There is a 50 um diameter epithelial cyst.

**Morphological Diagnosis:**

**Distribution:** focal; **MPATH Diagnosis:** cyst MPATH:62

**Definitive Diagnosis:**

Epithelial cyst

**Histopathology Comments:**

This is a developmental abnormality commonly seen in mice.

**liver (MA:0000358)****Histopath Description:**

diffuse lipidosis

**Morphological Diagnosis:**

**Distribution:** diffuse; **Severity:** severe; **MPATH Diagnosis:** steatosis MPATH:622

**Definitive Diagnosis:**

Hepatic lipidosis

**eye (MA:0000261)****Histopath Description:**

A 100-um long stretch of fibrous connective tissue extends from the area of the optic disc towards the posterior capsule of the lens.

**Morphological Diagnosis:**

**MPATH Diagnosis:** developmental and structural abnormality MPATH:55

**Definitive Diagnosis:**

Persistent hyaloid artery

**Histopathology Comments:**

hyaloid artery remnant is a rare condition in which there remain some parts of the hyaloid artery. The posterior hyaloid vascular system of mice usually undergoes involution in the first month of life (Richard et al., 2000).

**Organ/Tissue Analyzed:**

Histopathology examination included the following organs and tissues: brain, trigeminal ganglion, eyes, salivary glands, trachea, lungs, heart, thymus, thyroid gland, parathyroid gland, exocrine and endocrine pancreas, oesophagus, stomach, small intestine, large intestine, liver, gall bladder, spleen, kidneys, adrenal gland, lymph nodes, spinal cord, bone marrow, sternum, femur and tibia with associated skeletal muscles, brown fat, pinna, skin, testis, epididymis, seminal vesicle, and prostate.

---

**AnimalID: M00572305 (Female)****Histopathology Findings:****liver (MA:0000358)****Histopath Description:**

diffuse lipidosis

**Morphological Diagnosis:**

**Distribution:** diffuse; **Severity:** severe; **MPATH Diagnosis:** steatosis MPATH:622

**Definitive Diagnosis:**

Hepatic lipidosis

**Organ/Tissue Analyzed:**

Histopathology examination included the following organs and tissues: brain, trigeminal ganglion, eyes, salivary glands, trachea, lungs, heart, thymus, thyroid gland, parathyroid gland, exocrine and endocrine pancreas, oesophagus, stomach, small intestine, large intestine, liver, gall bladder, spleen, kidneys, adrenal gland, lymph nodes, spinal cord, bone marrow, sternum, femur and tibia with associated skeletal muscles, brown fat, pinna, skin, uterus, oviduct, and ovary, and mammary gland.

**Report Summary and Recommendation:**

Main finding in this line is diffuse testicular atrophy/degeneration with marked expansion of the interstitial tissues (Leydig cells) and absence of spermatocytes in the epididymis. This lesion is suggestive of testicular hypoplasia and should cause infertility (which is not reported in this line). There are no findings predictive of lethality in this line; histopathology analysis of earlier age or embryos is recommended.

Line summary: Testicular atrophy/degeneration; interstitial cell (leydig cell) hyperplasia; Epididymal aspermia (2/2)