



CMHD Pathology Report



CMHD Pathology Core

Toronto Centre for
Phenogenomics
25 Orde St. 3rd fl.
Toronto, Ont. M5T 3H7
Tel.(416) 586-8375
Fax (416) 586-5993

contact: Dr. Susan
Newbigging
email:
newbigging@lunenfeld.ca

ReportID: Report Date: September 17,
2013
Pathologist: Dr. H. Adissu

Mouse Genetics Project

Wellcome Trust Sanger
Institute
Wellcome Trust Genome
Campus
Hinxton, Cambridge
CB10 1SA
UK

CMHD LabID: N13-571

Relevant History:

Phenotype:

abnormal foot pad morphology
dark foot pads
greasy coat
increased red blood cell distribution width
increased platelet cell number
increased mean platelet volume
decreased mean corpuscular volume
decreased mean corpuscular hemoglobin
decreased hemoglobin content
partial lethality
fetal edema

AnimalID: M00724579 (Male)

Histopathology Findings:

lung (MA:0000415)

Histopath Description:

The alveolar spaces in one of the lung lobes are completely filled by abundant large histiocytes that contain abundant cytoplasmic eosinophilic crystalline material that are on average 1x2 um. Occasionally there are large free 30x3 um eosinophilic crystals freely within alveoli. They are multifocal small lymphoplasmacytic aggregates admixed with rare multinucleated giant cells.

Morphological Diagnosis:

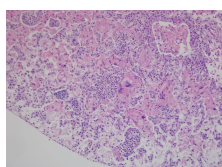
Duration: Chronic-active; **Distribution:** Multifocal to coalescing; **Severity:** severe; **MPATH Diagnosis:** acidophilic macrophage pneumonia MPATH:585

Definitive Diagnosis:

Eosinophilic crystalline pneumonia

Histopathology Comments:

The lesion explains the gross pathology observation in this mouse. Acidophilic macrophage pneumonia is a sporadic, idiopathic, age-related pulmonary disease of laboratory mice, more commonly affecting certain strains (C57BL/6, 129Sv), found naturally occurring in recessive mutations such as Ptpn6^{me} (motheaten) mice, SCID mice, as well as some knockout mice (such as CYP1A2 null) on a C57BL/6 or 129 background (Hoenerhoff et al., 2006 and references there in). The characteristic crystals morphologically resemble Charcot-Leyden crystals, which represent eosinophil breakdown products in humans with eosinophil-related disease (Hoenerhoff et al., 2006).



Lung, eosinophilic
crystalline
pneumonia, 20x, HE

testis (MA:0000411)**Histopath Description:**

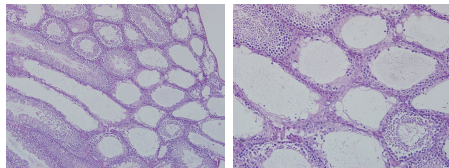
The seminiferous tubule is multifocally vacuolated and atrophic affecting 40-50% of the testicular parenchyma. Spermatogenesis is minimal to absent in the affected areas and there is minimal differentiation of spermatids to spermatozoa (spermiogenesis). There are numerous apoptotic spermatids and occasional multinucleated spermatids. The epididymis contains reduced amount of spermatozoa stores.

Morphological Diagnosis:

Distribution: multifocal to coalescing; **Severity:** severe;

Definitive Diagnosis:

Testicular degeneration and atrophy with absence of spermiogenesis; epididymal hypospermia



Testis,
degeneration and
atrophy, 10x, HE

Testis,
degeneration and
atrophy, 20x, HE

adrenal gland (MA:0000116)**Histopath Description:**

There is a small, well-circumscribed mass in the cortex. It is encapsulated by a thin layer of pale eosinophilic material and fusiform cells (connective tissue with fibroblasts) and is made of nests of polygonal cells interspersed by a very thin fibrovascular membrane. The architecture is reminiscent of the zona glomerulosa and zona fasciculate of the mature adrenal gland.

Morphological Diagnosis:

Distribution: focal;

Definitive Diagnosis:

accessory adrenal cortical tissue

liver (MA:0000358)**Histopath Description:**

diffuse lipidosis

Morphological Diagnosis:

Distribution: diffuse; **Severity:** extreme; **MPATH Diagnosis:** steatosis MPATH:622

Definitive Diagnosis:

hepatic steatosis

adrenal gland (MA:0000116)**Histopath Description:**

There is a small, well-circumscribed mass in the cortex. It is encapsulated by a thin layer of pale eosinophilic material and fusiform cells (connective tissue with fibroblasts) and is made of nests of polygonal cells interspersed by a very thin fibrovascular membrane. The architecture is reminiscent of the zona glomerulosa and zona fasciculate of the mature adrenal gland.

Morphological Diagnosis:

Distribution: focal;

Definitive Diagnosis:

accessory adrenal cortical tissue

lymph node (MA:0000139)**Histopath Description:**

The mesenteric lymph node is markedly enlarged (greater than four fold). The medulla is particularly expanded by chords and sheets of plasmotoid cells. There are prominent germinal centers within the medulla

Morphological Diagnosis:

Distribution: Diffuse; **Severity:** moderate; **MPATH Diagnosis:** hyperplasia MPATH:134

Definitive Diagnosis:

Lymphoid hyperplasia

Histopathology Comments:

The changes in the mesenteric lymph node are suggestive of draining of a regional inflammatory process. However, such a process was not observed in the tissues examined. Early maginal center lymphoma is suspected.

brain (MA:0000168)**Histopath Description:**

There is mild dilation of the lateral ventricles

Morphological Diagnosis:

Distribution: bilateral; **Severity:** mild;

Definitive Diagnosis:

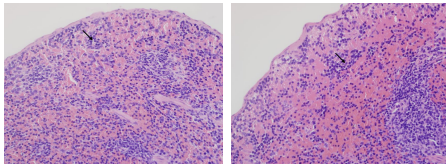
Dilation of the brain ventricles

Histopathology Comments:

Mild dilation of the lateral ventricles is a background condition in mice of C57BL/6N background (Brayton et al., 2004).

spleen (MA:0000141)**Histopath Description:**

Normal



Spleen, normal,
40x, HE

Spleen, Wt, normal,
40x, HE

Organ/Tissue Analyzed:

Histopathology examination included the following organs and tissues: brain, trigeminal ganglion, eyes, salivary glands, trachea, lungs, heart, thymus, thyroid gland, parathyroid gland, exocrine and endocrine pancreas, oesophagus, stomach, small intestine, large intestine, liver, gall bladder, spleen, kidneys, adrenal gland, lymph nodes, spinal cord, bone marrow, sternum, femur and tibia with associated skeletal muscles, brown fat, pinna, skin, testis, epididymis, seminal vesicle, and prostate.

AnimalID: M00706132 (Male)**Histopathology Findings:****testis (MA:0000411)****Histopath Description:**

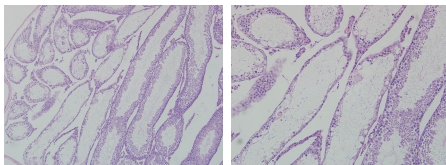
The seminiferous tubule is multifocally vacuolated and atrophic affecting 40-50% of the testicular parenchyma. Spermatozoa are minimal to absent in the affected areas and there is minimal differentiation of spermatids to spermatozoa. There are numerous apoptotic spermatids and occasional multinucleated spermatids. The epididymis contains reduced amount of spermatozoa stores.

Morphological Diagnosis:

Distribution: multifocal to coalescing; **Severity:** severe;

Definitive Diagnosis:

Testicular degeneration and atrophy with absence of spermiogenesis; epididymal hypospermia



Testis,
degeneration and
atrophy, 10x, HE

Testis,
degeneration and
atrophy, 20x, HE

spleen (MA:0000141)**Histopath Description:**

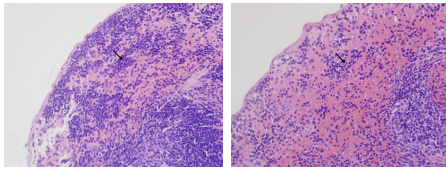
Mild erythropoiesis

Morphological Diagnosis:

Distribution: multifocal to coalescing; **Severity:** mild; **MPATH Diagnosis:** extramedullary hemopoiesis MPATH:595

Definitive Diagnosis:

Mild erythropoiesis



Spleen, mild erythroid hyperplasia, 40x, HE

Spleen, Wt, normal, 40x, HE

liver (MA:0000358)

Histopath Description:

diffuse lipidosis

Morphological Diagnosis:

Distribution: diffuse; **Severity:** extreme; **MPATH Diagnosis:** steatosis MPATH:622

Definitive Diagnosis:

hepatic steatosis

brain (MA:0000168)

Histopath Description:

There is mild dilation of the lateral ventricles

Morphological Diagnosis:

Distribution: bilateral; **Severity:** mild;

Definitive Diagnosis:

Dilation of the brain ventricles

Histopathology Comments:

Mild dilation of the lateral ventricles is a background condition in mice of C57BL/6N background (Brayton et al., 2004).

Organ/Tissue Analyzed:

Histopathology examination included the following organs and tissues: brain, trigeminal ganglion, eyes, salivary glands, trachea, lungs, heart, thymus, thyroid gland, parathyroid gland, exocrine and endocrine pancreas, oesophagus, stomach, small intestine, large intestine, liver, gall bladder, spleen, kidneys, adrenal gland, lymph nodes, spinal cord, bone marrow, sternum, femur and tibia with associated skeletal muscles, brown fat, pinna, skin, testis, epididymis, seminal vesicle, and prostate.

AnimalID: M00740520 (Female)

Histopathology Findings:

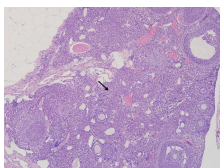
ovary (MA:0000384)

Histopath Description:

There ovarian stroma is markedly expanded. Numerous atrophic follicles are embeded within the stroma.

Definitive Diagnosis:

Ovarian stromal hyperplasia



Ovary, stromal hyperplasia, 10x, HE

spleen (MA:0000141)

Histopath Description:

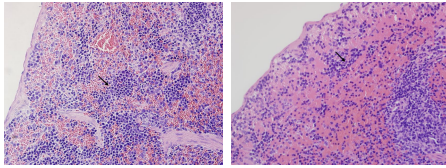
Moderate erythropoiesis; mild megakaryopoiesis

Morphological Diagnosis:

Distribution: multifocal to coalescing; **Severity:** moderate; **MPATH Diagnosis:** extramedullary hemopoiesis MPATH:595

Definitive Diagnosis:

Moderate erythropoiesis; mild megakaryopoiesis



Spleen, moderate erythroid hyperplasia, 40x, HE

Spleen, Wt, normal, 40x, HE

adrenal gland (MA:0000116)

Histopath Description:

There is a small, well-circumscribed mass in the cortex. It is encapsulated by a thin layer of pale eosinophilic material and fusiform cells (connective tissue with fibroblasts) and is made of nests of polygonal cells interspersed by a very thin fibrovascular membrane. The architecture is reminiscent of the zona glomerulosa and zona fasciculata of the mature adrenal gland.

Morphological Diagnosis:

Distribution: focal;

Definitive Diagnosis:

accessory adrenal cortical tissue

adrenal gland (MA:0000116)

Histopath Description:

There is a small, well-circumscribed mass in the cortex. It is encapsulated by a thin layer of pale eosinophilic material and fusiform cells (connective tissue with fibroblasts) and is made of nests of polygonal cells interspersed by a very thin fibrovascular membrane. The architecture is reminiscent of the zona glomerulosa and zona fasciculata of the mature adrenal gland.

Morphological Diagnosis:

Distribution: focal;

Definitive Diagnosis:

accessory adrenal cortical tissue

thyroid gland (MA:0000129)

Histopath Description:

The thyroid gland is partially replaced by a lymphoid tissue reminiscent of thymic tissue.

Morphological Diagnosis:

Distribution: multifocal;

Definitive Diagnosis:

Ectopic thymic tissue

Histopathology Comments:

This is developmental anomaly incidentally seen in mice

lymph node (MA:0000139)

Histopath Description:

The mesenteric lymph node is markedly enlarged (greater than four fold). The medulla is particularly expanded by chords and sheets of plasmotoid cells. There are prominent germinal centers within the medulla

Morphological Diagnosis:

Distribution: Diffuse; **Severity:** moderate; **MPATH Diagnosis:** hyperplasia MPATH:134

Definitive Diagnosis:

Lymphoid hyperplasia

Histopathology Comments:

The changes in the mesenteric lymph node are suggestive of draining of a regional inflammatory process. However, such a process was not observed in the tissues examined. Early marginal center lymphoma is suspected.

brain (MA:0000168)

Histopath Description:

There is mild dilation of the lateral ventricles

Morphological Diagnosis:

Distribution: bilateral; **Severity:** mild;

Definitive Diagnosis:

Dilation of the brain ventricles

Histopathology Comments:

Mild dilation of the lateral ventricles is a background condition in mice of C57BL/6N background (Brayton et al., 2004).

lung (MA:0000415)**Histopath Description:**

There is a focal perivascular aggregates of mononuclear inflammatory cells in the lung.

Morphological Diagnosis:**Duration:** Chronic; **Distribution:** focal; **Severity:** mild; **MPATH Diagnosis:** inflammation
MPATH:212**Definitive Diagnosis:**

Perivascular inflammatory aggregates

Histopathology Comments:

This lesion is suggestive of antigenic stimulation of hematogenous origin. It is a common and insignificant incidental finding.

liver (MA:0000358)**Histopath Description:**

moderate lipidosis

Morphological Diagnosis:**Distribution:** multifocal to coalescing; **Severity:** moderate; **MPATH Diagnosis:** steatosis
MPATH:622**Definitive Diagnosis:**

hepatic steatosis

Organ/Tissue Analyzed:

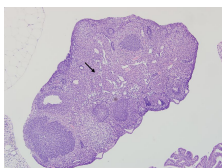
Histopathology examination included the following organs and tissues: brain, trigeminal ganglion, eyes, salivary glands, trachea, lungs, heart, thymus, thyroid gland, parathyroid gland, exocrine and endocrine pancreas, oesophagus, stomach, small intestine, large intestine, liver, gall bladder, spleen, kidneys, adrenal gland, lymph nodes, spinal cord, bone marrow, sternum, femur and tibia with associated skeletal muscles, brown fat, pinna, skin, uterus, oviduct, and ovary, and mammary gland.

AnimalID: M00740519 (Female)**Histopathology Findings:****ovary (MA:0000384)****Histopath Description:**

There ovarian stroma is markedly expanded. Numerous atrophic follicles are embeded within the stroma.

Definitive Diagnosis:

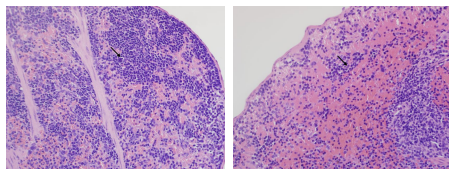
Ovarian stromal hyperplasia

Ovary, stromal
hyperplasia, 10x,
HE**spleen (MA:0000141)****Histopath Description:**

Marked erythropoiesis and mild megakaryopoiesis

Morphological Diagnosis:**Distribution:** multifocal to coalescing; **Severity:** severe; **MPATH Diagnosis:** extramedullary
hemopoiesis MPATH:595**Definitive Diagnosis:**

Marked erythropoiesis; mild megakaryopoiesis



Spleen, marked erythroid hyperplasia, 40x, HE

Spleen, Wt, normal, 40x, HE

lymph node (MA:0000139)

Histopath Description:

The mesenteric lymph node is markedly enlarged (greater than four fold). The medulla is particularly expanded by chords and sheets of plasmotoid cells. There are prominent germinal centers within the medulla

Morphological Diagnosis:

Distribution: Diffuse; **Severity:** moderate; **MPATH Diagnosis:** hyperplasia MPATH:134

Definitive Diagnosis:

Lymphoid hyperplasia

Histopathology Comments:

The changes in the mesenteric lymph node are suggestive of draining of a regional inflammatory process. However, such a process was not observed in the tissues examined. Early marginal center lymphoma is suspected.

brain (MA:0000168)

Histopath Description:

There is mild dilation of the lateral ventricles

Morphological Diagnosis:

Distribution: bilateral; **Severity:** mild;

Definitive Diagnosis:

Dilation of the brain ventricles

Histopathology Comments:

Mild dilation of the lateral ventricles is a background condition in mice of C57BL/6N background (Brayton et al., 2004).

lung (MA:0000415)

Histopath Description:

There is a focal perivascular aggregates of mononuclear inflammatory cells in the lung.

Morphological Diagnosis:

Duration: Chronic; **Distribution:** focal; **Severity:** mild; **MPATH Diagnosis:** inflammation MPATH:212

Definitive Diagnosis:

Perivascular inflammatory aggregates

Histopathology Comments:

This lesion is suggestive of antigenic stimulation of hematogenous origin. It is a common and insignificant incidental finding.

kidney (MA:0000368)

Histopath Description:

There is a focal perivascular aggregate of macrophages, lymphocytes and rare plasma cells at the corticomedullary junction of one of the kidneys.

Morphological Diagnosis:

Duration: Chronic-active; **Distribution:** Focal; **Severity:** mild; **MPATH Diagnosis:** inflammation MPATH:212

Definitive Diagnosis:

Focal perivascular inflammatory aggregate.

Histopathology Comments:

This is a common incidental and insignificant lesion in mice

liver (MA:0000358)

Histopath Description:

moderate lipidosis

Morphological Diagnosis:

Distribution: multifocal to coalescing; **Severity:** moderate; **MPATH Diagnosis:** steatosis
MPATH:622

Definitive Diagnosis:

hepatic steatosis

Organ/Tissue Analyzed:

Histopathology examination included the following organs and tissues: brain, trigeminal ganglion, eyes, salivary glands, trachea, lungs, heart, thymus, thyroid gland, parathyroid gland, exocrine and endocrine pancreas, oesophagus, stomach, small intestine, large intestine, liver, gall bladder, spleen, kidneys, adrenal gland, lymph nodes, spinal cord, bone marrow, sternum, femur and tibia with associated skeletal muscles, brown fat, pinna, skin, uterus, oviduct, and ovary, and mammary gland.

Report Summary and Recommendation:

Main findings in this line are splenic erythroid hyperplasia in three mice, testicular degeneration and atrophy in both male mice, and ovarian stromal hyperplasia in both female mice. The testicular lesion is marked although infertility was not documented in this line.

The splenic erythroid and megakaryocyte hyperplasia suggests enhanced production of erythrocytes and platelets, hence may, respectively, explain the increased red blood cell distribution width increased mean platelet volume observed by hematology. The erythroid hyperplasia was marked in both females. It is important to consider a potential role of the ovarian proliferative lesion in this regard. For instance progesterone is known to enhance hemoglobin synthesis where as androgen enhances erythropoiesis. Hence the hematology phenotypes may be explained by the ovarian proliferative changes. Similarly, cutaneous/hair dysmorphology documented in this line (at least in females) may also be secondary to ovarian stromal lesion (Note that we did not find correlative morphological change to the skin/hair dysmorphology documented by in-life phenotyping). Pruritic dermatitis resulting from hypersensitivity to endogenous sex hormones is recognized in women (autoimmune progesterone dermatitis) (Lee et al., 2011) and rarely in dogs with stromal proliferative lesions (Scott et al., 1999). There are no lesions predictive of partial lethality and fetal edema.

Summary: Testicular degeneration and atrophy (2/2 males); Ovarian stromal hyperplasia (2/2 females); Splenic erythroid hyperplasia (3/4).

References:

Hoenerhoff MJ et al. (2006). Eosinophilic crystalline pneumonia as a major cause of death in 129S4/SvJae mice. *Vet Pathol.* 5:682-8. Lee MK (2011). A Case of Autoimmune Progesterone Dermatitis Misdiagnosed as Allergic Contact Dermatitis. *Allergy Asthma Immunol Res.* 3(2): 141-144. Scott, D. W., and Miller, W. H. Probable hormonal hypersensitivity in two male dogs. *Canine Pract* 17: 14-17, 20, 1999.