

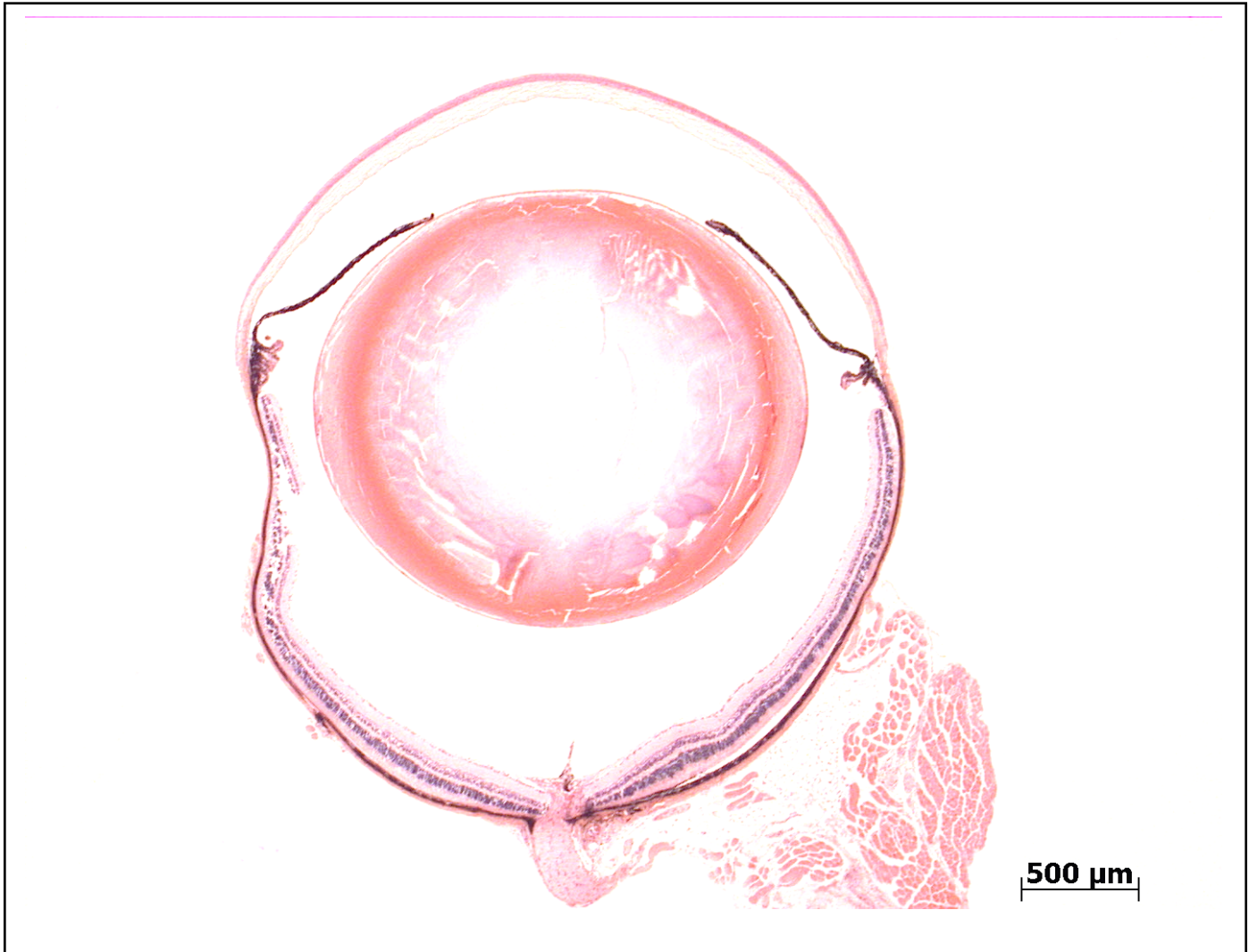
Gene: **Kifap3**

Genotype + / -

Sanger Colony: MCKW

### EYE Phenotype

**Abnormal Findings:** None.



6/6 Normal corneal epithelium, stroma, and endothelium. The anterior chamber was of normal depth without cells, and the angle appeared open. The iris showed normal pigmentation without rubeosis or pupillary membranes. No cataract was observed. Normal stroma, pigmented and nonpigmented layers were present along with cilia. No abnormal opacities or cells. The retinal ganglion, inner nuclear and photoreceptor layers are normal. Normal pigmentation. Bruch's membrane is intact. No neovascular membranes were noted. The nerve is normal.