



# CMHD Pathology Report



## CMHD Pathology Core

Toronto Centre for  
Phenogenomics  
25 Orde St. 3rd fl.  
Toronto, Ont. M5T 3H7  
Tel.(416) 586-8375  
Fax (416) 586-5993

contact: Dr. Susan  
Newbigging  
email:  
[newbigging@lunenfeld.ca](mailto:newbigging@lunenfeld.ca)

ReportID: Report Date: September 12,  
2013  
Pathologist: Dr. H. Adissu

## Mouse Genetics Project

Wellcome Trust Sanger  
Institute  
Wellcome Trust Genome  
Campus  
Hinxton, Cambridge  
CB10 1SA  
UK

CMHD LabID: N13-565

### Relevant History:

Phenotype:  
decreased lumbar vertebrae number  
increased sacral vertebrae number  
lumbar vertebral transformation  
vertebral transformation  
abnormal vertebral arch morphology  
chromosomal instability

---

### AnimalID: M00896523 (Male)

#### Histopathology Findings:

##### liver (MA:0000358)

###### Histopath Description:

diffuse lipidosis

###### Morphological Diagnosis:

**Distribution:** diffuse; **Severity:** extreme; **MPATH Diagnosis:** steatosis MPATH:622

###### Definitive Diagnosis:

hepatic steatosis

##### brain (MA:0000168)

###### Histopath Description:

There is mild dilation of the lateral ventricles. The medulla is poorly preserved to assess lesions observed in M00896535 and M00896536.

###### Morphological Diagnosis:

**Distribution:** bilateral; **Severity:** mild;

###### Definitive Diagnosis:

Dilation of the brain ventricles

###### Histopathology Comments:

Mild dilation of the lateral ventricles is a background condition in mice of C57BL/6N background (Brayton et al., 2004).

##### eye (MA:0000261)

###### Histopath Description:

Involving one eye, there are clusters of external nuclear structures within the internal plexiform layer.

###### Morphological Diagnosis:

**Distribution:** multifocal; **Severity:** mild;

###### Definitive Diagnosis:

Retinal dysplasia

**Organ/Tissue Analyzed:**

Histopathology examination included the following organs and tissues: brain, trigeminal ganglion, eyes, salivary glands, trachea, lungs, heart, thymus, thyroid gland, parathyroid gland, exocrine and endocrine pancreas, oesophagus, stomach, small intestine, large intestine, liver, gall bladder, spleen, kidneys, adrenal gland, lymph nodes, spinal cord, bone marrow, sternum, femur and tibia with associated skeletal muscles, brown fat, pinna, skin, testis, epididymis, seminal vesicle, and prostate.

---

**AnimalID: M00896524 (Male)****Histopathology Findings:****liver (MA:0000358)****Histopath Description:**

diffuse lipidosis

**Morphological Diagnosis:**

**Distribution:** diffuse; **Severity:** extreme; **MPATH Diagnosis:** steatosis MPATH:622

**Definitive Diagnosis:**

hepatic steatosis

**brain (MA:0000168)****Histopath Description:**

There is mild dilation of the lateral ventricles. The medulla is poorly preserved to assess lesions observed in M00896535 and M00896536.

**Morphological Diagnosis:**

**Distribution:** bilateral; **Severity:** mild;

**Definitive Diagnosis:**

Dilation of the brain ventricles

**Histopathology Comments:**

Mild dilation of the lateral ventricles is a background condition in mice of C57BL/6N background (Brayton et al., 2004).

**thymus (MA:0000142)****Histopath Description:**

There are two 50 um diameter epithelial cysts.

**Morphological Diagnosis:**

**Distribution:** multifocal; **MPATH Diagnosis:** cyst MPATH:62

**Definitive Diagnosis:**

Epithelial cyst

**Histopathology Comments:**

This is a developmental abnormality commonly seen in mice.

**Organ/Tissue Analyzed:**

Histopathology examination included the following organs and tissues: brain, trigeminal ganglion, eyes, salivary glands, trachea, lungs, heart, thymus, thyroid gland, parathyroid gland, exocrine and endocrine pancreas, oesophagus, stomach, small intestine, large intestine, liver, gall bladder, spleen, kidneys, adrenal gland, lymph nodes, spinal cord, bone marrow, sternum, femur and tibia with associated skeletal muscles, brown fat, pinna, skin, testis, epididymis, seminal vesicle, and prostate.

---

**AnimalID: M00896536 (Female)****Histopathology Findings:****brain (MA:0000168)****Histopath Description:**

Within the neuropil of the dorsal medullary region (area postrema, solitary and cuneate nuclei) are numerous eosinophilic, amorphous granular spheroid/globular bodies that are 20-40 um in diameters. Some of the spheroids have a basophilic core. There is no cellular reaction in these areas. The lateral ventricles are mildly dilated.

**Morphological Diagnosis:**

**Distribution:** multifocal;

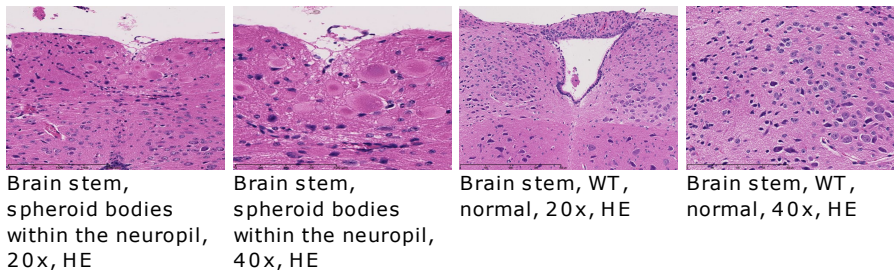
**Definitive Diagnosis:**

Eosinophilic spheroids in dorsal medullar nuclei

**Histopathology Comments:**

See line summary for comments on this lesion. Mild dilation of the lateral ventricles is a background

condition in mice of C57BL/6N background (Brayton et al., 2004).



Brain stem,  
spheroid bodies  
within the neuropil,  
20x, HE

Brain stem,  
spheroid bodies  
within the neuropil,  
40x, HE

Brain stem, WT,  
normal, 20x, HE

Brain stem, WT,  
normal, 40x, HE

#### **liver (MA:0000358)**

##### **Histopath Description:**

moderate lipidosis

##### **Morphological Diagnosis:**

**Distribution:** multifocal to coalescing; **Severity:** moderate; **MPATH Diagnosis:** steatosis  
MPATH:622

##### **Definitive Diagnosis:**

hepatic steatosis

#### **Organ/Tissue Analyzed:**

Histopathology examination included the following organs and tissues: brain, trigeminal ganglion, eyes, salivary glands, trachea, lungs, heart, thymus, thyroid gland, parathyroid gland, exocrine and endocrine pancreas, oesophagus, stomach, small intestine, large intestine, liver, gall bladder, spleen, kidneys, adrenal gland, lymph nodes, spinal cord, bone marrow, sternum, femur and tibia with associated skeletal muscles, brown fat, pinna, skin, uterus, oviduct, and ovary, and mammary gland.

---

#### **AnimalID: M00896535 (Female)**

##### **Histopathology Findings:**

##### **brain (MA:0000168)**

##### **Histopath Description:**

Within the neuropil of the dorsal medullary region (area posterama, solitary and cuneate nuclei) are numerous eosinophilic, amorphous granular spheroid/globular bodies that are 20-40 um in diameters. Some of the spheroids have a basophilic core. There is no cellular reaction in these areas. The lateral ventricles are mildly dilated.

##### **Morphological Diagnosis:**

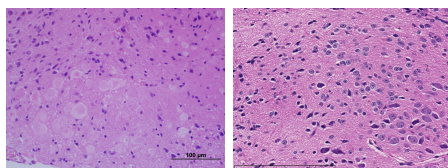
**Distribution:** multifocal;

##### **Definitive Diagnosis:**

Eosinophilic spheroids in dorsal medullar nuclei

##### **Histopathology Comments:**

See line summary for comments on this lesion. Mild dilation of the lateral ventricles is a background condition in mice of C57BL/6N background (Brayton et al., 2004).



Brain stem,  
spheroid bodies  
within the neuropil,  
40x, HE

Brain stem, WT,  
normal, 40x, HE

#### **liver (MA:0000358)**

##### **Histopath Description:**

diffuse lipidosis

##### **Morphological Diagnosis:**

**Distribution:** diffuse; **Severity:** extreme; **MPATH Diagnosis:** steatosis MPATH:622

##### **Definitive Diagnosis:**

hepatic steatosis

#### **thymus (MA:0000142)**

**Histopath Description:**

There are two 50 um diameter epithelial cysts.

**Morphological Diagnosis:**

**Distribution:** multifocal; **MPATH Diagnosis:** cyst MPATH:62

**Definitive Diagnosis:**

Epithelial cyst

**Histopathology Comments:**

This is a developmental abnormality commonly seen in mice.

**thyroid gland (MA:0000129)****Histopath Description:**

The thyroid gland is partially replaced by a lymphoid tissue reminiscent of thymic tissue.

**Morphological Diagnosis:**

**Distribution:** multifocal;

**Definitive Diagnosis:**

Ectopic thymic tissue

**Histopathology Comments:**

This is developmental anomaly incidentally seen in mice

**lymph node (MA:0000139)****Histopath Description:**

The mesenteric lymph node is markedly enlarged (greater than four fold). The medulla is particularly expanded by chords and sheets of plasmotoid cells. There are prominent germinal centers within the medulla

**Morphological Diagnosis:**

**Distribution:** Diffuse; **Severity:** moderate; **MPATH Diagnosis:** hyperplasia MPATH:134

**Definitive Diagnosis:**

Lymphoid hyperplasia

**Histopathology Comments:**

The changes in the mesenteric lymph node are suggestive of draining of a regional inflammatory process. However, such a process was not observed in the tissues examined. Early marginal center lymphoma is suspected.

**Organ/Tissue Analyzed:**

Histopathology examination included the following organs and tissues: brain, trigeminal ganglion, eyes, salivary glands, trachea, lungs, heart, thymus, thyroid gland, parathyroid gland, exocrine and endocrine pancreas, oesophagus, stomach, small intestine, large intestine, liver, gall bladder, spleen, kidneys, adrenal gland, lymph nodes, spinal cord, bone marrow, sternum, femur and tibia with associated skeletal muscles, brown fat, pinna, skin, uterus, oviduct, and ovary, and mammary gland.

**Report Summary and Recommendation:**

Main lesion in this line is the presence of eosinophilic spheroid bodies in the dorsal medullary nuclei in two female mice (M00896535 and M00896536). The brainstem from the other two male mice (both males) is fragmented and poorly preserved.

The morphology and the specific location of these bodies is very similar to those described in autophagy-related 4b (Agtb4b) mutants (Read et al., 2011). In addition, mice deficient for Atg5 (autophagy-related 5) specifically in neural cells develop progressive deficits in motor function that are accompanied by the accumulation of cytoplasmic inclusion bodies in neurons (Hara et al., 2006). These types of bodies are occasionally seen in old mice so their appearance in young mice is often associated with premature senility or autophagy defects. We suspect they represent the latter stages of axonal spheroids and dystrophic axons and neurites, basically an accumulation of incompletely digested endosomal/lysosomal contents and thus the connection to autophagy defects. Based on these findings, we speculate that the Esco1 gene may have a role in autophagy. We did not see similar lesions elsewhere in other tissues. Hence its role (if any) in the phenotypes observed in this line are uncertain.

It is challenging to corroborate the skeletal dysmorphologies by histopathology.

Line summary: Eosinophilic spheroids in dorsal medullary nuclei (2/4).