



CMHD Pathology Report



CMHD Pathology Core

Toronto Centre for
Phenogenomics
25 Orde St. 3rd fl.
Toronto, Ont. M5T 3H7
Tel.(416) 586-8375
Fax (416) 586-5993

contact: Dr. Susan
Newbigging
email:
newbigging@lunenfeld.ca

ReportID: Report Date: January 08, 2014
Pathologist: Dr. H. Adissu

Mouse Genetics Project

Wellcome Trust Sanger
Institute
Wellcome Trust Genome
Campus
Hinxton, Cambridge
CB10 1SA
UK

CMHD LabID: N13-708

Relevant History:

Phenotypes:

increased body weight
decreased bone mineral density
increased percent body fat
increased total body fat amount
increased circulating sodium level
increased B cell number
abnormal fertility/fecundity

AnimalID: M01036859 (Male)

Histopathology Findings:

testis (MA:0000411)

Histopath Description:

There are multifocal vacuolation of the seminiferous tubules; these tubules are devoid of spermatogenesis

Morphological Diagnosis:

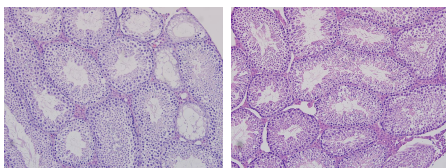
Distribution: focally extensive; **Severity:** mild; **MPATH Diagnosis:** degenerative change MPATH:14; **MPATH Process Term:** degenerative change MPATH:14

Definitive Diagnosis:

Testicular degeneration

Histopathology Comments:

The significance of this locally extensive degenerative change (in presence of robust spermatogenesis in the rest of the testis and abundant spermatocyte storage in the epididymis) is uncertain.



Testis, seminiferous vacuolation, 20x, HE Testis, normal, 20x, HE

Organ/Tissue Analyzed:

Histopathology examination included the following organs and tissues: brain, trigeminal ganglion, eyes, salivary glands, trachea, lungs, heart, thymus, thyroid gland, parathyroid gland, exocrine and endocrine pancreas, oesophagus, stomach, small intestine, large intestine, liver, gall bladder, spleen, kidneys, adrenal gland, lymph nodes, spinal cord, bone marrow, sternum, femur and tibia with associated skeletal muscles, brown fat, pinna, skin, testis, epididymis, seminal vesicle, and prostate.

AnimalID: M01036858 (Male)

Histopathology Findings:**testis (MA:0000411)****Histopath Description:**

There are multifocal vacuolation of the seminiferous tubules; these tubules are devoid of spermatogenesis

Morphological Diagnosis:

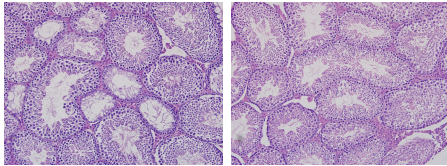
Distribution: focally extensive; **Severity:** mild; **MPATH Diagnosis:** degenerative change MPATH:14; **MPATH Process Term:** degenerative change MPATH:14

Definitive Diagnosis:

Testicular degeneration

Histopathology Comments:

The significance of this locally extensive degenerative change (in presence of robust spermatogenesis in the rest of the testis and abundant spermatocyte storage in the epididymis) is uncertain.



Testis, seminiferous vacuolation, 20x, HE Testis, normal, 20x, HE

sternum (MA:0001331)**Histopath Description:**

There is a partial sternal fracture between the 4th and 5th sternal bodies. The chondroid tissue along the fracture is markedly degenerate. There is a nodular cartilagenous proliferation at the perichondrial margins at the outer aspect of the body wall (reactive reparative chondroid hyperplasia)

Morphological Diagnosis:

Duration: chronic; **Distribution:** focally extensive; **MPATH Process Term:** degenerative change MPATH:14

Definitive Diagnosis:

Sternal osteoarthritis with fracture and reactive and reparative chondroid hyperplasia ('calus')

eye (MA:0000261)**Histopath Description:**

Involving one eye, there are clusters of external nuclear structures within the internal plexiform layer.

Morphological Diagnosis:

Distribution: multifocal; **Severity:** mild; **MPATH Process Term:** developmental dysplasia MPATH:64

Definitive Diagnosis:

Retinal dysplasia

Organ/Tissue Analyzed:

Histopathology examination included the following organs and tissues: brain, trigeminal ganglion, eyes, salivary glands, trachea, lungs, heart, thymus, thyroid gland, parathyroid gland, exocrine and endocrine pancreas, oesophagus, stomach, small intestine, large intestine, liver, gall bladder, spleen, kidneys, adrenal gland, lymph nodes, spinal cord, bone marrow, sternum, femur and tibia with associated skeletal muscles, brown fat, pinna, skin, testis, epididymis, seminal vesicle, and prostate.

AnimalID: M01007888 (Female)**Histopathology Findings:****ovary (MA:0000384)****Histopath Description:**

The ovary is small. The tissue contains rare poorly organized moderately cellular structure composed of spindle-shaped stromal cells and numerous foamy cells that are organized as singly and in cluster and that are irregularly surrounded by flattened to low cuboidal cells. There are no discernible or well defined follicles or luteal tissue.

Morphological Diagnosis:

Distribution: Diffuse; **Severity:** severe; **MPATH Diagnosis:** hypoplasia MPATH:133; **MPATH**

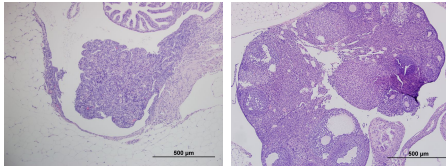
Process Term: hypoplasia MPATH:133

Definitive Diagnosis:

Ovarian hypoplasia

Histopathology Comments:

The absence of follicles and luteal structures within the ovary indicate hypoplasia. Note that there is a concomitant hypoplasia of the uterus.



Ovary, hypoplasia, 10x, HE

Ovary, WT, normal, 10x, HE

uterus (MA:0000389)

Histopath Description:

The uterus is small and the endometrium is composed of a cuboidal to low columnar epithelium supported by a thin layer of submucosa; the muscular layer is underdeveloped.

Morphological Diagnosis:

Distribution: Diffuse; **Severity:** severe; **MPATH Diagnosis:** hypoplasia MPATH:133; **MPATH Process Term:** hypoplasia MPATH:133

Definitive Diagnosis:

Uterine hypoplasia

lymph node (MA:0000139)

Histopath Description:

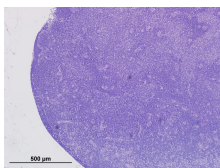
The architecture of the mesenteric lymph node is altered by the presence of large numbers of monomorphic lymphocytes filling and distending all the sinuses and elevating the capsule. The neoplastic cells have generally a scant amount of eosinophilic cytoplasm, medium sized round central nucleus with granular chromatin and single variably distinct amphophilic nucleoli. Mitotic figures are less than 1/HPF.

Morphological Diagnosis:

Distribution: Diffuse; **MPATH Diagnosis:** lymphoid neoplasms MPATH:513; **MPATH Process Term:** neoplasia MPATH:218

Definitive Diagnosis:

Lymphoma



Lymph node, lymphoma, 10x, HE

Organ/Tissue Analyzed:

Histopathology examination included the following organs and tissues: brain, trigeminal ganglion, eyes, salivary glands, trachea, lungs, heart, thymus, thyroid gland, parathyroid gland, exocrine and endocrine pancreas, oesophagus, stomach, small intestine, large intestine, liver, gall bladder, spleen, kidneys, adrenal gland, lymph nodes, spinal cord, bone marrow, sternum, femur and tibia with associated skeletal muscles, brown fat, pinna, skin, uterus, oviduct, and ovary, and mammary gland.

AnimalID: M01007886 (Female)

Histopathology Findings:

ovary (MA:0000384)

Histopath Description:

The ovary is small. The tissue contains rare poorly organized moderately cellular structure composed of spindle-shaped stromal cells and numerous foamy cells that are organized as singly and in cluster and that are irregularly surrounded by flattened to low cuboidal cells. There are no discernible or well defined follicles or luteal tissue.

Morphological Diagnosis:

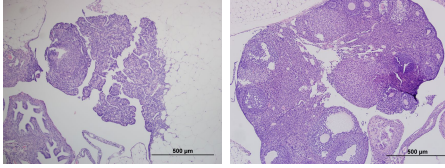
Distribution: Diffuse; **Severity:** severe; **MPATH Diagnosis:** hypoplasia MPATH:133; **MPATH Process Term:** hypoplasia MPATH:133

Definitive Diagnosis:

Ovarian hypoplasia

Histopathology Comments:

The absence of follicles and luteal structures within the ovary indicate hypoplasia. Note that there is a concomitant hypoplasia of the uterus; see below.

O vary, hypoplasia,
10x, HEO vary, WT, normal,
10x, HE**uterus (MA:0000389)****Histopath Description:**

The uterus is small and the endometrium is composed of a cuboidal to low columnar epithelium supported by a thin layer of submucosa; the muscular layer is underdeveloped.

Morphological Diagnosis:

Distribution: Diffuse; **Severity:** severe; **MPATH Diagnosis:** hypoplasia MPATH:133; **MPATH Process Term:** hypoplasia MPATH:133

Definitive Diagnosis:

Uterine hypoplasia

liver (MA:0000358)**Histopath Description:**

There is a focal aggregates of inflammatory cells centered on necrotic and regenerative hepatocytes

Morphological Diagnosis:

Distribution: Multifocal; **Severity:** mild; **MPATH Diagnosis:** inflammation MPATH:212; **MPATH Process Term:** inflammation MPATH:212

Definitive Diagnosis:

Inflammatory cell aggregates

Histopathology Comments:

This is a common finding in lab mice and is attributed to inflammation from bacterial showering from the portal circulation.

Organ/Tissue Analyzed:

Histopathology examination included the following organs and tissues: brain, trigeminal ganglion, eyes, salivary glands, trachea, lungs, heart, thymus, thyroid gland, parathyroid gland, exocrine and endocrine pancreas, oesophagus, stomach, small intestine, large intestine, liver, gall bladder, spleen, kidneys, adrenal gland, lymph nodes, spinal cord, bone marrow, sternum, femur and tibia with associated skeletal muscles, brown fat, pinna, skin, uterus, oviduct, and ovary, and mammary gland.

Report Summary and Recommendation:

Ovarian and uterine hypoplasia is observed in both females consistent with reduced infertility/fecundity in this line. Mild testicular lesions were also observed in both males. However, the lesion was not considered severe enough to compromise fertility (in light of abundant sperm store in the epididymis). Lymphoma of the mesenteric lymph node was observed in one mouse; the lesion may explain increased B lymphocyte number in this mouse. No such lesion was found in the rest of the mice to explain B lymphocytosis. We did not find morphological correlate to increased body weight, increased percent body fat, decreased bone mineral density, and increased circulating sodium level.

Summary:

Males: Testicular degeneration, multifocal (2/2)

Females: Ovarian hypoplasia (2/2); uterine hypoplasia (2/2)