



CMHD Pathology Report



CMHD Pathology Core

Toronto Centre for
Phenogenomics
25 Orde St. 3rd fl.
Toronto, Ont. M5T 3H7
Tel.(416) 586-8375
Fax (416) 586-5993

contact: Dr. Susan
Newbigging
email:
newbigging@lunenfeld.ca

ReportID: Report Date: October 15, 2013
Pathologist: Dr. H. Adissu

Mouse Genetics Project

Wellcome Trust Sanger
Institute
Wellcome Trust Genome
Campus
Hinxton, Cambridge
CB10 1SA
UK

CMHD LabID: N13-701

Relevant History:

Phenotypes

chromosomal instability
preweaning lethality
embryonic lethality

AnimalID: M00867482 (Male)

Histopathology Findings:

lymph node (MA:0000139)

Histopath Description:

Overall, the mesenteric lymph node is distinctly basophilic. Its architecture is disrupted by diffuse sheets of monotypic round cells that distended the subcapsular, medullary and occasional transverse sinuses. The cells have scant or no visible cytoplasm, round nuclei with stippled chromatin and a central distinct nucleolus (interpreted as lymphocytes). Rare apoptotic bodies and mitotic figures are present within occasional germinal centers.

Morphological Diagnosis:

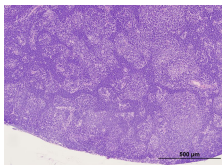
MPATH Diagnosis: lymphoid neoplasms MPATH:513; **MPATH Process Term:** neoplasia MPATH:218

Definitive Diagnosis:

Lymphoma

Histopathology Comments:

The presence of diffuse sheets of monomorphic lymphocytes within the sinuses is suggestive of lymphoma. Note all mice in this line have mesenteric lymphoma.



Lymph node,
lymphoma, 10x, HE

kidney (MA:0000368)

Histopath Description:

Nearly half of the renal parenchyma is replaced by a large cyst; the renal parenchyma surrounding the cyst is mildly compressed. There is prominent tubular hyperplasia and interstitial inflammation.

Morphological Diagnosis:

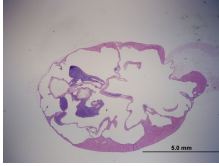
Duration: Chronic; **Distribution:** Unilateral; **Severity:** severe; **MPATH Diagnosis:** hydronephrosis MPATH:635;

Definitive Diagnosis:

Hydronephrosis with mild parenchymal atrophy

Histopathology Comments:

Hydronephrosis is usually caused by an ascending obstructive urinary lesion; this is not evident in the examined sections.



Kidney,
hydronephrosis,
1.25x, HE

retina (MA:0000276)

Histopath Description:

There are multifocal indulation of the retinal layers

Morphological Diagnosis:

Distribution: multifocal; **Severity:** mild;

Definitive Diagnosis:

Retinal folding (dysplasia)

liver (MA:0000358)

Histopath Description:

diffuse lipidosis

Morphological Diagnosis:

Distribution: diffuse; **Severity:** extreme; **MPATH Diagnosis:** steatosis MPATH:622; **MPATH Process Term:** lipid deposition MPATH:42

Definitive Diagnosis:

hepatic steatosis

Organ/Tissue Analyzed:

Histopathology examination included the following organs and tissues: brain, trigeminal ganglion, eyes, salivary glands, trachea, lungs, heart, thymus, thyroid gland, parathyroid gland, exocrine and endocrine pancreas, oesophagus, stomach, small intestine, large intestine, liver, gall bladder, spleen, kidneys, adrenal gland, lymph nodes, spinal cord, bone marrow, sternum, femur and tibia with associated skeletal muscles, brown fat, pinna, skin, testis, epididymis, seminal vesicle, and prostate.

AnimalID: M00867483 (Male)

Histopathology Findings:

lymph node (MA:0000139)

Histopath Description:

Overall, the mesenteric lymph node is distinctly basophilic. Its architecture is disrupted by diffuse sheets of monotypic round cells that distended the subcapsular, medullary and occasional transverse sinuses. The cells have scant or no visible cytoplasm, round nuclei with stippled chromatin and a central distinct nucleolus (interpreted as lymphocytes). Rare apoptotic bodies and mitotic figures are present within occasional germinal centers.

Morphological Diagnosis:

MPATH Diagnosis: lymphoid neoplasms MPATH:513; **MPATH Process Term:** neoplasia MPATH:218

Definitive Diagnosis:

Lymphoma

Histopathology Comments:

The presence of diffuse sheets of monomorphic lymphocytes within the sinuses is suggestive of lymphoma. Note all mice in this line have mesenteric lymphoma.

brain (MA:0000168)

Histopath Description:

There is mild dilation of the lateral ventricles

Morphological Diagnosis:

Distribution: bilateral; **Severity:** mild; **MPATH Process Term:** degenerative change MPATH:14

Definitive Diagnosis:

Dilation of the brain ventricles

Histopathology Comments:

Mild dilation of the lateral ventricles is a background condition in mice of C57BL/6N background

(Brayton et al., 2004).

liver (MA:0000358)

Histopath Description:

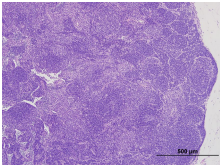
diffuse lipidosis

Morphological Diagnosis:

Distribution: diffuse; **Severity:** extreme; **MPATH Diagnosis:** steatosis MPATH:622; **MPATH Process Term:** lipid deposition MPATH:42

Definitive Diagnosis:

hepatic steatosis



Lymph node,
lymphoma, 10x, HE

Organ/Tissue Analyzed:

Histopathology examination included the following organs and tissues: brain, trigeminal ganglion, eyes, salivary glands, trachea, lungs, heart, thymus, thyroid gland, parathyroid gland, exocrine and endocrine pancreas, oesophagus, stomach, small intestine, large intestine, liver, gall bladder, spleen, kidneys, adrenal gland, lymph nodes, spinal cord, bone marrow, sternum, femur and tibia with associated skeletal muscles, brown fat, pinna, skin, testis, epididymis, seminal vesicle, and prostate.

AnimalID: M00867484 (Female)

Histopathology Findings:

lymph node (MA:0000139)

Histopath Description:

Overall, the mesenteric lymph node is distinctly basophilic. Its architecture is disrupted by diffuse sheets of monotypic round cells that distended the subcapsular, medullary and occasional transverse sinuses. The cells have scant or no visible cytoplasm, round nuclei with stippled chromatin and a central distinct nucleolus (interpreted as lymphocytes). Rare apoptotic bodies and mitotic figures are present within occasional germinal centers.

Morphological Diagnosis:

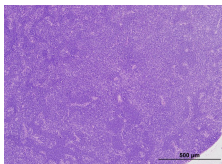
MPATH Diagnosis: lymphoid neoplasms MPATH:513; **MPATH Process Term:** neoplasia MPATH:218

Definitive Diagnosis:

Lymphoma

Histopathology Comments:

The presence of diffuse sheets of monomorphic lymphocytes within the sinuses is suggestive of lymphoma. Note all mice in this line have mesenteric lymphoma.



Lymph node,
lymphoma, 10x, HE

liver (MA:0000358)

Histopath Description:

moderate lipidosis

Morphological Diagnosis:

Distribution: multifocal to coalescing; **Severity:** moderate; **MPATH Diagnosis:** steatosis MPATH:622; **MPATH Process Term:** lipid deposition MPATH:42

Definitive Diagnosis:

hepatic steatosis

retina (MA:0000276)

Histopath Description:

There are multifocal indulation of the retinal layers

Morphological Diagnosis:

Distribution: multifocal; **Severity:** mild;

Definitive Diagnosis:

Retinal folding (dysplasia)

Organ/Tissue Analyzed:

Histopathology examination included the following organs and tissues: brain, trigeminal ganglion, eyes, salivary glands, trachea, lungs, heart, thymus, thyroid gland, parathyroid gland, exocrine and endocrine pancreas, oesophagus, stomach, small intestine, large intestine, liver, gall bladder, spleen, kidneys, adrenal gland, lymph nodes, spinal cord, bone marrow, sternum, femur and tibia with associated skeletal muscles, brown fat, pinna, skin, uterus, oviduct, and ovary, and mammary gland.

AnimalID: M00867485 (Female)**Histopathology Findings:****lymph node (MA:0000139)****Histopath Description:**

Overall, the mesenteric lymph node is distinctly basophilic. Its architecture is disrupted by diffuse sheets of monotypic round cells that distended the subcapsular, medullary and occasional transverse sinuses. The cells have scant or no visible cytoplasm, round nuclei with stippled chromatin and a central distinct nucleolus (interpreted as lymphocytes). Rare apoptotic bodies and mitotic figures are present within occasional germinal centers.

Morphological Diagnosis:

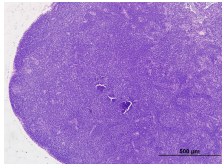
MPATH Diagnosis: lymphoid neoplasms MPATH:513; **MPATH Process Term:** neoplasia MPATH:218

Definitive Diagnosis:

Lymphoma

Histopathology Comments:

The presence of diffuse sheets of monomorphic lymphocytes within the sinuses is suggestive of lymphoma. Note all mice in this line have mesenteric lymphoma.



Lymph node,
lymphoma, 10x, HE

liver (MA:0000358)**Histopath Description:**

moderate lipidosis

Morphological Diagnosis:

Distribution: multifocal to coalescing; **Severity:** moderate; **MPATH Diagnosis:** steatosis MPATH:622; **MPATH Process Term:** lipid deposition MPATH:42

Definitive Diagnosis:

hepatic steatosis

brain (MA:0000168)**Histopath Description:**

There is mild dilation of the lateral ventricles

Morphological Diagnosis:

Distribution: bilateral; **Severity:** mild; **MPATH Process Term:** degenerative change MPATH:14

Definitive Diagnosis:

Dilation of the brain ventricles

Histopathology Comments:

Mild dilation of the lateral ventricles is a background condition in mice of C57BL/6N background (Brayton et al., 2004).

Organ/Tissue Analyzed:

Histopathology examination included the following organs and tissues: brain, trigeminal ganglion, eyes, salivary glands, trachea, lungs, heart, thymus, thyroid gland, parathyroid gland, exocrine and endocrine pancreas, oesophagus, stomach, small intestine, large intestine, liver, gall bladder, spleen, kidneys, adrenal gland, lymph nodes, spinal cord, bone marrow, sternum, femur and tibia with associated skeletal muscles, brown fat, pinna, skin, uterus, oviduct, and ovary, and mammary gland.

Report Summary and Recommendation:

Lymphoma of the mesenteric lymph node is present in all mice consistent with gross finding of enlarged lymph nodes. Note that lymphoma is one of the most common neoplasms in C57BL/6 strain. The presence of lymphoma in all mice in this line suggests that the gene may have a potential tumor modifier effect. Note that chromosomal instability is one of the phenotype abnormalities in this line.

There are no lesions predictive of embryonic and preweaning lethality in homozygotes. Analysis of embryos and preweaning homozygotes is required to determine cause of mortality.

Line summary:

Mesenteric lymph node: Lymphoma (4/4)